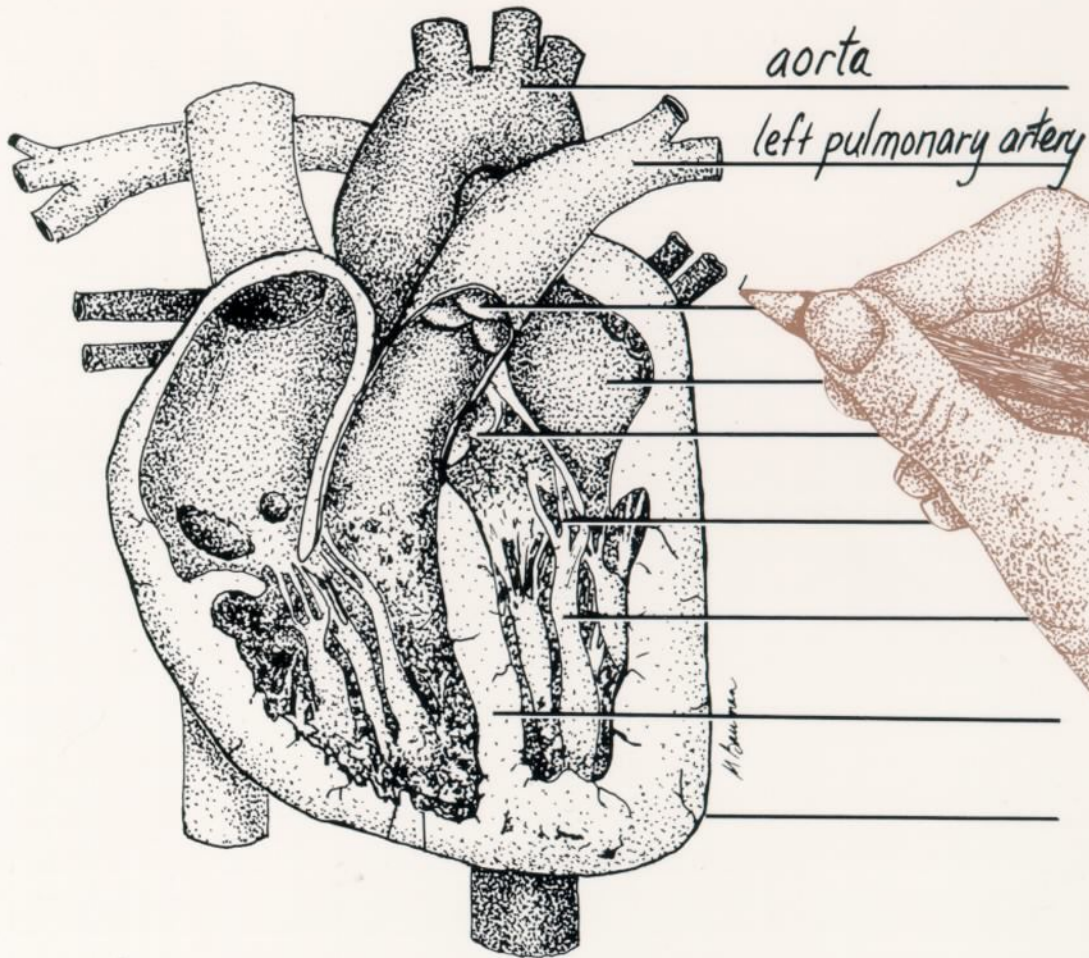


HUMAN ANATOMY AND PHYSIOLOGY LABORATORY TEXTBOOK

ROBERT BAUMAN, JR., PH.D

STEVE DUTTON



HUMAN ANATOMY
AND PHYSIOLOGY,
LABORATORY TEXTBOOK

ROBERT BAUMAN, JR., PH.D.
STEVE DUTTON

ILLUSTRATIONS BY MICHELLE BAUMAN

WP
whittier
publications inc.

Published by Whittier Publications Inc.
Lido Beach N.Y. 11561

Copyright ©1991, 1996 by Robert Bauman Jr. and Steve Dutton.
All rights reserved.

ISBN 1-878045-06-7

No part of this publication can be reproduced,
stored in a retrieval system, or transmitted, in any
form or by any means, electronic, mechanical,
photocopying, recording, or otherwise, without the
prior permission of the publisher.

Printed in the United States of America

10 9 8 7 6 5 4 3

CONTENTS

FUNDAMENTALS

1. Terminology	1
2. Microscopy	12
3. Cell Structure and Function	21
4. Mitosis.....	25
5. Histology	29
Epithelial	29
Connective (other than bone)	32

SYSTEMS OF THE HUMAN BODY

6. The Integument	42
-------------------------	----

THE SKELETAL SYSTEM

7. Osseous Tissue	47
8. The Skeletal Plan	50
9. The Axial Skeleton: The Skull	57
10. The Axial Skeleton: The Vertebral Column	72
11. The Appendicular Skeleton	80
12. Articulations	93

THE SKELETAL MUSCLES

13. Muscle Tissue and the Neuromuscular Junction	98
14. Body Movements	107
15. Cat Dissection: Skin Removal	111
16. Muscles of the Trunk and Shoulder	116
17. Head and Neck Muscles	123
18. Arm Muscles	128
19. Leg Muscles	133

THE DIGESTIVE SYSTEM

20. The Digestive System	140
--------------------------------	-----

THE NERVOUS SYSTEM

21. Nervous Tissue	152
22. Spinal Cord and Reflexes	157
23. Brain	165
24. The Eye and Visual tests	176
25. The Ear	187

THE CIRCULATORY SYSTEMS

26. Hematology:	194
Total White Blood Cell Count	194
Total Red Blood Cell Count	197
Blood Typing	198
Hemoglobin Determination	201
Hematocrit	203
Coagulation Time	204
27. The Heart	207
28. Arteries and Veins	216
29. Fetal Circulation	226
30. The Lymphatic System	230

THE RESPIRATORY SYSTEM

31. Respiratory Organs	234
32. Spirometry	241

THE URINARY SYSTEM

33. Urinary Organs	245
34. Urinalysis	253

THE REPRODUCTIVE SYSTEM

35. Meiosis	260
36. The Reproductive System	
Male	264
Female	267

GENETICS

37. Genetics	274
--------------------	-----

Forward

This book has been written with learning in mind. There are several ways to use this book.

First the student should read it. Second, he or she should fill in the label lines of the figures in pencil. This can be done with reference to the lab text as well as to the course textbook. At this time the student should also make use of the models and bones available in the laboratory. Finally, the figures have been printed in black and white so that the enterprising student can color the drawings with colored pencils.

With diligence and hard work the fascinating world of anatomy and physiology can be successfully mastered.

Dedication

We dedicate this book to our students at
Amarillo College, both present and past.
To our wives, for their support and patience
while we have wrestled with this endeavor,
thank you.

TERMINOLOGY

Human **anatomy** is the study of the **structure** of the human body and of its various parts. **Physiology** is the study of the **function** of those parts. A complete understanding of anatomy requires knowledge of physiology, and a comprehension of physiology, requires knowledge of anatomy.

Scientific and medical terminology has been developed to accurately explain the location and relationship of the parts of the body. A thorough understanding of these terms, is necessary for a clear comprehension of the location and function of body parts. If you do not know the exact meaning of these terms, you will be unable to successfully master human anatomy and physiology.

RELATIVE POSITIONS

Descriptions of the location of one part of the body in relation to another part of the body utilize terms of relative position. All of these terms assume that the body is in a standard position called the **anatomical position**. This posture of the body assumes that the body is facing the viewer, arms and legs down, and palms forward (Figure 1.1). Regardless of the actual position of the body and its parts, anatomical terminology is used as if the body were in anatomical position. Note: in anatomical position the body is facing you; therefore, the right side of the body will be on your left.

Anterior and Posterior. In humans the anterior structures are those at the front of the body such as the face and abdomen. The posterior features are those at the rear of the body, for example, the back and buttocks. The terms ventral and dorsal are sometimes used in place of anterior and posterior. Ventral is normally used of four-legged animals to refer to structures underneath, i.e. the belly. The word dorsal refers to the back.

Superior and Inferior. These two terms explain the vertical relationship between body parts. The Latin

word *super* means above. Therefore, a superior part is above an inferior part. For example the head is superior to the neck while the neck is inferior to the head. The hair on top of the head is superior to all other structures. In animals, the terms cephalad (toward the head) and caudal (toward the tail) are used instead of superior and inferior.

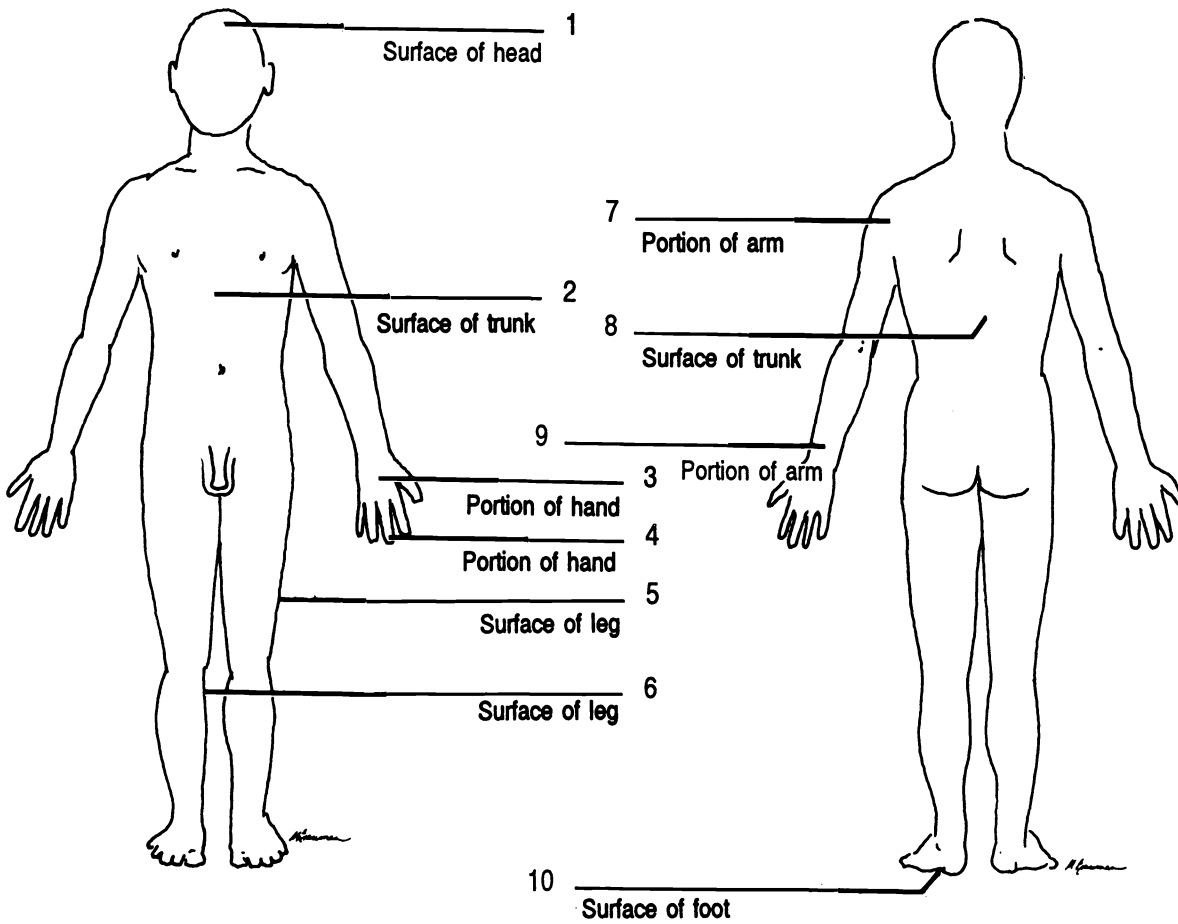


Figure 1.1 Anatomical Position

Figure 1.2 Posterior Surface

Anterior Distal (X2) Inferior Lateral Medial Posterior Proximal (X2) Superior

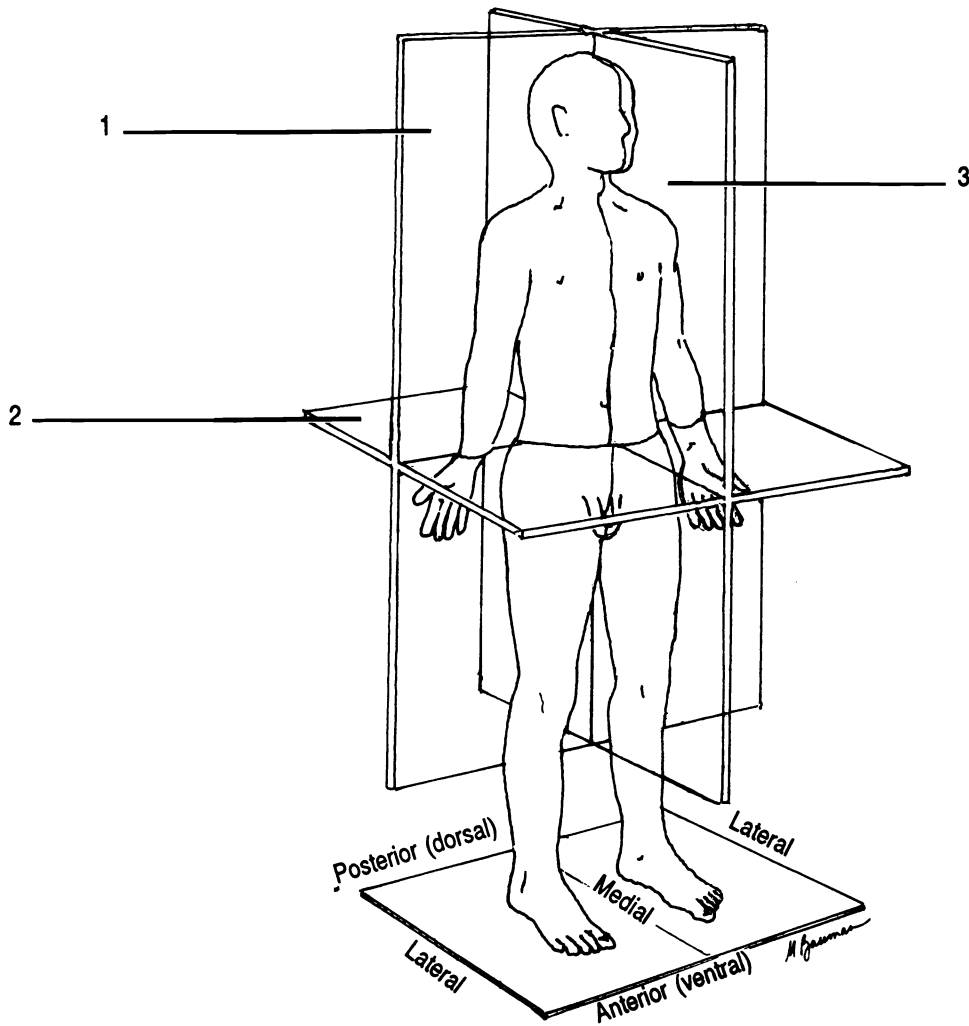


Figure 1.3 Sections of the Body

Frontal section Midsagittal section Transverse section

Medial and Lateral. These words describe the location of structures in relationship to an imaginary plane separating the body into right and left halves. Medial structures are closer to the line than are lateral structures. For example the nose is medial to the eyes; whereas, the eyes are lateral to the nose.

Superficial and Deep. Superficial structures lie closer to the surface of the body than deep structures.

Proximal and Distal. The last words describing relative positions are used to describe the location of parts of a limb relative to the point of attachment of the limb to the trunk.

Those parts which are closer to the point of attachment are said to be proximal. The more distant parts are distal. The fingers are distal to the palm; the palm is proximal to the fingers.

BODY SECTIONS

To view internal organs and understand their anatomy it is often helpful to cut or section them. There are three primary ways that an organ or the body can be cut to view its internal structure (Figure 1.3). A **sagittal** section is a cut which divides the body or organ into right and left portions. A special kind of sagittal section is a cut which passes through the imaginary midline of the body or organ. This cut is termed a **midsagittal** section. A **frontal** section is one which divides the structure into anterior and posterior parts (as if one had cut the “front all” off). Finally a **transverse** or cross section is a cut perpendicular to the midline dividing the body or organ into superior and inferior portions.

ABDOMINAL DIVISIONS

The location of organs which lie in the abdomen can be described using either the names of four quadrants (Figure 1.4A) or nine abdominal regions (Figure 1.4B). The four quadrants are named the upper right, lower right, upper left, and lower left quadrants. Remember that the right side of a body in anatomical position is on your left!

The nine abdominal surface areas are named as follows. The **umbilical** is located in the central region where the navel lies. Superior to this is the **epigastric** (*epi* = Gr. upon; *gaster* = Gr. belly) and below this is the **hypogastric** (*hypo* = Gr. under). The upper lateral regions are the right and left **hypochondriacs** (*hypo* = Gr. under; *chondros* Gr. = cartilage [of ribs]). (The Greeks thought that disease originated in this region, thus a person with many diseases was a “hypochondriac”.) Inferior to the hypochondriac regions, lateral to the umbilicus region, are the two **lumbar** regions. Inferior to the lumbar regions are the right and left **iliac** regions. Remember that in anatomical position the right of a body facing you is on your left.

BODY CAVITIES

All of the internal organs (viscera) are located within body cavities (Figure 1.5). The two major cavities are the **dorsal cavity** and the **ventral cavity**. The dorsal cavity is divided

into the **cranial cavity** containing the brain and the **spinal cavity** containing the spinal cord.

The ventral cavity is divided into the **thoracic cavity**, superior to the diaphragm, and the **abdominopelvic cavity**, inferior to the diaphragm. The thoracic cavity is further divided into the **pleural cavities**, which contain the lungs, and the **mediastinum**. The mediastinum is a mass of tissue between the lungs containing many organs including the heart, thymus gland, trachea, esophagus, and many blood vessels. The abdominopelvic cavity consists of two parts, the **pelvic cavity** and the **abdominal cavity**. The plane of division between these two is imaginary.

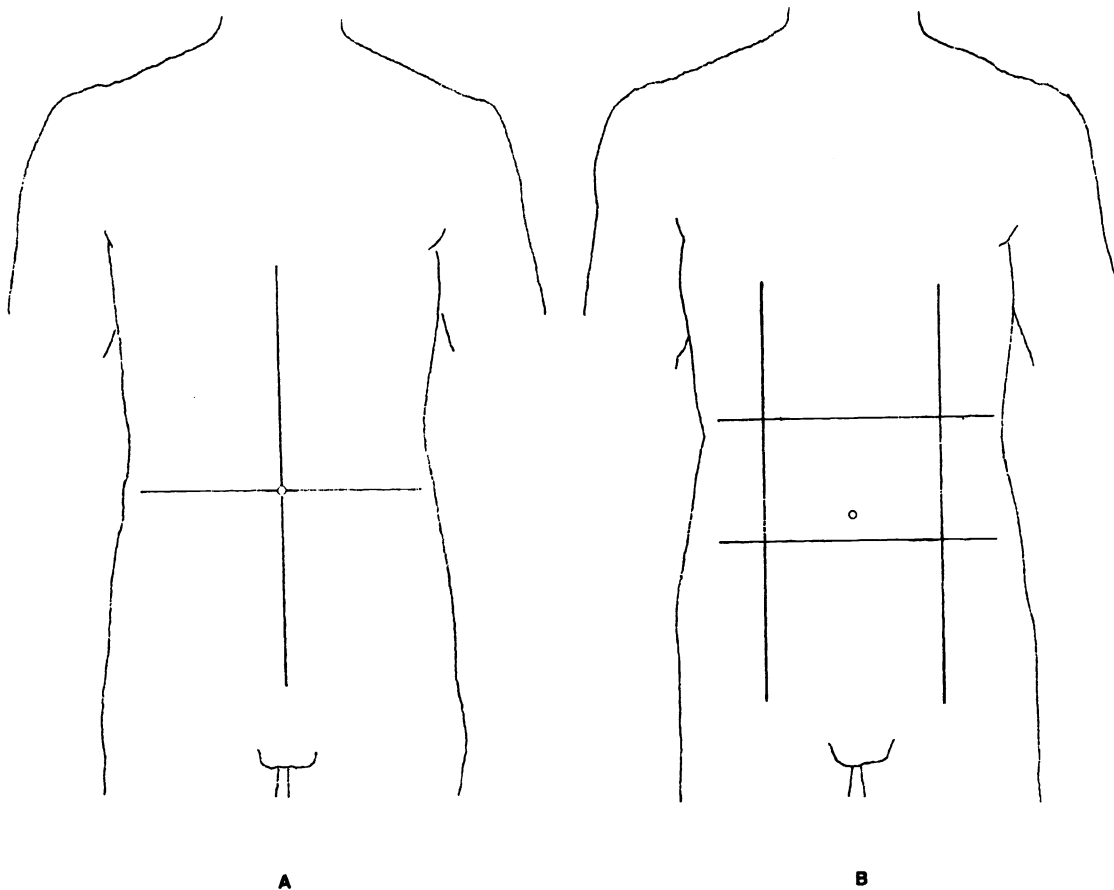


Figure 1.4 Abdominal Divisions

A: Left lower Right lower Left upper Right upper

B: Epigastric Hypogastric Left hypochondriac Left iliac Left lumbar Right hypochondriac Right iliac Right lumbar Umbilical

BODY CAVITY MEMBRANES

The anterior cavities of the body are lined with membranes called serous membranes (Figs. 1.6, 1.7). These secrete serous fluid. The membranes and the fluid provide a smooth, lubricated surface for the viscera. There are four serous membranes: the pericardium around the heart, the peritoneum around most of the abdomino-pelvic organs, and the two pleurae (sing. - pleura), one around each lung. Each serous membrane is folded twice around the internal organs so that there appears to be two membranes instead of one. Figure 1.8 illustrates how this is possible. A potential space exists between the two layers. The potential space around the heart is named the **pericardial cavity**. The potential space around a lung is a **pleural cavity** and the potential space around the abdominal viscera is the **peritoneal cavity**. The layer of each serous membrane closest to the viscera is the **visceral layer**, and the layer of the membrane closest to the wall of the body is the **parietal layer**.

Exercise 1.1

Label the figures with the correct words from the list below each drawing.

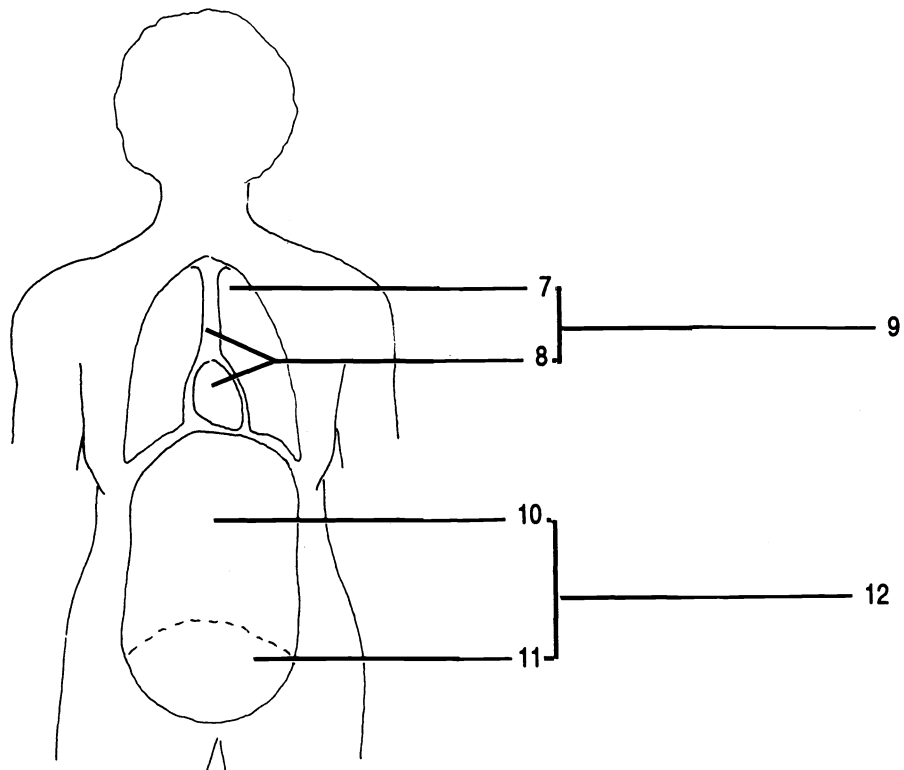
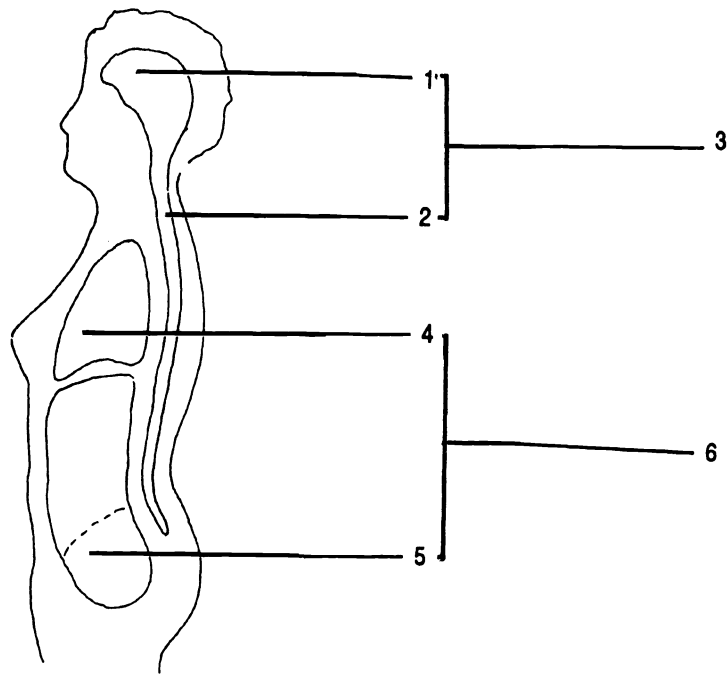


Figure 1.5 Body Cavities

Abdominal cavity Abdominopelvic cavity (X2) Cranial cavity Dorsal cavity Mediastinum Pleural cavity
 Spinal cavity Thoracic cavity (X2) Ventral cavity

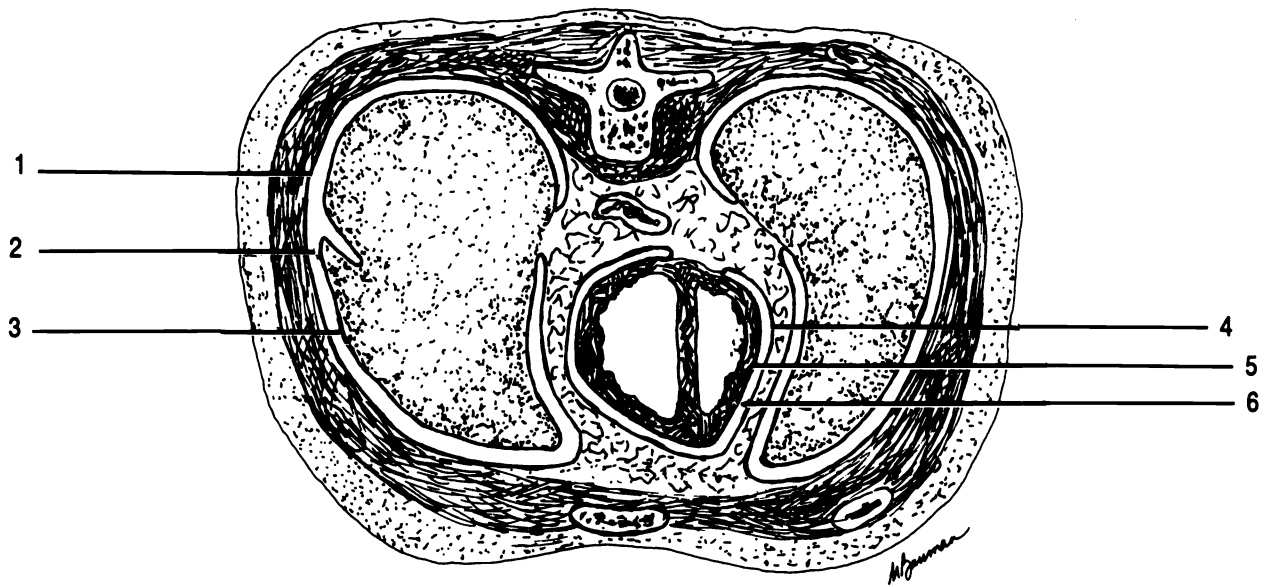


Figure 1.6 Transverse Section through the Thoracic Cavity

Parietal pericardium Parietal pleura Pericardial cavity Pleural cavity Visceral pericardium Visceral pleura

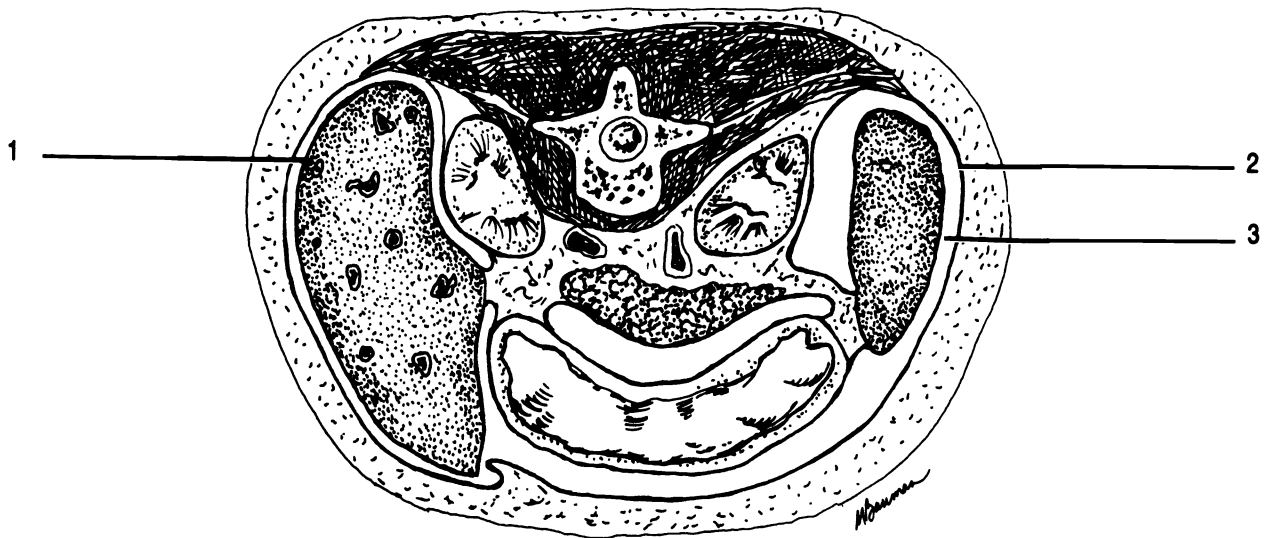


Figure 1.7 Transverse Section through the Abdominal Cavity

Parietal peritoneum Peritoneal cavity Visceral peritoneum

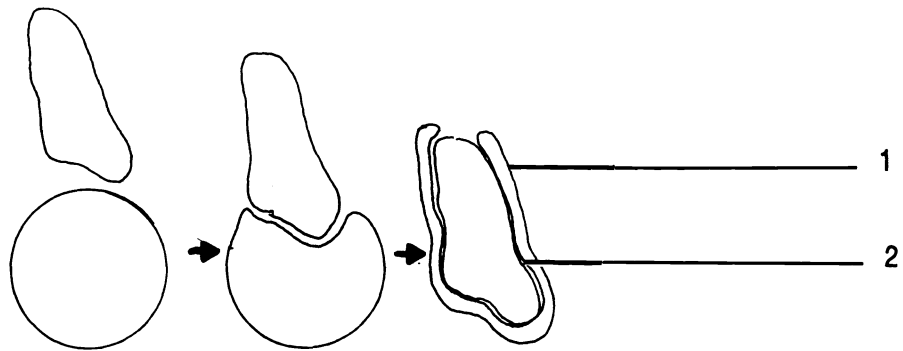


Figure 1.8 Serous Membrane. Note how a "circular" membrane can surround an organ in such a way as to form two layers from the one membrane.

Parietal layer Visceral layer

CHAPTER 1 REVIEW

From the list below fill in the word which best completes each sentence. Each word may be used more than once or not at all.

1. _____ The nose is (1) to the eyes.
2. _____ The nose is (2) to the forehead.
3. _____ The nose is (3) to the mouth.
4. _____ The nose is (4) to the ears.
5. _____ The thoracic cavity is (5) to the abdominopelvic cavity.
6. _____ The feet are (6) to the legs.
7. _____ The thumb is (7) to the fingers.
8. _____ The umbilicus (navel) is on the (8) surface of the body.
9. _____ The toes are (9) to the heel.
10. _____ The wrist is (10) to the elbow.
11. _____ The palms are on the (11) surface of the body, while the knuckles are on the posterior surface.
12. _____ The tongue is (12) to the cheeks.
13. _____ The lungs are (13) to the diaphragm.
14. _____ The knee is (14) to the ankle.
15. _____ The skin is (15) to the muscles.

anterior
medial

deep
posterior

distal
proximal

inferior
superficial

lateral
superior

16. _____ Which section divides the body into upper and lower portions?
17. _____ A student cuts a brain into two equal, right and left, portions. What kind of section has she made?
18. _____ If you cut the brain into right and left sections which were not equal then the section would be (18).

19. _____ Which section would divide an organ into anterior and posterior portions?
20. _____ In which of the nine abdominopelvic regions does the gallbladder lie? Look in your textbook for a picture of the gallbladder.
21. _____ In which of the nine regions would you find the urinary bladder?
22. _____ In which of the nine regions would you usually find the proximal end of the appendix?
23. _____ The stomach lies in the (23) quadrant.
24. _____ The liver is in the (24) quadrant.
25. _____ The distal end of the descending colon is in the (25) quadrant.

MICROSCOPY

A microscope allows you to observe objects which are too small to be seen with the naked eye. To maximize your laboratory experience in the study of cells and tissues you must master the use of a microscope.

Here are a few rules which will protect the microscopes from damage:

1. ALWAYS USE TWO HANDS TO CARRY THE MICROSCOPE. ONE HAND SHOULD BE ON THE BASE AND ONE HAND ON THE ARM (SEE "PARTS OF THE MICROSCOPE" BELOW).
2. NEVER TOUCH THE LENSES OF THE MICROSCOPE WITH ANYTHING EXCEPT THE LENS PAPER PROVIDED BY YOUR TEACHER.
3. TURN OFF THE LIGHT AND RETURN THE LENSES TO THE LOWEST POWER POSITION BEFORE RETURNING THE MICROSCOPE TO THE STORAGE AREA.

Observing these rules will protect the microscopes from damage and insure that they will be available for your use throughout the semester.

PARTS OF THE MICROSCOPE

Exercise 2.1

Write the name of each part of the microscope in the blanks in Figure 2.1 or Figure 2.2. (Label only the drawing which most closely matches your microscope).

Your microscope is a **compound** microscope; that is, it has two sets of lenses which focus the light into your eye and magnify the object being observed. The lens closest to your eye is the eyepiece which is scientifically known as the **ocular**. Some microscopes have two oculars and

are thus binocular. Your ocular magnifies objects ten times (10X).

The lens closest to the object being observed is an **objective**. Your microscope has either three or four objectives mounted on a **revolving nosepiece**. Each objective has a magnifying power which is printed on the lens. In Anatomy and Physiology you will use the 10X or **low power objective** and the 43X (or 40X) **high power objective**. The other lens(es) will not be used. Never touch the glass part of a lens with anything except lens paper. Always return the lowest power objective into the down position before storing the microscope.

The total magnification of a microscope is calculated by multiplying the magnification of the ocular (10X) by the magnifying power of the objective. Thus the total magnification using the low power objective is 100 times (100X). This is calculated by multiplying 10 (ocular) times 10 (low power objective).

Your microscope has a special feature called **parfocal**. This means that once you have located and focused the object on low power you will have to make only minimal adjustments of the fine focusing knob to focus the object at high power.

The sturdy bottom of the microscope is the **base**. Built into the base is a **light source**. Always turn the light off before you put your microscope away. The **arm** extends upwards from the base and holds two concentric adjustment knobs, the stage, and the lenses. Carry a microscope with one hand on the base and the other hand on the arm.

The larger adjustment knob is the **coarse adjustment knob** and is used only with the short, low power objective. The smaller **fine adjustment knob** is used to focus when you are using the high power objective.

The slide to be observed is placed on the **stage**. Some microscopes have a mechanical stage which allows you to move the slide without touching it. Such a stage has a **mechanical stage control**. On other microscopes the slide must be moved manually. **Slide clips** hold the slide and steady it when you move it.

Beneath the stage is another lens, the **condenser**, which condenses light onto the slide. Below the condenser is the **diaphragm**. The diaphragm is controlled by the

diaphragm lever or by a **diaphragm ring**. The diaphragm controls the amount of light that passes into the slide. In microscopy, the more light entering the specimen the less resolution or detail you can see. In order to see detail you must reduce the amount of light entering the slide. However, with too little light it will be too dark to see anything! Good microscopy depends upon adjusting the light level to an optimum level maximizing visibility and resolution.

Some microscopes have a rheostat to control the brightness of the light source. If your light has a rheostat, then you may use the rheostat and the diaphragm to control the amount of light. **HINT: EVERY TIME YOU CHANGE SLIDES OR LENSES, READJUST THE LIGHT OR DIAPHRAGM. MAKE THIS A HABIT, AND YOUR EXPERIENCES WITH THE MICROSCOPE WILL BE MUCH BETTER.**

Exercise 2.2

Get your microscope and plug it in. Your teacher may assign a specific microscope to you and have further instructions regarding setting up your microscope. Turn on the light.

Do not look through the ocular until Exercise 2.3. Look down on the stage and adjust the diaphragm or the rheostat if your microscope has one. Notice that the amount of light coming through the stage varies. Adjust so that the light is about half bright.

Be sure that the low power objective is locked into place by turning the revolving nosepiece until you feel a positive "click" with the low power objective pointing down. Turn the coarse adjustment knob and observe what happens. (Either the stage or the nosepiece will visibly move.)

Turn the coarse adjustment knob so that there is maximum distance between the objective and the stage. Turn the fine focusing knob and observe what happens. (Nothing visible to the naked eye will occur.)

Exercise 2.3

Be sure that the low power objective is in place. Put the slide labelled "e" on your stage. Align the "e" over the hole in the stage.

Looking through the ocular turn the coarse adjustment knob until the "e" comes into focus. You may not be able to see the entire "e".

*The circle that you see in the microscope is known as the **field**.*

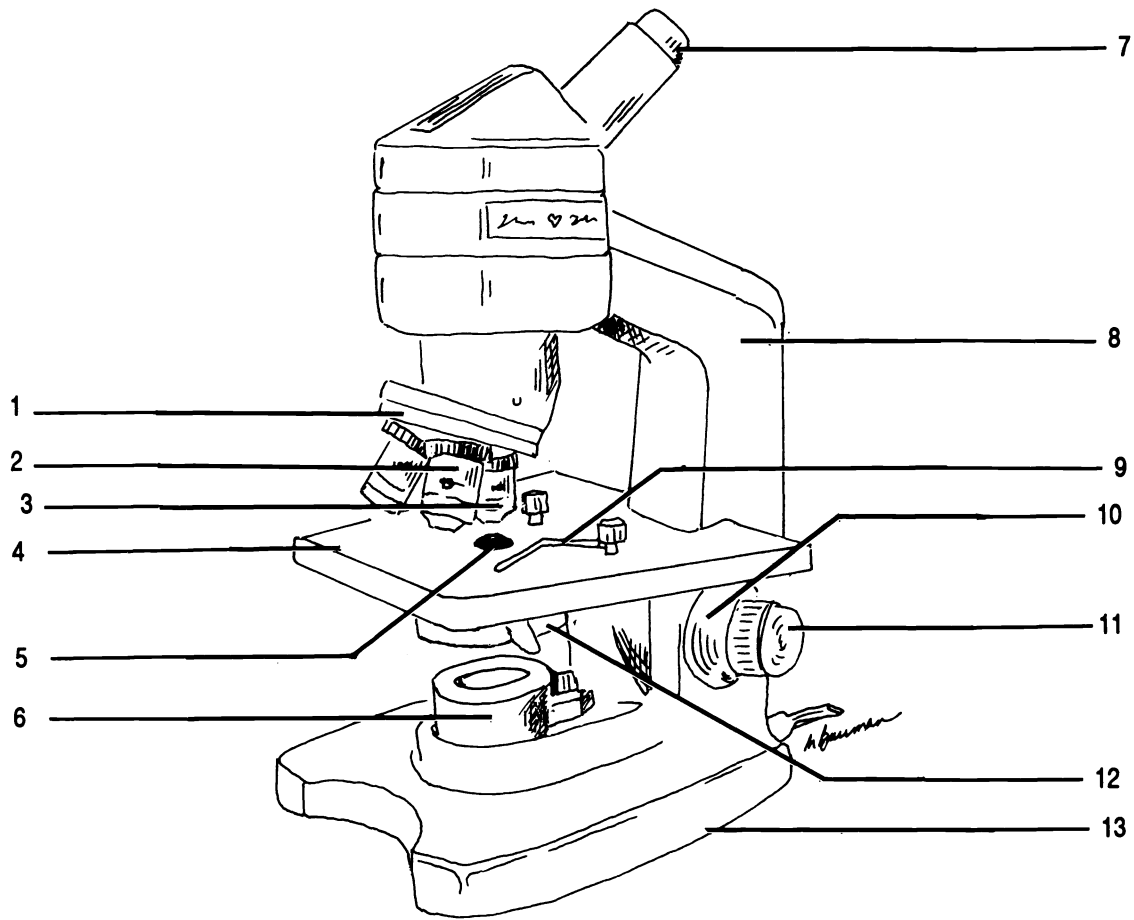


Figure 2.1 Monocular Microscope

Arm Base Coarse adjustment knob Condenser Fine adjustment knob High power objective Iris diaphragm Light
 Low power objective Ocular Revolving nosepiece Slide clip Stage

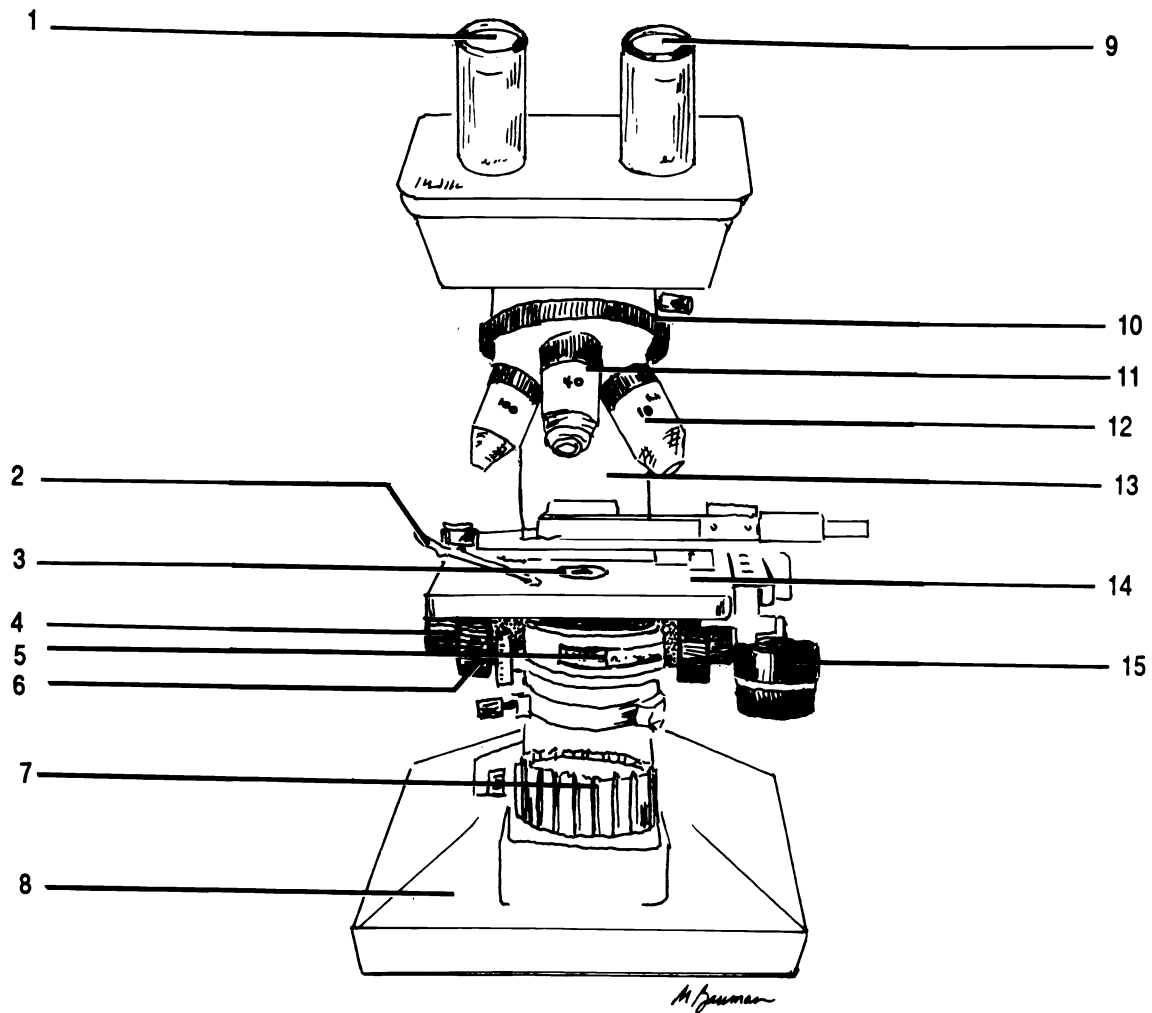


Figure 2.2 Binocular Microscope with Mechanical Stage

Arm Base Coarse adjustment knob Condenser Fine adjustment knob High power objective Iris diaphragm Light
 Low power objective Mechanical stage Mechanical stage controls Ocular (X2) Revolving nosepiece Slide holder

Move the slide to the right. The image in the field moved to the _____.

Move the slide away from you ("up"). Notice that the image moves _____.

Also notice that the "e" on the stage is upside down to the image you see through the ocular.

SUMMARY: MICROSCOPIC IMAGES ARE UPSIDE DOWN FROM THE SLIDE AND MOVEMENTS OF THE SLIDE ARE REVERSED IN THE IMAGE.

Exercise 2.4

Return the "e" to the center of the field.

Be sure that you are in focus using the coarse adjustment knob.

Click the high power lens into position WITHOUT MOVING THE COARSE ADJUSTMENT KNOB OR THE STAGE.

A BASIC RULE: IF YOU SEE NOTHING, START OVER BY FOCUSING WITH THE LOW POWER OBJECTIVE.

Note that your microscope is parfocal. The "e" is almost in focus when you changed lenses.

Use the fine adjustment knob to focus. NEVER USE THE COARSE ADJUSTMENT KNOB WITH THE HIGH POWER OBJECTIVE.

Remember, since you have changed lenses, you should readjust the light.

Does the entire "e" fit into the field? _____

SUMMARY: YOUR MICROSCOPE IS PARFOCAL. DO NOT ADJUST THE COARSE ADJUSTMENT KNOB WHEN YOU MOVE TO THE HIGH POWER OBJECTIVE. AT HIGH POWER THE DIAMETER OF THE FIELD IS CONSIDERABLY LESS.

Exercise 2.5

Return to low power.

Remove and return the "e" slide.

Put the "three colored threads" slide onto the stage.

Focus on low power using the coarse adjustment knob.

(Note that you did not have to focus very much since you were already in focus from the "e" slide.)

Center the point where the red thread crosses the blue thread.

Change to the high power objective. Remember the objective will not hit the stage because your microscope is parfocal.

Use the fine adjustment knob to focus on the red thread.

Is the blue thread still in focus?

Now focus on the blue thread. What happens to the image of the red thread? _____

SUMMARY: AT HIGH POWER THE "DEPTH OF FIELD" IS REDUCED; THAT IS, YOU CANNOT FOCUS ON TWO OBJECTS WHICH LIE AT DIFFERENT DEPTHS FROM OBJECTIVE. A GOOD MICROSCOPIST CONTINUALLY ADJUSTS THE FINE ADJUSTMENT KNOB WHILE LOOKING THROUGH THE HIGH POWER OBJECTIVE. THIS ALLOWS YOU TO VIEW THE SUPERFICIAL AND DEEP REGIONS OF THE SLIDE.

Exercise 2.6

Return the "three colored threads" slide.

Put the "micrometer" slide on the stage. (The slide looks like it has a big "O" on it.)

In the exact center of the "O" is a small ruler, a micrometer. Find the micrometer on low power.

Using the micrometer, measure the width of the field at low power. _____ mm (millimeters)

Move the high power objective into place. REMEMBER DO NOT FOCUS WITH THE COARSE ADJUSTMENT KNOB WHEN USING THE HIGH POWER OBJECTIVE.

Measure the width of the field at high power.

_____ mm

You will notice that some microscopes have a pointer arrow which allows you to point to specific objects in the field. This will be helpful when you want to be sure that you and the instructor are looking at the same object!

Move the micrometer so that a number is visible.

Now move the pointer by turning the ocular so that it points to the number. Try to do this without moving the slide.

Return the low power objective into position.

Turn off the light.

Return your microscope to its storage area.

SUMMARY: THE FIELD IS ACTUALLY SMALLER AT HIGH POWER, THOUGH IT LOOKS THE SAME SIZE. THE POINTER IS BUILT INTO THE OCULAR AND CAN BE ADJUSTED WITHOUT MOVING THE SLIDE.

CHAPTER 2 REVIEW

1. _____ Carry the microscope with (1) hands.
2. _____ Use (2) paper to clean the lenses.
- 3a. _____ When you finish with the microscope you should turn the light (3a) and return the (3b) power objective into the down position.
- 3b. _____
4. _____ What is the total magnification if the ocular is 10X and the objective is 10X?
5. _____ What is the total magnification if the ocular is 10X and the objective is 43X?
6. _____ What is the total magnification if the ocular is 15X and the objective is 40X?
7. _____ If the total magnification is 430 times and the ocular is 10x, what is the magnifying power of the objective?
8. _____ If the total magnification is 225X and the objective is 15X, what is the magnification of the ocular?
9. _____ The objectives are mounted in a (9) .
10. What is the purpose of the diaphragm?

11. _____ What is a micrometer?
12. What is resolution?

13. _____ The circle of light that one sees when looking through the ocular is the (13) .

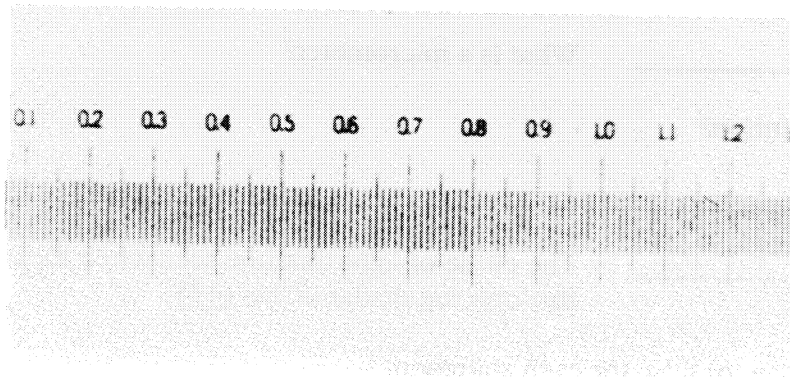
Write the word true or false for each statement.

14. _____ When using high power it is always possible to have everything in the field in focus at the same time.
15. _____ You should always leave the diaphragm full open and the light on full bright.
16. _____ Resolution is increased by reducing the amount of light.

17. _____ The coarse focusing knob is used only with the low power objective.
18. _____ The diameter of the field at low power is less than the diameter of the field at high power.
19. _____ It is better for the light of the microscope to leave it on when you unplug.
20. _____ Lenses can be cleaned with any soft cloth or tissue.
21. _____ The term "depth of field" refers to the diameter of the field.

From the choices given write the entire answer.

22. _____ When you change from low power to high power you will see (more or less?) of the specimen.
23. _____ The light is built into the (arm/base/stage).
24. _____ The pointer is built into the (objective/stage/ocular).
25. _____ The microscope needs little focusing when moving from low to high power because it is (expensive/parfocal).



CELL STRUCTURE

Your body is made up of billions of individual living structures called cells. All cells are different, but most cells have certain common structures called **organelles**. We will study the anatomy of these structures in this chapter. More detail on the anatomy and physiology is given in your textbook.

Exercise 3.1

Figure 3.1 shows a generalized human cell and its basic parts. Using your textbook as a guide, fill in the labels on the figure.

Exercise 3.2

Examine the models of the cell. Be able to identify these parts on the model: cell membrane, Golgi apparatus, lysosome, mitochondrion, nuclear envelope (membrane), nucleolus, nucleus, pinocytosis, RER, ribosomes, SER, and vacuole.

Exercise 3.3

Materials:

*microscope slide with a small drop of iodine in the center
cover slip
toothpick
microscope*

Using a toothpick scrape off a few cells from the inside of your cheek. Do not draw blood!

Float the cells off the toothpick into the drop of iodine. (The iodine will stain the cell and allow you to see them more clearly. Iodine also kills the cells.)

Put the coverslip on the drop and mount the slide on the microscope.

View the cells. Remember to start with the low power objective. Switch to high power when you are in focus. Readjust the light when you change lenses.

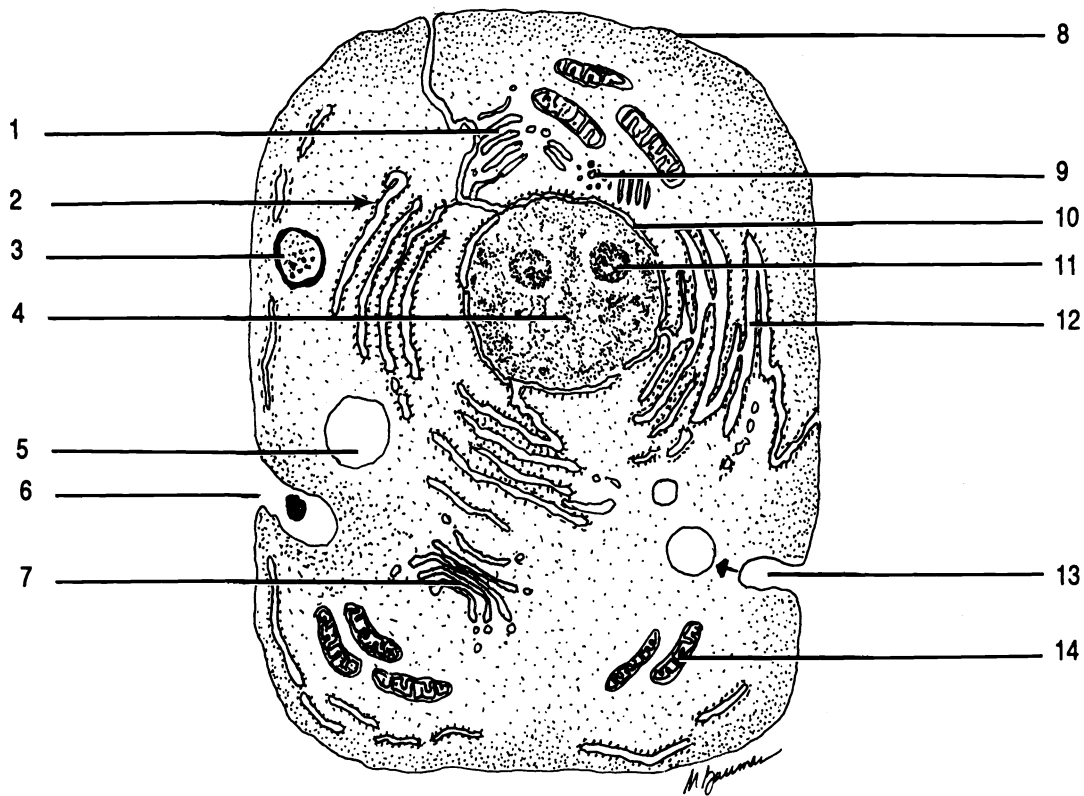


Figure 3.1 Generalized Human Cell

Cell membrane (plasma membrane, plasmalemma) Centriole Golgi complex Lysosome Mitochondrion Nuclear membrane (envelope) Nucleus Nucleolus Phagocytosis Pinocytosis Ribosome Rough endoplasmic reticulum (RER) Smooth endoplasmic reticulum (SER) Vacuole

Color each part of the cell a different color using crayons or colored pencils.

Sketch three cells in the space below. Label the nucleus, nucleolus (if visible), and cell membrane. All other organelles are too small to be seen with a light microscope. An electron microscope must be used.

Exercise 3.4

Clean your slide and coverslip with a lens paper.

Place a small drop of pond water on the slide.

Replace the cover slip.

Observe the organisms. Look for nuclei, nucleoli, cell membranes, cilia, flagella, and vacuoles.

Generally the green organisms are algae, the blue-green ones are photosynthetic bacteria, and the colorless ones are one-celled animals. Sometimes the animals eat the other organisms and therefore appear colored.

Discard your slide and coverslip when you are finished.

Remember to turn off the light and return the low power objective into the down position. Return the microscope to its storage area.

CHAPTER 3 REVIEW

1. _____ The “control center” of the cell is the (1).
2. _____ Inside the nucleus there are one or two (2).
3. _____ The outer boundary of the cell is a sack called the (3).
4. _____ Between the nucleus and the cell membrane there is a jelly-like substance called (4) which contains many submicroscopic organelles.
5. _____ The organelle called a “suicide sac” or “digestive vacuole” is the (5).
6. _____ Which organelle produces most of the energy for the cells and is thus known as the “powerhouse”?
7. _____ Small, hairlike, moveable protrusions of the cell membrane which allow the cell to move material past its surface are called (7).
8. _____ Small extensions of the plasma membrane which do not move but which do increase surface area for absorption are (8).
9. _____ Proteins and other substances can be packaged for export by the (9).
10. _____ Movement through the cell is conducted in the tubes which make up the rough (10) and the
11. _____ (11) endoplasmic reticulum.
12. _____ The rough endoplasmic reticulum is rough because of the presence of (12) on its surface.
13. _____ Ribosomes are the site of (13) synthesis in the cell.
14. _____ The (14) plays a role in nuclear division.

MITOSIS

Cells divide to form daughter cells. Before they can divide however, the nucleus must divide so that each daughter cell will have the correct instructions (genes) to carry out its function. Division of the nucleus in somatic (body) cells is called **mitosis**. Division of the cell itself is called **cytokinesis**. Mitosis must occur before cytokinesis can occur, but cytokinesis does not have to occur after mitosis. For instance, some cells undergo mitosis but not cytokinesis and thus end up with more than one nucleus.

Although mitosis is a continuous process, it has historically been divided into four stages. These stages can be recognized by certain features. The acronym "PMAT" may help you remember the order in which the phases occur.

Exercise 4.1

As you read, label each diagram in Figure 4.1.

Prophase. In this stage the nuclear membrane breaks down and the **chromosomes** become visible. Chromosomes contain the genetic material, DNA, which contains the instructions for all of the body's anatomy and physiology. Each chromosome is composed of two **chromatids** which are held together by a **centromere**. Do not confuse the centromere with the centrioles which are larger organelles of the cell.

During prophase the two centrioles move to opposite ends of the cell and a **spindle** of visible fibers called microtubules forms from one pole of the cell to the other.

Metaphase. This phase is characterized by the movement of the chromosomes to line up in the middle of the spindle. The chromosomes attach to the spindle by means of the centromeres.

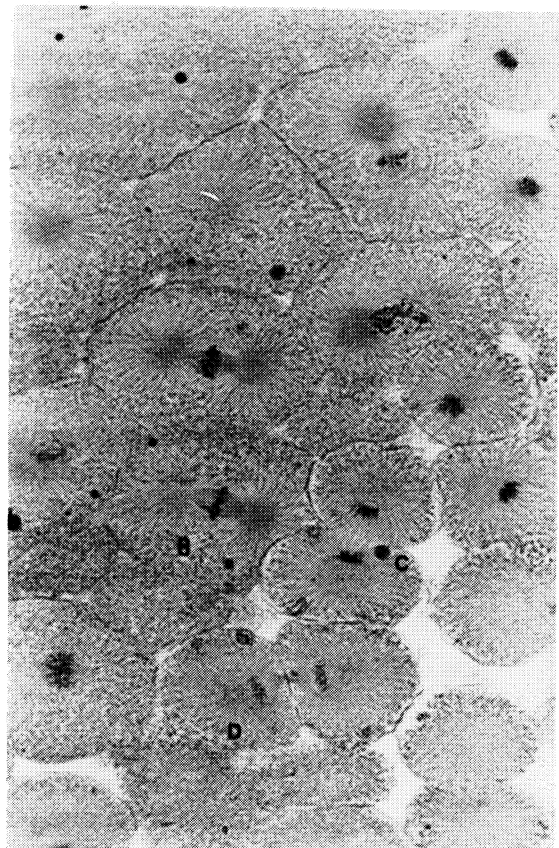
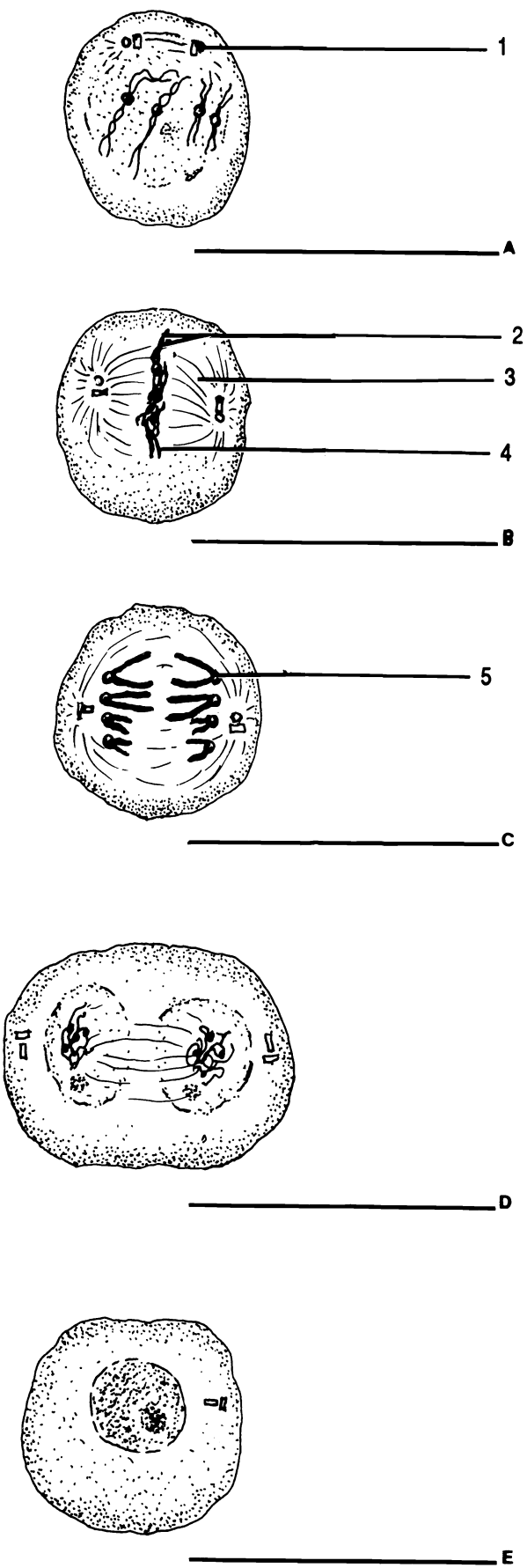


Figure 4.1 Mitosis and Interphase

Anaphase Centromere Centriole Chromatid
 Chromosome Interphase Metaphase Prophase
 Spindle Telophase

Anaphase. The metaphase chromosomes seem to pull apart by the action of some of the spindle fibers. The chromosome becomes two individual chromatids which, unfortunately, are now called chromosomes. The two anaphase chromosomes (formerly chromatids) move toward the poles of the cell.

Telophase. This phase is like prophase in reverse. The separated chromosomes begin to disappear and the nuclear membrane reappears. If cytokinesis is going to take place it usually begins during telophase. Remember that mitosis and cytokinesis are separate events, though they may occur at the same time.

It is often difficult to determine if a cell is in prophase or telophase. A general "rule of thumb" is that if two adjoining cells are in this state, they are probably daughter cells and the nuclei are daughter nuclei in telophase. If a single set of unaligned chromosomes is present then it is probably prophase.

INTERPHASE

Interphase is not a stage of mitosis. Interphase is the time a nucleus spends between mitoses (plural of mitosis). During this time the DNA of the nucleus is replicated in preparation for the next mitosis.

Exercise 4.2

Examine the models of mitosis. Be sure that you can identify the phase of mitosis represented by each model and that you can place the models in correct sequence.

Exercise 4.3

Examine prepared slides of whitefish blastulae. Each slide contains more than one section through the blastula. Start with low power to locate the section of the blastula, then change to high power to see the individual cells and their nuclei.

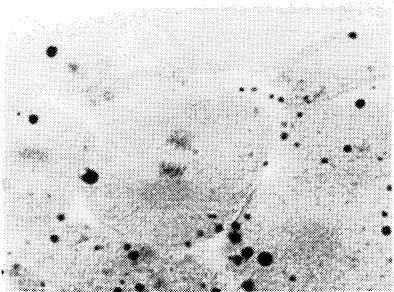
Draw each of the four phases of mitosis. You may have to examine more than one section or more than one slide to locate all of the phases.

CHAPTER 4 REVIEW

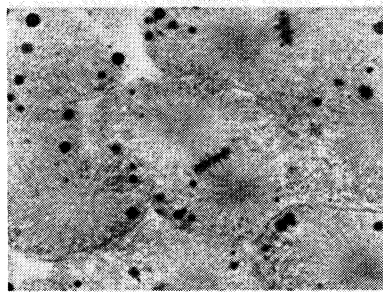
1. _____ The genes of a cell are contained in the chemical (1).
2. _____ During prophase the DNA condenses to form visible structures called (2).
3. _____ The two identical parts of each metaphase chromosome in mitosis are (3).
4. _____ List the phases of mitosis in order.
5. _____
6. _____
7. _____
8. _____ After chromatids are pulled apart in anaphase, they are called (8).
9. _____ The (9) is a system of microtubules which forms during prophase.
10. _____ Some of these microtubules pull the chromatids apart during (10).

Write the word true or false for each statement.

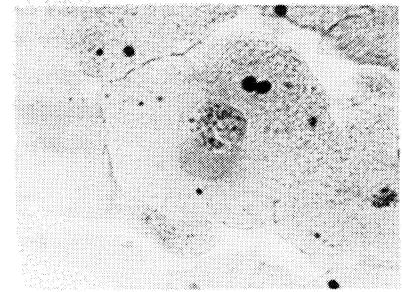
11. _____ Cytokinesis and mitosis mean essentially the same thing.
12. _____ Mitosis and cell division are the same thing.
13. _____ The final phase of mitosis is interphase.
14. _____ The centriole is an organelle which appears to play a part in mitosis.
15. _____ Chromosomes begin to move apart during anaphase of mitosis.



16. _____



17. _____



18. _____

HISTOLOGY

Cells in the body do not function alone. They are organized into tissues. A tissue is a group of cells organized for a common purpose. The study of tissues is **histology**. There are four basic types of tissues in the human body: epithelial, connective, nervous, and muscular. This chapter will deal with epithelial and connective tissues. Nervous and muscular tissues will be discussed in the chapter dealing with the nervous and muscular systems respectively.

EPITHELIAL TISSUES

Epithelial tissues are characterized by tightly packed cells with little or no intercellular material. Epithelial tissues are always attached to underlying connective tissue by a **basement membrane** (Figure 5.1) which acts like glue. Epithelial tissues cover the body and line the cavities of the body. Additionally, epithelial tissues form the secretory portions of glands.

There are eight types of epithelial tissues. These types can be determined microscopically by first noting how many layers of cells are in the tissue and secondly the type of cells in the superficial layer.

If there is a single layer of cells, the tissue is **simple epithelium**. If there is more than one layer of cells, the tissue is **stratified epithelium**.

The three types of cells found in epithelial tissues are: **squamous**, **cuboidal**, and **columnar**. Squamous cells are flat and irregularly shaped while cuboidal cells have basically the same width, length, and height. These cells look like cubes with rounded corners.

Columnar cells are characterized by being taller than they are wide. They show the most variation of all epithelial cells. Columnar cells can be ciliated or unciliated. Some columnar cells have many microscopic folds of their cell membranes called microvilli. A **goblet cell** is a

special columnar cell shaped like a goblet. Goblet cells secrete mucus.

An epithelial tissue takes its name from the shape of the cells in the superficial layer regardless of the shape of the cells in other layers.

By combining the two criteria of epithelial tissues, we have six categories: simple squamous, simple cuboidal, simple columnar, stratified squamous, stratified cuboidal, and stratified columnar. The two remaining epithelial tissues are special cases.

Pseudostratified (*pseudo* = Gr. false) **epithelium** is in reality a simple tissue. That is, it is composed of one layer. However, because the cells of this tissue are different in size they give the appearance of being stratified. Pseudostratified tissue can be identified microscopically by the presence of various sized cells (cuboidal and columnar) all of which contact the basement membrane.

The second special epithelial tissue is **transitional**. Transitional epithelium lines the urinary bladder. It looks like stratified cuboidal epithelium except that the uppermost cells have a free, rounded appearance.

Exercise 5.1

Label the drawings in Figure 5.1 with the correct names of the tissues.

Exercise 5.2

Fill in the chart below with the appropriate terms.

Epithelial Tissues

<i>(one layer)</i>		<i>(more than one layer)</i>	
1. _____	<i>(flat cells)</i>	1. _____	<i>(flat cells)</i>
2. _____	<i>(cubed cells)</i>	2. _____	<i>(cubed cells)</i>
3. _____	<i>(tall cells)</i>	3. _____	<i>(tall cells)</i>
4. _____	<i>(many sizes)</i>	4. _____	<i>(bladder)</i>

Which cells can be ciliated? _____

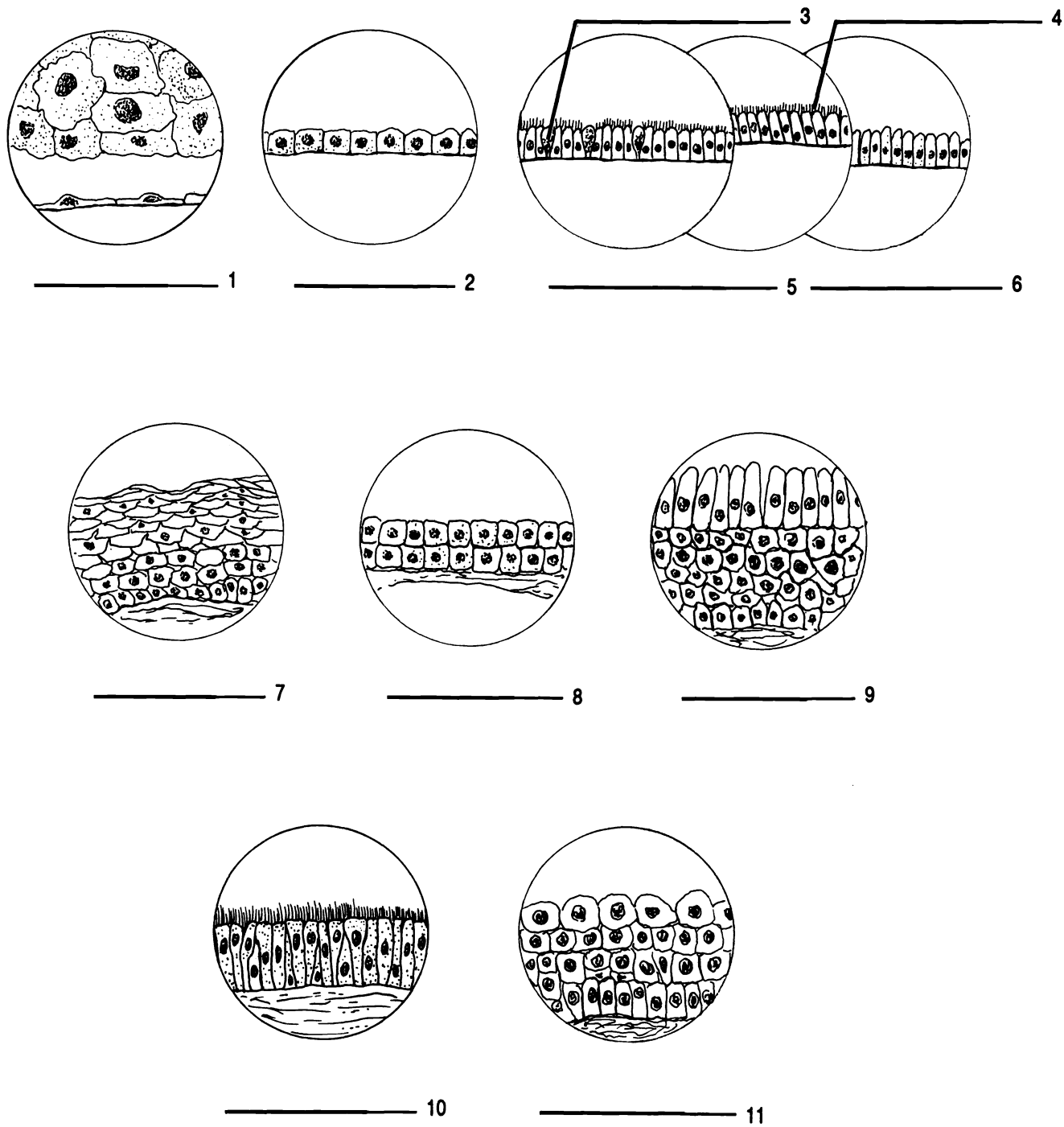


Figure 5.1 Epithelial Tissues

Cilia Goblet cell Pseudostratified, ciliated Simple columnar, ciliated Simple columnar, unciliated Simple cuboidal
 Simple squamous Stratified columnar Stratified cuboidal Stratified squamous Transitional

Examine and sketch the following tissues as seen with a microscope: simple squamous, stratified squamous, simple cuboidal (kidney tubules), simple columnar (intestinal lining), and transitional (urinary bladder).

As you examine the tissues, ask yourself these questions:

- 1. How many layers of cells are there in the epithelium?*
- 2. What is the shape of the cells in the superficial layer?*
- 3. If there are columnar cells, do they have cilia? Do they have microvilli?*

Be able to identify each of these tissues from a drawing, a description, and microscopically.

CONNECTIVE TISSUE

Connective tissues are found throughout the body. They are characterized by widely spaced cells (with one exception), and a large amount of non-living, intercellular material called the **matrix**. The basic function of connective tissues is to connect things together. There are eleven connective tissues. Three of these: blood, compact bone, and cancellous bone are more thoroughly discussed in the chapters on blood and skeletal tissue respectively.

The other connective tissues can be determined by the answers to two questions: 1. Are the cells in lacunae? 2. What kind of fibers are in the tissue? Before you can answer the questions, you must have a thorough understanding of lacunae and fibers!

Lacunae (sing. - lacuna) are holes within the matrix of the tissue. The cells of the tissue live inside these holes like hermits in a cave.

There are three kinds of fibers found in connective tissues. These are **collagenous**, **elastic**, and **reticular**. Collagenous fibers (also called dense, white, and regular) are composed of the protein **collagen**. They are white, long, unbranched, tightly packed, and often assume a wavy appearance. Elastic fibers are composed of the protein **elastin** and are elastic, that is they return to their original shape when they are stretched and released. Elastic fibers are branched. Reticular (*reticulum* = L. net) fibers are also branched. The branching pattern of reticular fibers is such that they form a net-like arrangement.

To identify connective tissues under the microscope ask and answer two questions: 1. Are the cells in lacunae? If so, you are looking at either osseous or cartilaginous material, and 2. What kinds of fibers are present? There may be none, one, or three kinds of fibers visible.

1a. Cells in lacunae.

There are two kinds of osseous tissue, **compact** and **cancellous** (spongy). The matrix of compact bone is organized into columns of concentric rings (osteons). The matrix of cancellous bone has a sponge-like appearance. Osseous tissue is easily identified if you have seen it once. These two tissues are covered in more detail in chapter seven.

Cartilaginous material can be divided into three groups. **Hyaline** cartilage or gristle has no visible fibers, though they are present. **Elastic** cartilage has many elastic fibers and **fibrocartilage** contains bundles of collagenous fibers. Cartilages do not contain blood vessels. The cells of cartilages are called **chondrocytes** (*chondros* = Gr. cartilage; *cytos* = Gr. cell).

1b. Cells not in lacunae.

Connective tissues which do not have lacunae are called "connective tissues proper". There are five types determined by the kinds of fibers which are present.

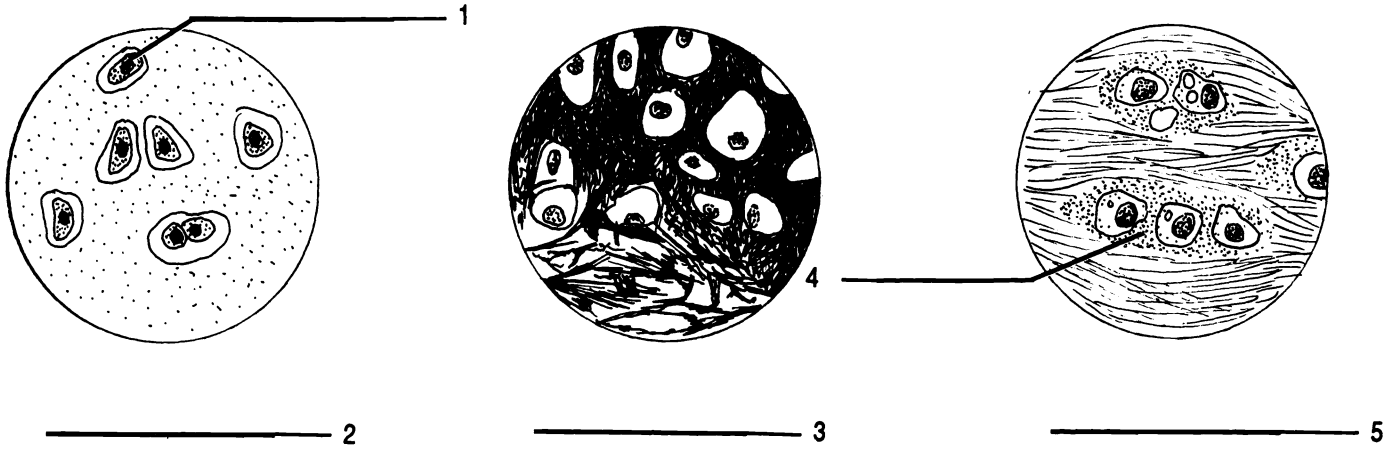
Areolar tissue has an airy, "cotton-candy" appearance. All three types of fibers, collagenous, elastic, and reticular, can be found in areolar tissue. **Reticular** connective tissue contains reticular fibers, **elastic** connective tissue has elastic fibers, while **dense** connective tissue has collagenous (dense) fibers. Dense connective tissue is also called **collagenous**. **Adipose** or fat tissue has no visible fibers. Adipose tissue is an exception among connective tissues in that the cells are packed together and there is no large amount of matrix.

A final, special connective tissue is **vascular** or **blood** tissue. This connective tissue is the only liquid tissue in the body. Blood will be covered in more detail in chapter twenty-six.

Exercise 5.4

Write the correct name of each connective tissue into the blanks of Figure 5.2.

CARTILAGES



CONNECTIVE TISSUE PROPER

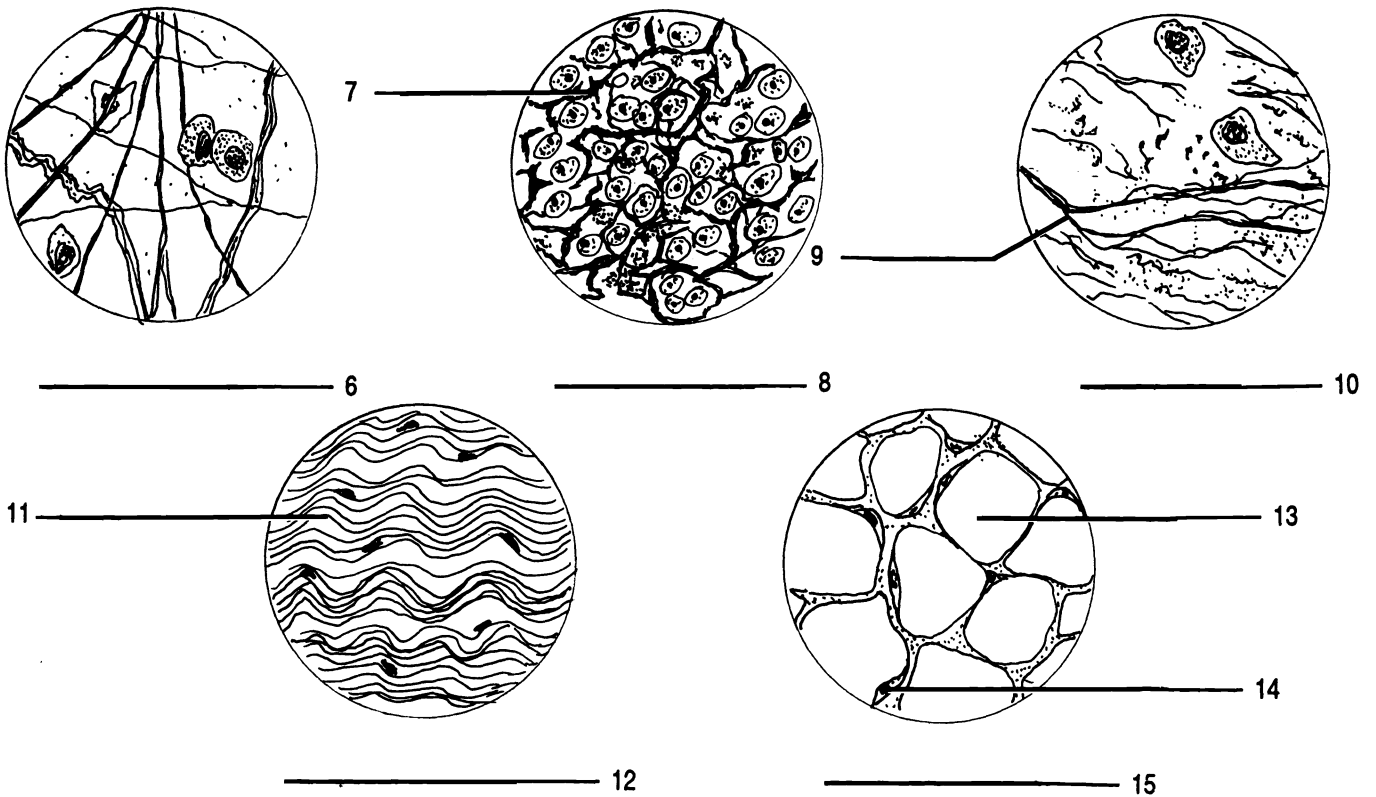


Figure 5.2 Connective Tissues

Adipocyte Adipose Areolar Chondrocyte Collagen (fiber) Collagenous (tissue) (dense, white) Elastic (X2) Elastic
 fiber Fibrocartilage Hyaline Lacuna Nucleus (of cell) Reticular Reticular fiber

Exercise 5.5

Fill in the chart below with the appropriate terms.

Connective Tissues	
<i>(cartilage, cells in lacunae)</i>	<i>(cells not in lacunae)</i>
<i>fibers</i>	<i>fibers</i>
1. _____ <i>(none visible)</i>	1. _____ <i>(none visible)</i>
2. _____ <i>(elastic)</i>	2. _____ <i>(elastic)</i>
3. _____ <i>(collagen)</i>	3. _____ <i>(collagen)</i>
	4. _____ <i>(reticular)</i>
	5. _____ <i>(all three)</i>
<i>(osseous, cells in lacunae, blood vessels present)</i>	<i>(special connective tissue)</i>
1. _____ <i>(no osteons)</i>	1. _____ <i>(liquid)</i>
2. _____ <i>(osteons)</i>	

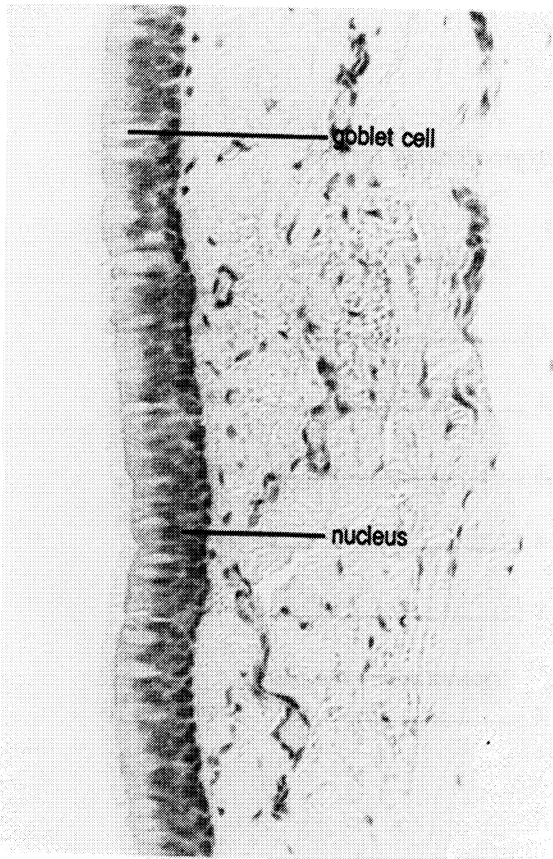
Exercise 5.6

Examine and sketch the following tissues as seen with a microscope: adipose, areolar, blood, cancellous bone, compact bone, dense (collagenous) connective, elastic cartilage, reticular connective, fibrocartilage, and hyaline cartilage.

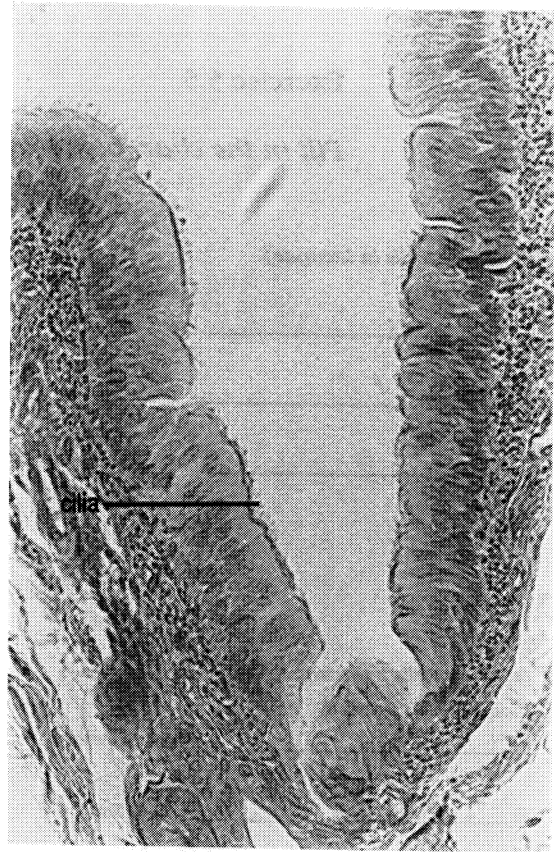
As you examine the tissues, ask yourself these questions:

1. Are the cells in lacunae?
2. Which types of fibers are visible?

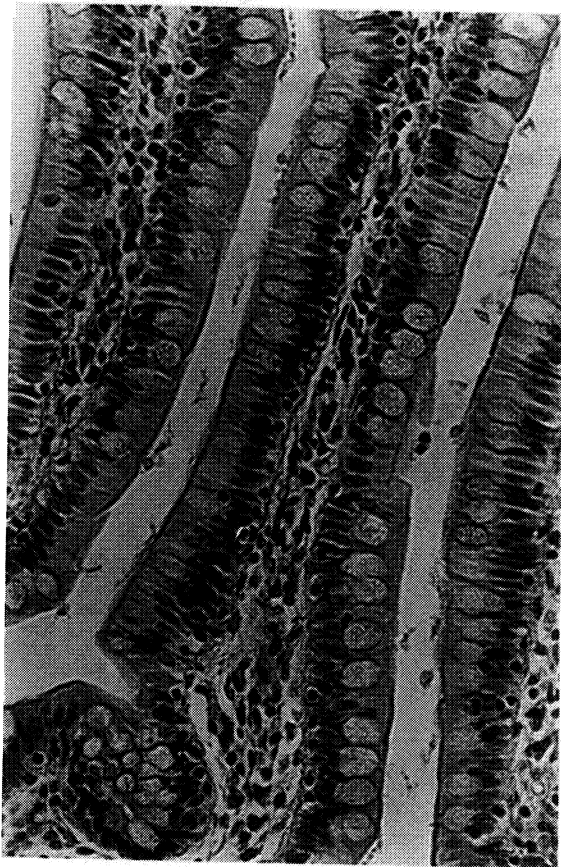
Be able to identify each of these tissues from a drawing, a description, and microscopically.



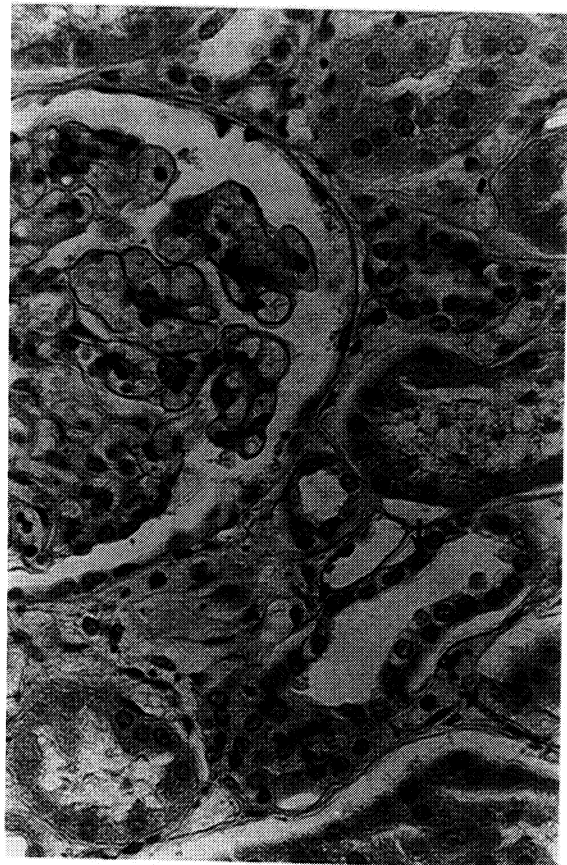
Pseudostratified, ciliated



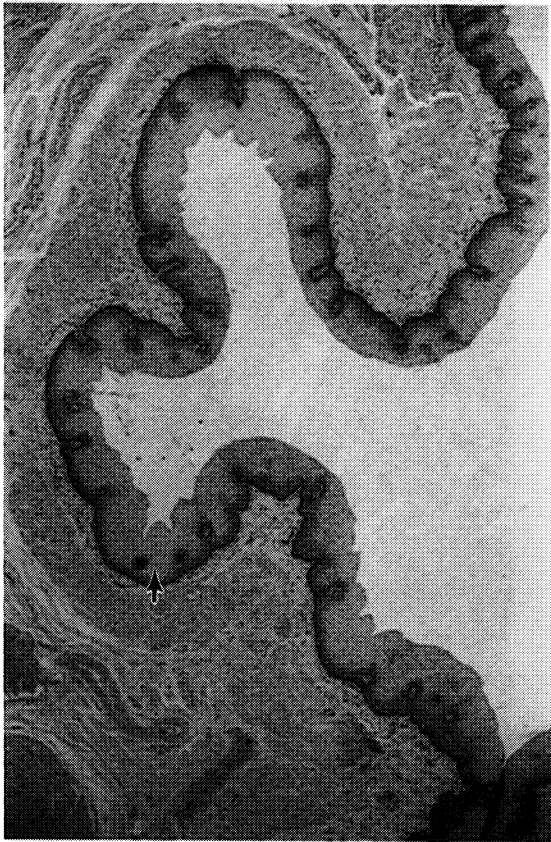
Pseudostratified, ciliated



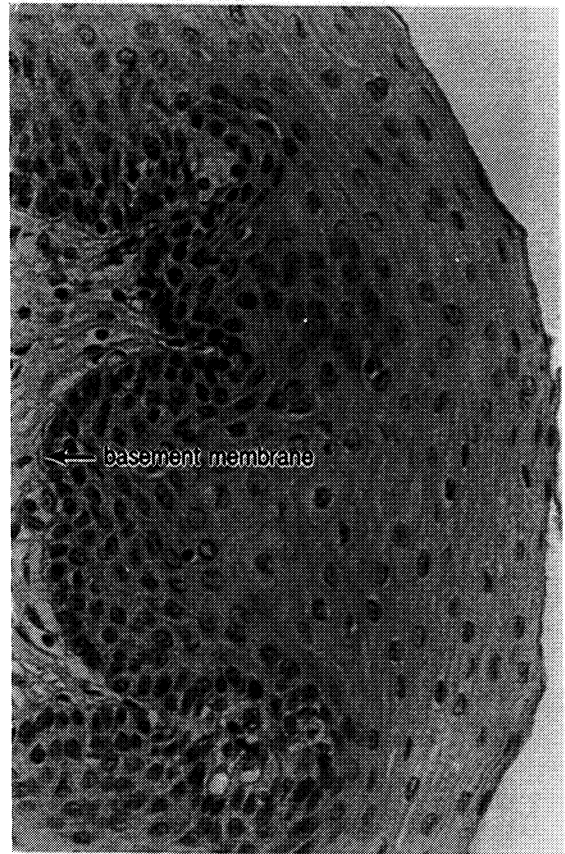
Simple columnar



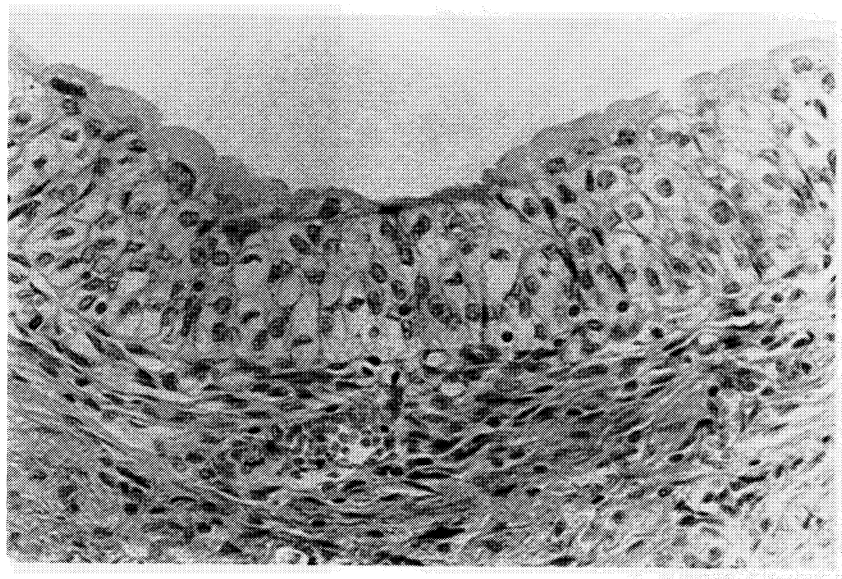
Simple cuboidal



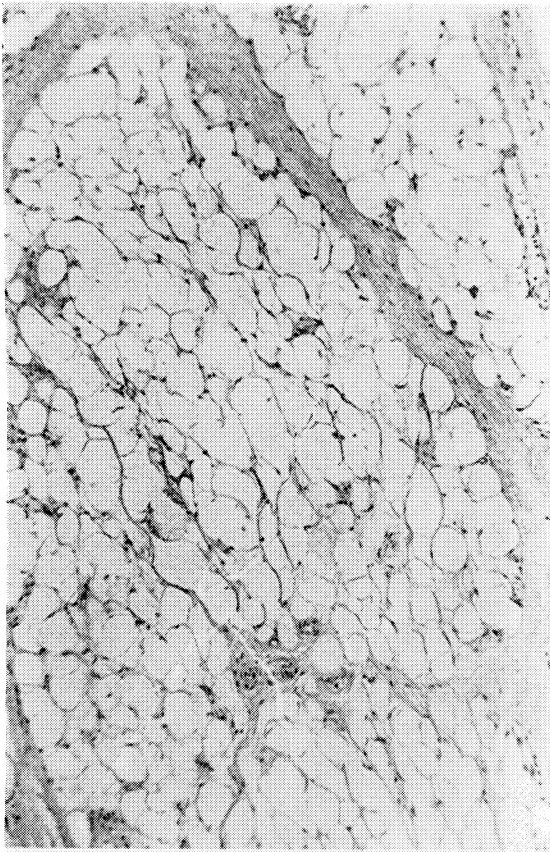
Stratified Squamous



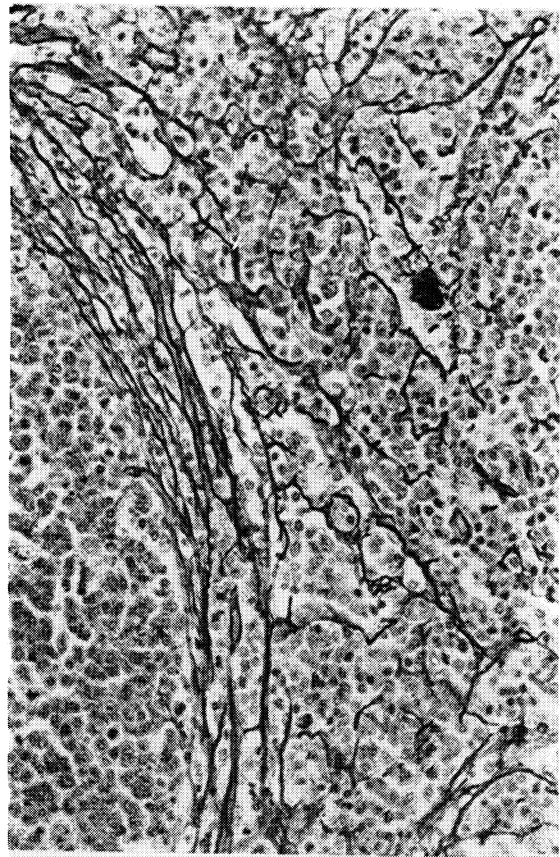
Stratified Squamous




Transitional




Adipose



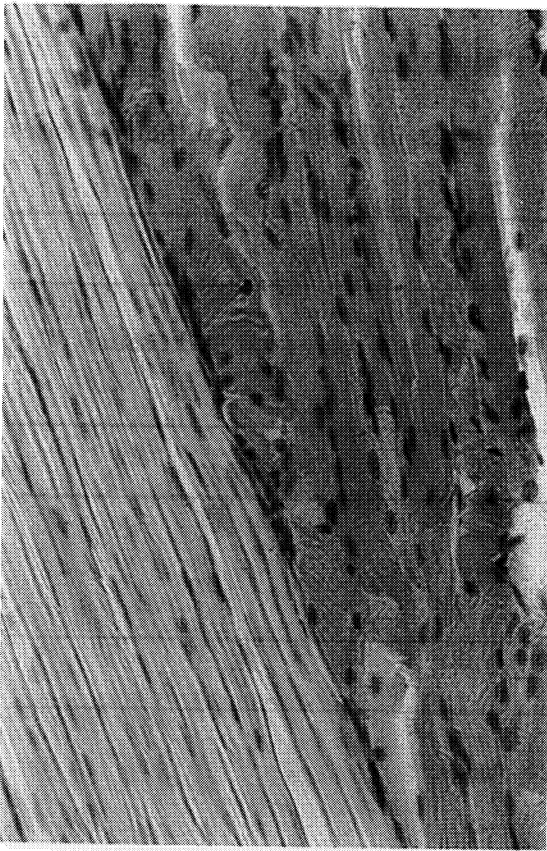
Reticular



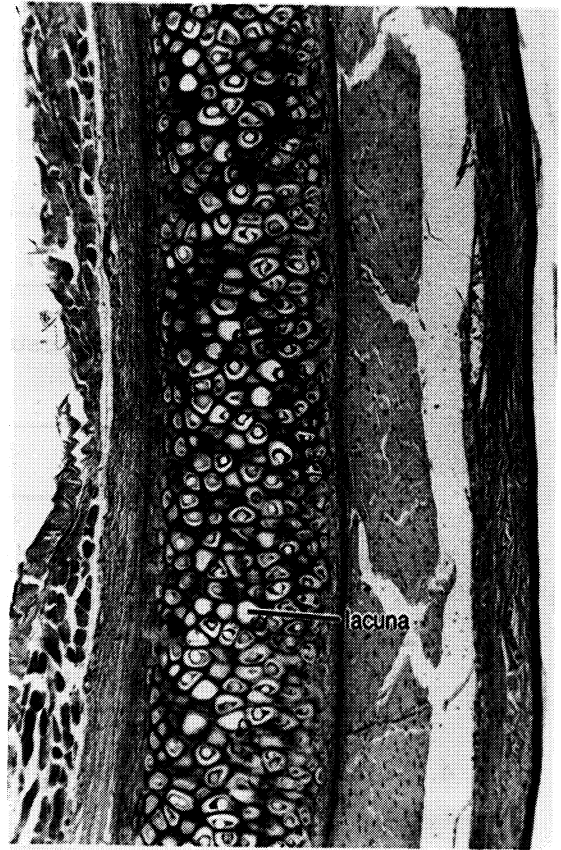
Areolar



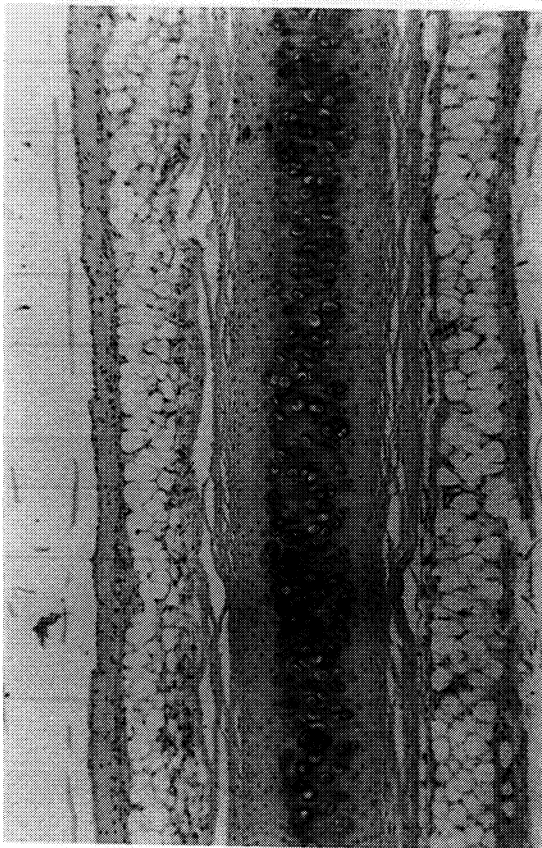Elastic



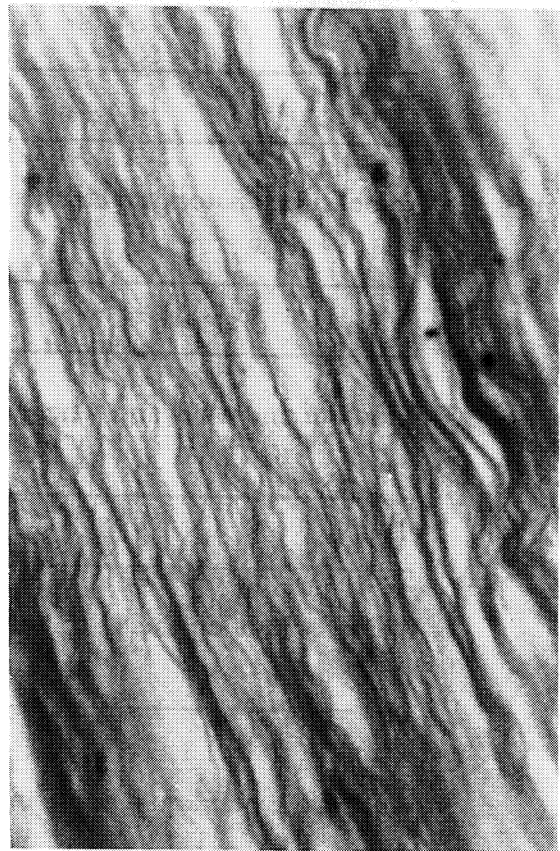
Collagenous



Elastic cartilage



Hyaline cartilage



Fibrocartilage

CHAPTER 5 REVIEW

1. How can you tell the difference between simple and stratified epithelial tissues?

2. Why isn't pseudostratified tissue considered to be a truly stratified tissue?

3. What is the purpose of a goblet cell?

4. Which epithelial tissue lines the urinary bladder?

5. What are the three basic functions of epithelial tissues?

6. Name three anatomical characteristics of all epithelial tissues.

7. What are microvilli and where are they found?

8. Which type of epithelial cells may have cilia?

9. What is the one liquid tissue in the body?

10. Besides being connective tissues, how are adipose and hyaline cartilage alike? How are they different?

11. Which three connective tissues contain elastic fibers? How can you tell these three apart?

12. How are cartilage and bone different?

13. Give two characteristics of all connective tissues (except adipose).

14. How are cartilage and bone different from the connective tissues proper?

15. List and describe the three types of fibers found in connective tissues.

THE INTEGUMENT

Tissues are organized in the body to form organs and systems. The integumentary system is composed of the skin (integument), nails, hairs, glands, and associated muscles and neurons (nerve cells).

The integument can be divided into two layers, the **dermis** (*dermis* = Gr. skin) and **epidermis** (*epti* = Gr. upon). The dermis is composed of connective tissue containing blood vessels, neurons, and glands. The superficial 20% of the dermis is called the **papillary layer** because of the bumps or **papillae** which characterize the surface of the region. The **reticular layer** accounts for the deeper four-fifths of the dermis.

Some of the dermal papillae contain **Meissner's corpuscles**, which are nerve endings sensitive to touch. The reticular layer contains nerve endings called **Pacinian corpuscles** that are sensitive to pressure.

The epidermis can be divided into four or five layers or strata (sing. - stratum). These are the **stratum basale**, **stratum spinosum**, **stratum granulosum**, **stratum lucidum**, and **stratum corneum**. Since the superficial cells of the stratum corneum are squamous, the epidermis is a stratified, squamous epithelial tissue which covers the body. The stratum lucidum occurs only in the palms and soles.

Deep to the dermis is the **hypodermis** (*hypo* = Gr. under) which attaches the skin to the underlying structures.

A notable feature of the integument is the presence of hairs (**pili**, sing. - **pilus**) located within a tube of epithelial cells called the **hair follicle**. The **shaft** of the hair is composed of packed, keratinized cells produced in the proximal end or **root**. The root is enlarged to form a **bulb**. Within the bulb is an involution, the **hair papilla**, through which the cells of the root are nourished. The entire root is enclosed in **external** and **internal root sheaths** which are infoldings of the epithelium.

There are two accessory structures associated with each pilus. The **arrector pili muscle** serves to move the hair into a vertical position. In animals this traps a layer of air and insulates the body during cold weather. The motion of the pilus against the epidermis causes the epidermis to buckle forming a "goosebump".

The **sebaceous gland** secretes **sebum**, an oily substance, onto the shaft of the hair. The sebum keeps the hair pliable and adds the waterproofing of the skin.

The deeper glands shown in Figure 6.1 are **sudoriferous** or **sweat glands**. There are two types of sudoriferous glands. Those with ducts which open directly onto the surface of the epidermis are termed **merocrine (eccrine) sudoriferous glands**. The glands which secrete into the hair follicle are **apocrine sudoriferous glands**. They can be found in the skin of the axillae (armpits), genital areas, nasal canal, and external ear canal.

Exercise 6.1

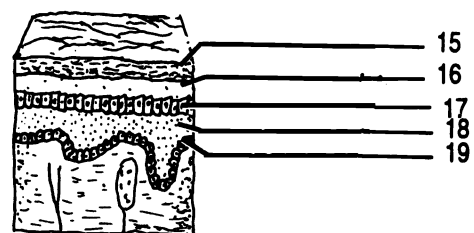
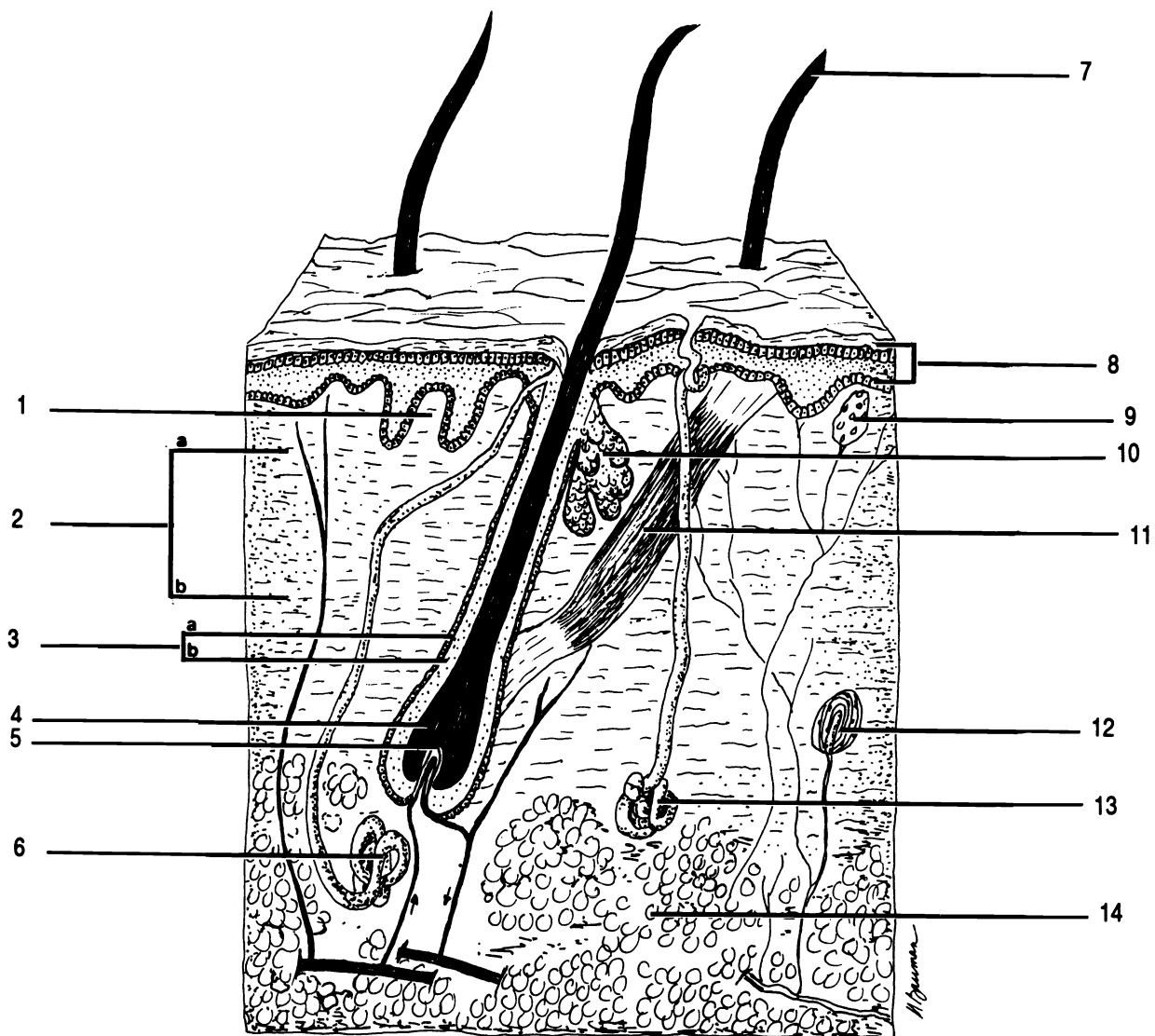
Using your textbook as a guide, label Figure 6.1.

Exercise 6.2

Examine the models of the integumentary system. Be able to identify the layers of the dermis and of the epidermis, arrector pili muscle, bulb, hair papilla, pilus, root sheaths of hair follicle, sebaceous (oil) gland, and sudoriferous (sweat) glands (two kinds).

Exercise 6.3

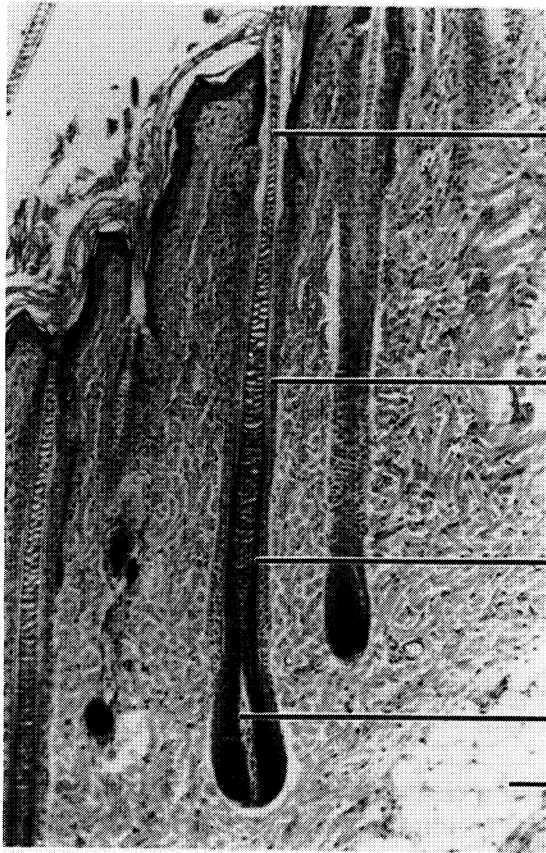
Examine both a prepared slide of hairy skin and one of skin from the sole or palm. Identify all of the structures listed in Exercise 6.2. You may have to look at several slides to find all of the structures. The stratum basale is composed of the deepest, columnar cells of the epidermis. Cells in the stratum spinosum are spiny in some sections, while the cells of stratum granulosum contain grains of keratin (a waterproofing substance) and generally stain more darkly. Stratum corneum is the superficial layer in hairy skin. The clear cells of stratum lucidum can be seen deep to stratum corneum in non-hairy skin.



THICK SKIN (= NON-HAIRY SKIN)

Figure 6.1 Integumentary System

Apocrine sudoriferous gland Arrector pili muscle Bulb Dermal papilla Dermis Eccrine sudoriferous gland Epidermis
 External root sheath Hair follicle Hair papilla Hypodermis Internal root sheath Meissner's corpuscle (touch)
 Pacinian corpuscle (pressure) Papillary layer (region) Pilus Reticular layer (region) Sebaceous gland Stratum
 basale (germinativum) Stratum corneum Stratum granulosum Stratum lucidum Stratum spinosum



root

external root sheath

internal root sheath

hair papilla in bulb

adipose

Hair follicle

CHAPTER 6 REVIEW

1. _____ List the layers of the epidermis in order from superficial to deep.
2. _____
3. _____
4. _____
5. _____ What kind of tissue is found in the epidermis?
6. How is an apocrine sweat gland different from a merocrine one?

7. Why is the papillary layer called "papillary"?

8. _____ In which area of the body could you find the stratum lucidum?
9. _____ Is there a clear line or structure separating the reticular layer from the papillary layer of the dermis?
10. _____ What is the function of the arrector pili muscles?
11. _____ What is the function of the Meissner's corpuscle?
12. _____ What is the function of the Pacinian corpuscle?
13. _____ Specifically, what causes "goosebumps" during cold weather?
14. _____ What is the secretion of a sebaceous gland?
15. _____ What is the scientific name for all sweat glands?

OSSEOUS TISSUE

In chapter five you were introduced to osseous or bone tissue. There are two kinds of bone, **compact** and **cancellous**. These two types occupy different regions of bones, have different functions, and are histologically distinct.

Compact osseous tissue makes up the strong outer portion of bones. This type of bone is composed of tightly packed cylindrical structures called **osteons** (*osteon* = Gr. bone). Each osteon is composed of concentric rings of mineral called **lamellae** surrounding a **central canal**. Within the lamellae are lacunae containing the bone cells (**osteocytes**). The lacunae are connected to one another by small channels called **canaliculi**. Cytoplasmic extensions of osteocytes fill the canaliculi allowing diffusion of nutrients and wastes from one osteocyte to another and eventually to the blood vessels in the central canal. Central canals of adjoining osteons are connected by **perforating canals** which also contain blood vessels.

Cancellous tissue is found within bones and is the site of blood cell production. Cancellous bone is a spongy structure composed of overlapping plates of matrix called **trabeculae**. Blood is formed within the spaces between trabeculae.

Covering the outside of the bone is a collagenous sheath, the **periosteum** (*peri* = Gr. around), which is held to the bone by **Sharpey's fibers**. These fibers are extensions of the collagen fibers of the periosteum. The Sharpey's fibers extend into the matrix of the osteons.

Exercise 7.1

Correctly label Figure 7.1 using the terms at the bottom. Use your textbook to help you identify the various parts.

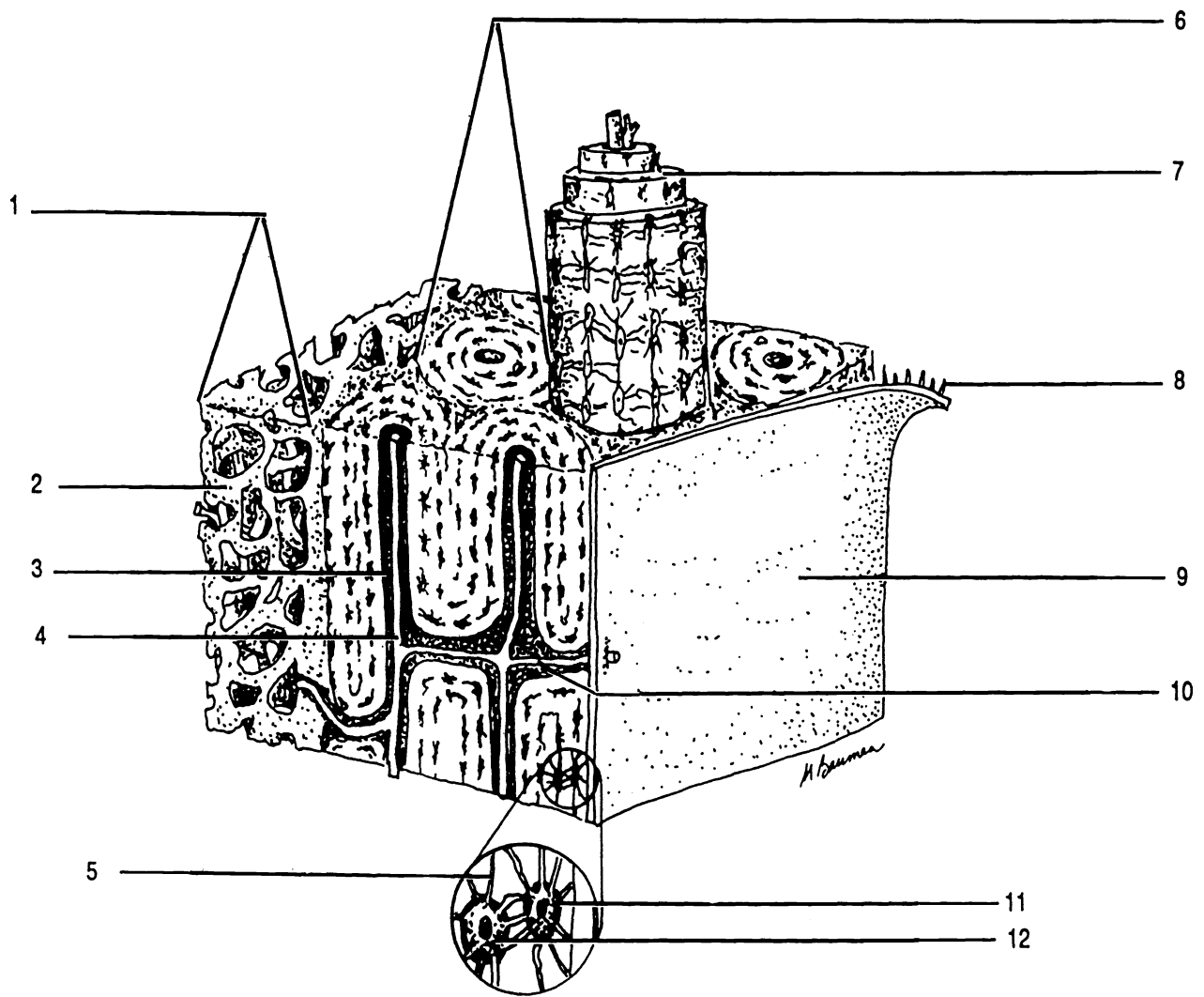


Figure 7.1 Osseous Tissue

Blood vessel Canaliculus Cancellous bone Central canal Lacuna Lamella Osteocyte Osteon Perforating canal
 Periosteum Sharpey's fiber Trabeculae

CHAPTER 7 REVIEW

1. How is an osteocyte different from a chondrocyte (see chapter five)?

2. Osteocytes are enclosed within lacunae. Most osteocytes do not have a direct blood supply. How do these distant osteocytes acquire nutrients and rid themselves of waste?

3. What is the name of the concentric rings which make up an osteon?

4. How are osteons held together?

5. What is another name for an osteon?

6. What structures can be found within the central canal of an osteon?

7. Anatomically speaking, how is a central canal different from a transverse canal?

8. What is the name of the collagenous connective tissue which covers the outer surfaces of bones?

9. How is this connective tissue held onto the bone?

10. What is the name of the bony matrix structures within cancellous bone?

THE SKELETAL PLAN

The human skeleton is composed of 206 bones. These bones are arranged in two groups: the **axial skeleton** which is composed of the central bones of the body (skull, hyoid, ribs, sternum, and vertebral column) and the **appendicular skeleton** which contains the bones of the shoulder and pelvic girdles and of the arms and legs.

All bones can be grouped according to their shape: long, short, flat, and irregular, or according to their location: **sutural** and **sesamoid**. Sutural bones are located between the bones of the skull. They do not occur in all individuals. Sesamoid bones are bones located within tendons. Everyone has at least two sesamoid bones, the patellas (kneecaps).

Every bone contains both compact and cancellous osseous tissue. The compact tissue provides strength and support. The cancellous tissue makes the bone light weight without sacrificing strength. Cancellous bone also provides a site for blood cell production. The substance in the cavities of cancellous bone is called **red marrow** because of its red color.

To further reduce the weight of the skeleton, long bones contain a central cavity, the **medullary cavity**. The cavity serves as a storage site for adipose tissue (**yellow marrow**). Lining the medullary cavity is the **endosteum** (*endo* = Gr. inside).

The proximal and distal ends of long bones are termed the **epiphyses** (sing. - epiphysis). The epiphyses are covered with **articular cartilage** (*arthros* = Gr. joint). The term "articular" refers to its function (physiology). Anatomically this tissue is hyaline cartilage. The shaft of the bone is the **diaphysis**. Between the diaphysis and the epiphyses can be seen the **epiphyseal lines**, which are the remnants of the growth zones from childhood.

A break in a bone is called a **fracture**. Several terms are used to describe fractures and the procedures used to correct them. If the skin is broken open, the fracture is termed a **compound** or **open fracture**. If the skin remains intact, it is

a **simple** or **closed** fracture. The procedure used to repair a fracture by manipulation is **closed reduction**. If surgery is required to restore the bone, then the process is termed **open reduction**.

A **greenstick** fracture is one in which the bone is broken only on one side. Another type of incomplete fracture is the **fissured** fracture in which the bone is partially split linearly.

Complete fractures can be **transverse**, **oblique**, or **spiral**. If a piece of bone is broken out of the diaphysis, the fracture is **segmental**. If many pieces are broken out then the fracture is **comminuted**. When one bone is jammed into another the fracture is **compacted**.

Exercise 8.1

Using your textbook as a guide, label the figure of the humerus, a representative long bone.

Exercise 8.2

Label the bones and regions of the skeleton shown in Figure 8.2.

Exercise 8.3

Using your textbook as a guide, label the fractures shown in Figure 8.3.

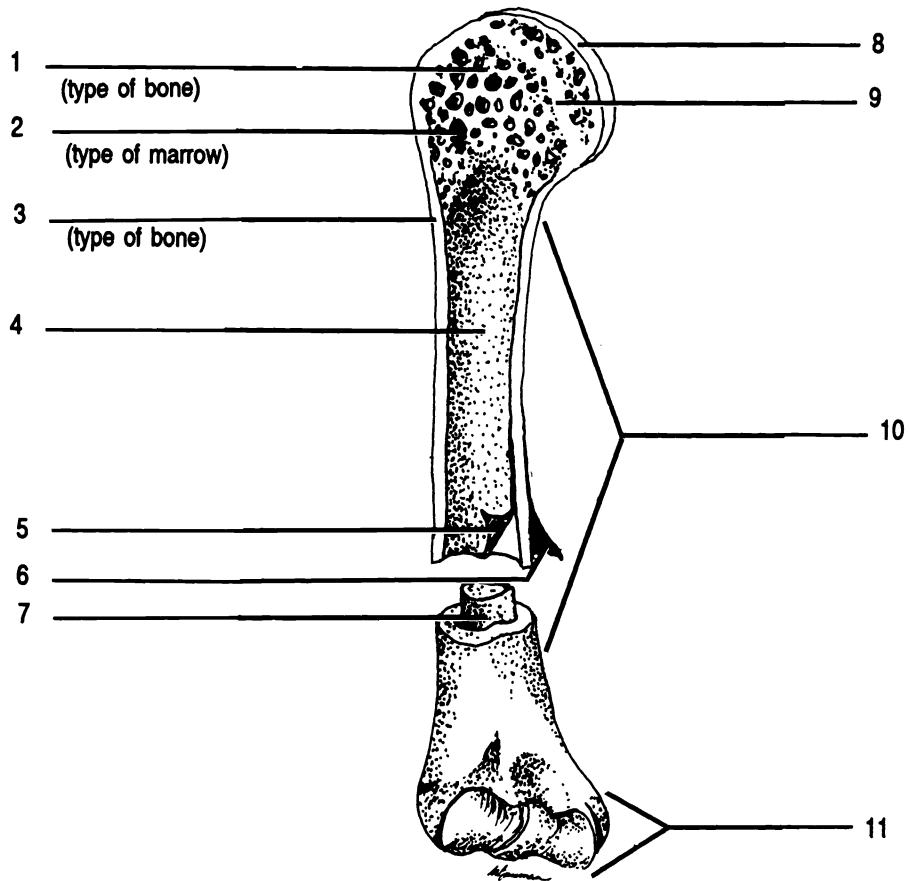


Figure 8.1 Humerus, A Long Bone

Articular cartilage Cancellous bone Compact bone Diaphysis Endosteum Epiphysis Medullary cavity Metaphysis
 Periosteum Red marrow Yellow marrow

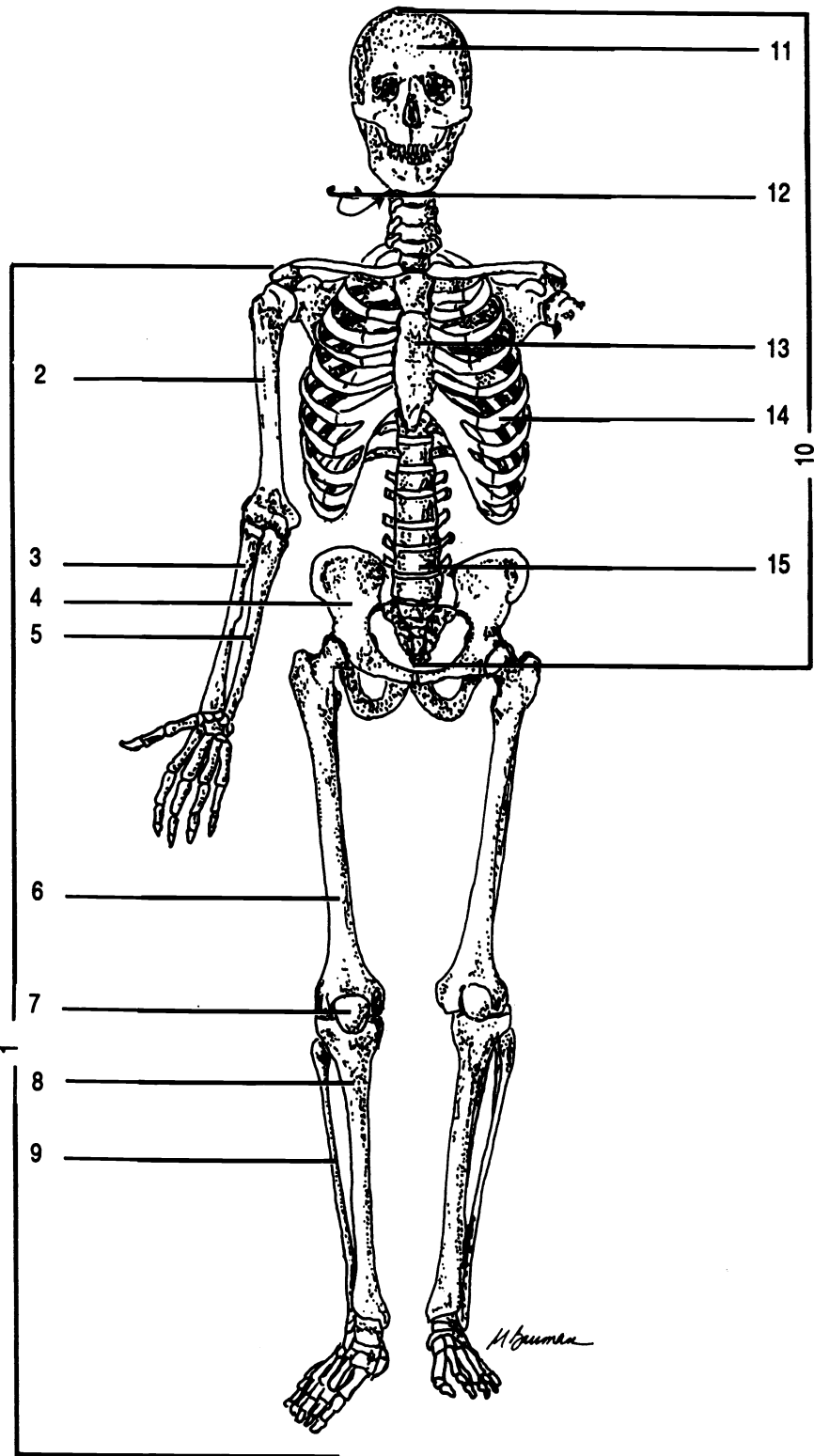


Figure 8.2 Skeletal System

Appendicular skeleton Axial skeleton Femur Fibula Humerus Hyoid Os coxa Patella Radius Rib Skull
 Sternum Tibia Ulna Vertebral column

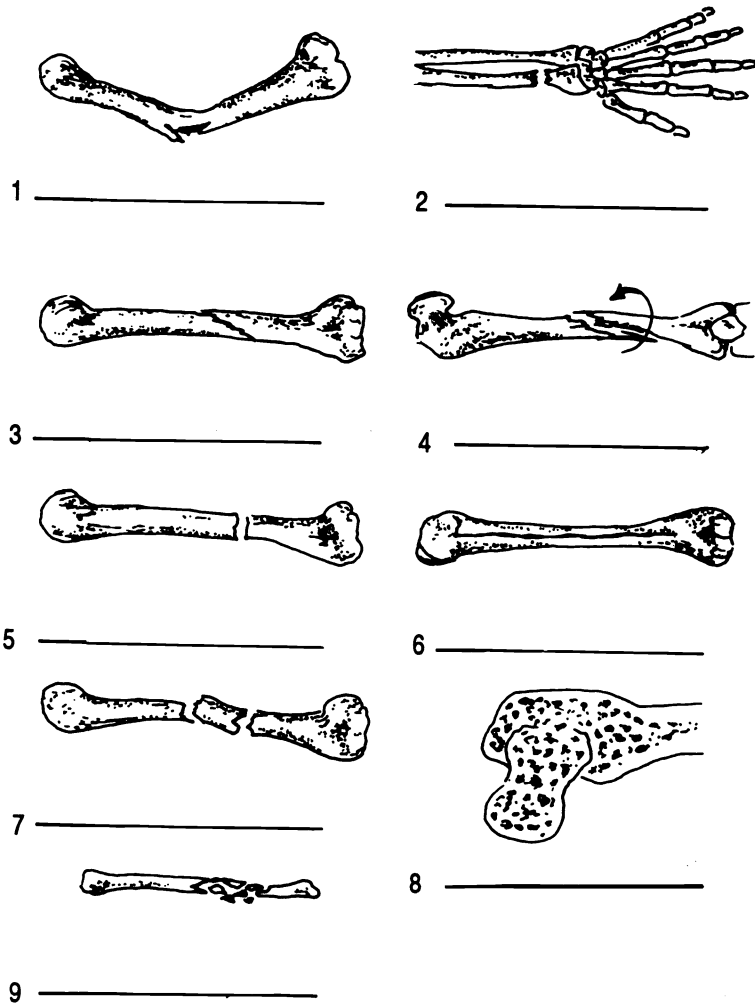


Figure 8.3 Bone Fractures

Colles' Comminuted Compacted (impacted) Fissured Greenstick Oblique Segmental Spiral Transverse

The surfaces of bones have various structural features called bone markings for specific functions. Using your textbook as a guide, fill in this chart on the bone markings.

MARKINGS

DESCRIPTIONS

DEPRESSIONS AND OPENINGS

Cleftlike opening

Round opening

Tubelike passage

Air-filled cavity

Depression for vessel or nerve

Fossa

PROCESSES = ANY PROMINENT PROJECTION FOR A JOINT OR TO ATTACH MUSCLES, TENDONS, OR LIGAMENTS

Condyle

Projection above a condyle

Rounded projection on a thin neck

Flat surface on ribs and vertebrae

Tubercle

Tuberosity

Large, blunt process on femur

Prominent border or ridge

Line

Spine (spinous process)

CHAPTER 8 REVIEW

1. _____ The sternum (breastbone) lies on the midsagittal plane of the body. Therefore this bone is part of the (axial/appendicular) skeleton.
2. _____ The carpals (bones of the wrist) have about the same length as width; therefore, they are (long/short irregular).
3. _____ Bones which lie in the sutures of the skull are (3) bones.
4. _____ The shaft of a long bone is the (4).
5. _____ The end of a long bone is the (5).
6. _____ The central cavity of a long bone is the (6).
7. _____ Which kind of marrow is found in the central cavity?
8. _____ Would you look in a diaphysis or an epiphysis to find cancellous tissue?
9. One student says that the cartilage at the end of a long bone is articular cartilage. Her fellow student says, "No, it is hyaline cartilage." Who is correct? Explain your answer.

THE AXIAL SKELETON

PART ONE

THE SKULL

NOTE: IN THE LABORATORY, YOU WILL BE EXAMINING SKULLS WHICH ARE FRAGILE. HANDLE THEM CAREFULLY. DO NOT POINT TO THE SKULLS WITH A PEN OR PENCIL. USE YOUR FINGER OR AN ERASER.

The skull is composed of the eight bones of the cranium and the fourteen bones of the face. With exception of the mandible (lower jaw), these bones are joined together with irregular interlocking joints called **sutures**. In addition to these twenty-two bones, there are three small bones in each ear.

Exercise 9.1

As you read, label the structures in the Figures. After you have located the structure on the drawing, locate it on the skull. If you will proceed with care and diligence, you will be able to learn all of the bones of the cranium and their markings in a relatively short time. Some vocabulary will help you in your investigations. The base of the skull (Figure 9.3) is the inferior, external surface. The floor of the cranium (Figure 9.4) is the inferior, internal surface.

After you have studied each bone, examine it and its markings on the disarticulated skull.

THE CRANIUM

The portion of the skull which encloses the brain is the cranium. There are eight cranial bones: frontal, two parietals, occipital, two temporals, ethmoid, and sphenoid. They are all held together with sutures.

The **frontal** bone forms the anterior portion of the cranium, including the ridges above the eyebrows, and the superior portion of the **orbit** or eye socket. The **supraorbital foramina** can be seen above the orbits.

The frontal is attached to the two **parietals** at the **coronal suture** (*corona* = L. crown). Examine the parietals carefully and you will see the two faint **temporal lines** which form an arch on each side of the skull. They serve as a point of attachment for the temporal muscles.

Note the depressions for blood vessels on the interior surface of the parietals. These depressions are **sulci** (*sing.* - *sulcus*). The two parietal bones are held together by the **sagittal suture**.

The posterior, inferior portion of the cranium is the **occipital** bone. The occipital is joined to both of the parietals by the **lambdoidal suture**. The large hole in the occipital is the **foramen magnum**. The spinal cord exits the brain there. On either side of the foramen magnum, on the inferior surface, are the two **occipital condyles** which form a joint with the vertebral column. "Under" (actually superior to) the occipital condyles are the **hypoglossal canals**.

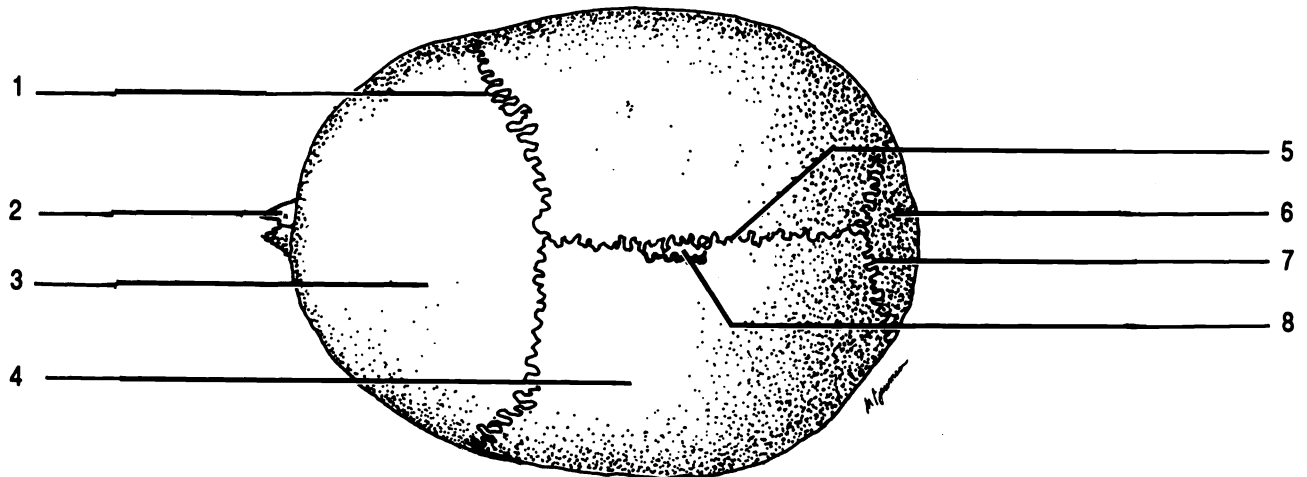


Figure 9.1 Superior View of the Skull

Coronal suture Frontal Lambdoidal suture Nasal Occipital Parietal Sagittal suture Sutural bone

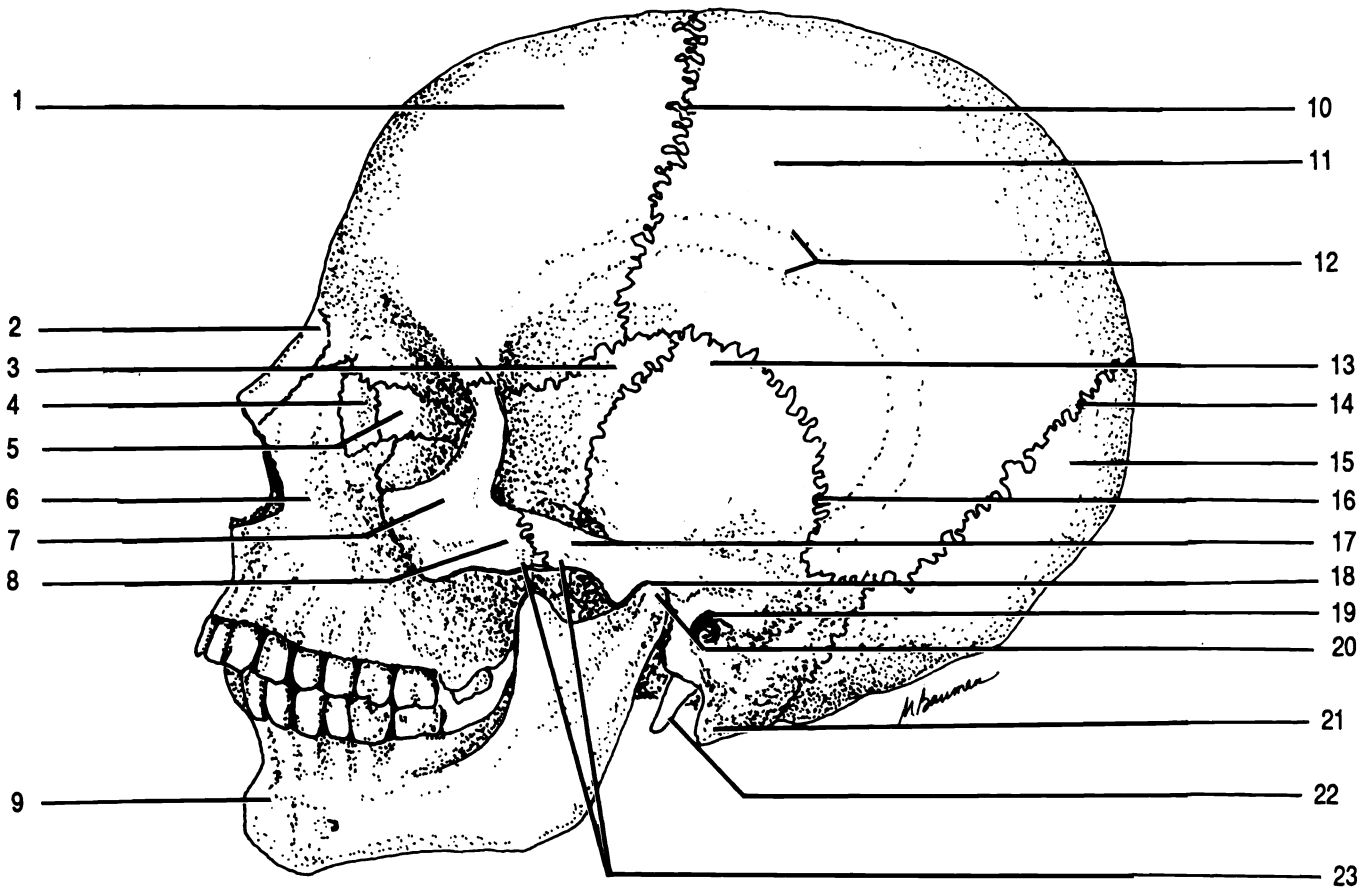


Figure 9.2 Skull, Lateral View

Coronal suture Ethmoid External auditory meatus Frontal Lacrimal Lambdoidal suture Mandible Mandibular condyle Mandibular fossa Mastoid process Maxilla Nasal Occipital Parietal Sphenoid Styloid process Squamosal suture Temporal Temporal lines Temporal process of zygomatic Zygomatic Zygomatic arch Zygomatic process of temporal

On each side of the skull there is a **temporal bone**. The temporal bones are joined to the parietals at the **squamosal sutures**. The flattened portions of the temporal bones are called the **squamosal portions**.

The temporal bone has many important bone markings. Projecting inferiorly is the slender, pointed **styloid process**. Unfortunately, this feature has been broken off most of the laboratory skulls. Find the styloid process on the drawing and where it was on the skull. The larger, blunt **mastoid process** is located lateral and posterior to the styloid process.

Superior to these two processes is the **external auditory meatus**. As the name suggests, this canal contains the internal organs of hearing. The external ear is attached at this point on the temporal bone.

On the interior sloping surface of the temporal bone, you can see the **internal auditory meatus** which contains the nerves of hearing and equilibrium. The **petrous portion** of the temporal bone is the thickened, triangular portion through which the auditory canals run. Within the petrous process are the organs of hearing and equilibrium including the three smallest bones of the body, the **malleus, incus, and stapes**. These bones play a vital role in hearing. Details of their function, as well as of the anatomy of the rest of the inner ear, will be dealt with in chapter twenty-five.

Between the petrous portion of the temporal bone and the occipital bone, inferior and posterior to the internal auditory meatus, you can see the large **jugular foramen** which holds the jugular vein. Find and label both internal and external openings of the jugular foramen. **DO NOT PUT THE POINT OF A PENCIL OR PEN NEAR THE SKULL! DO NOT ATTEMPT TO PUT ANYTHING THROUGH THE FORAMINA OF THE SKULL!**

Once you have located the external openings of the jugular foramina, you can easily see the external openings of the **carotid canals** immediately anterior to the exterior openings of the jugular foramina. The carotid canals are directed medially to their internal openings. These internal openings are not easily visible on the floor of the cranium. They are located along with some other foramina at the medial point of the petrous portions. We will learn the other foramina in this group later.

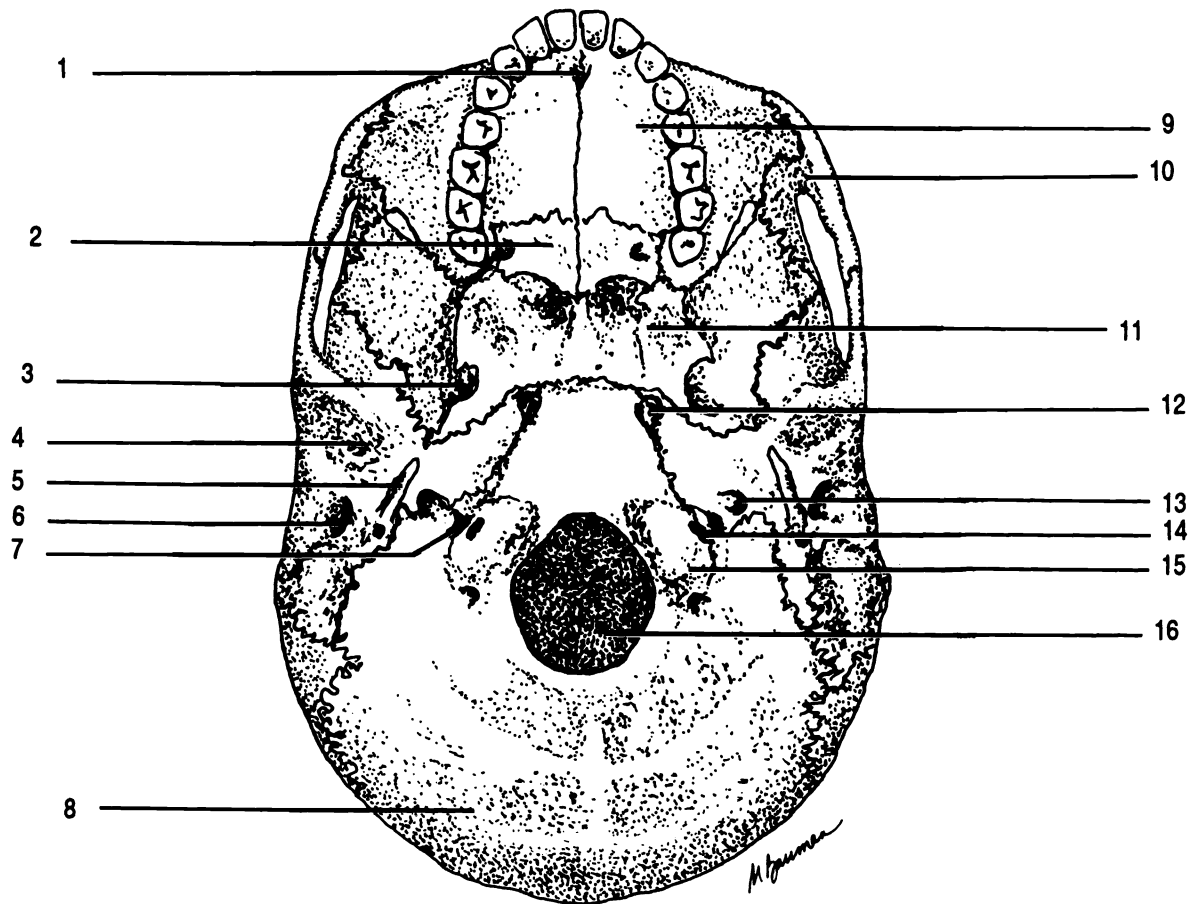


Figure 9.3 Base of the Skull

Carotid canal External auditory meatus Foramen lacerum Foramen magnum Foramen ovale Hypoglossal canal
 Incisive foramen Jugular foramen Maxilla Occipital Occipital condyle Palatine Sphenoid Styloid process
 Temporal Zygomatic

Once again, examine the external surface of the temporal bone. Anterior to the external auditory meatus is a depression, the **mandibular fossa**, which articulates with the mandible. The long anteriorly projected process which articulates with the cheekbone (zygomatic bone) is the **zygomatic process of the temporal bone**. This process is part of the **zygomatic arch**. Can you locate the suture between the zygomatic process of the temporal bone and the temporal process of the zygomatic bone?

Medial to the zygomatic arch is the **sphenoid bone**. This portion of the sphenoid bone is called the **greater wing of the sphenoid**. The rest of the sphenoid bone can be seen on the floor of the cranium.

The depression in the center of the superior surface of the sphenoid is the **hypophyseal fossa**. The pituitary gland (hypophysis) is located here. Note that the hypophyseal fossa is part of a ridge of bone that looks somewhat like a saddle with the fossa being the seat. This ridge of bone is the **sella turcica** (L. Turkish saddle). The two points of bone on the back of the saddle are the **posterior clinoid processes**. Anterior to the sella turcica are the two **optic foramina** which contain the optic nerves from the eyes. Lateral and posterior to the optic foramina are the **anterior clinoid processes**.

The sphenoid contains a number of other important markings. Lateral to each posterior clinoid process is the **foramen lacerum**. The internal opening of the carotid canal joins the internal opening of the foramen lacerum (see discussion of temporal bone). Lateral to the foramen lacerum are the **foramen ovale** and the **foramen spinosum**. The foramen ovale is larger, oval-shaped, and anterior.

The final bone of the cranium is the **ethmoid**. It can be seen projecting into the floor of the cranium through the frontal bone. The ridge of bone in the center is the **crista galli** (L. cock's comb). On either side of the crista galli is the **cribriform plate** which has numerous holes for the olfactory nerves from the nasal cavity. Projecting from the inferior surface of the ethmoid is the **perpendicular plate** which forms the upper part of the nasal septum.

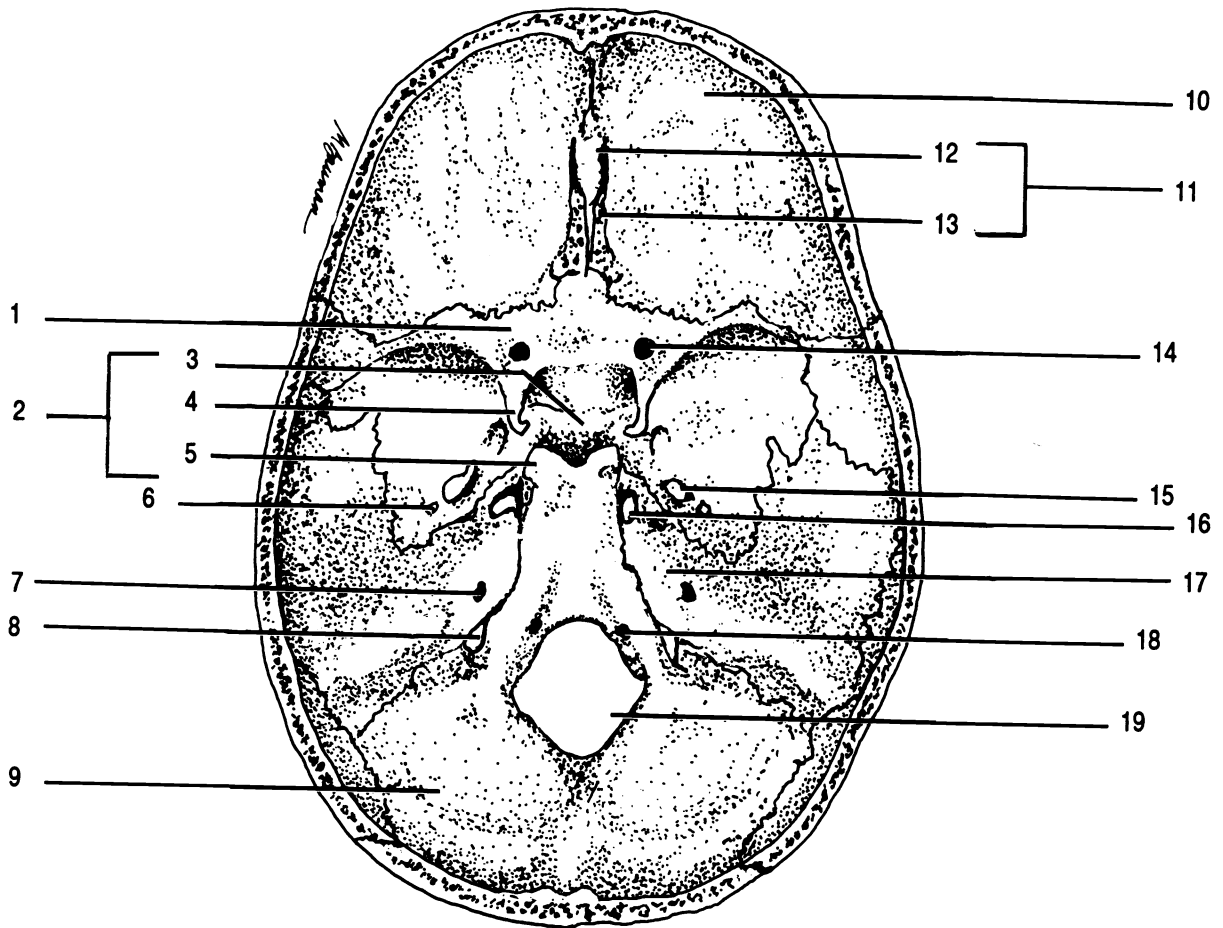


Figure 9.4 Floor of the Cranium

Anterior clinoid process Cribriform plate Crista galli Ethmoid Foramen lacerum Foramen magnum Foramen ovale
 Foramen spinosum Frontal Hypoglossal canal Hypophyseal fossa Internal auditory meatus Jugular foramen
 Occipital Optic foramen Petrous portion of temporal Posterior clinoid process Sella turcica Sphenoid

FACIAL BONES

The rest of the skull is composed of the fourteen facial bones. These are the two nasal, the two lacrimal, the two maxillae, the two zygomatic, the vomer, the two inferior nasal conchae, the two palatine, and the only movable bone of the skull, the mandible. One way to learn these bones is to consider how they form the nose and orbits of the eyes.

The **nasal** bones make up the bridge of the nose. They are best seen in a frontal view of the skull.

Lateral to the nasal are processes extending upwards from the **maxillae** (sing. - maxilla). The maxillae form the upper jaw and a portion of the inferior surfaces of the orbits. They have sockets called **alveoli** for the teeth. The bony projections which form the alveoli are called **alveolar processes**.

The **palatine processes** of the maxillae form the anterior hard palate or roof of the mouth. The **incisive foramen** can be seen on the base of the skull in the suture between the two palatine processes.

Between the maxillae and the temporal bones, forming the lateral walls of the orbits, are the two **zygomatic** bones. The zygomatic bones also form the remainder of the inferior surfaces of the orbits as well as the prominent ridges of the cheeks. You have already noted the **temporal process of the zygomatic** which joins with the zygomatic process of the temporal to form the zygomatic arch.

Lateral to the nasal and maxillae bones within the orbits of the eyes can be seen the small **lacrimal** (*lacrima* = L. tear) bones.

The remainder of the orbits is composed of a portion of the ethmoid lateral to each lacrimal, the sphenoid on the posterior surface, and the frontal forming the superior surfaces. Note that though there are two orbits there is only one ethmoid, one sphenoid, and one frontal. These three bones form part of each orbit. The two fissures seen in each orbit are the **superior orbital fissure** and the **inferior orbital fissure**.

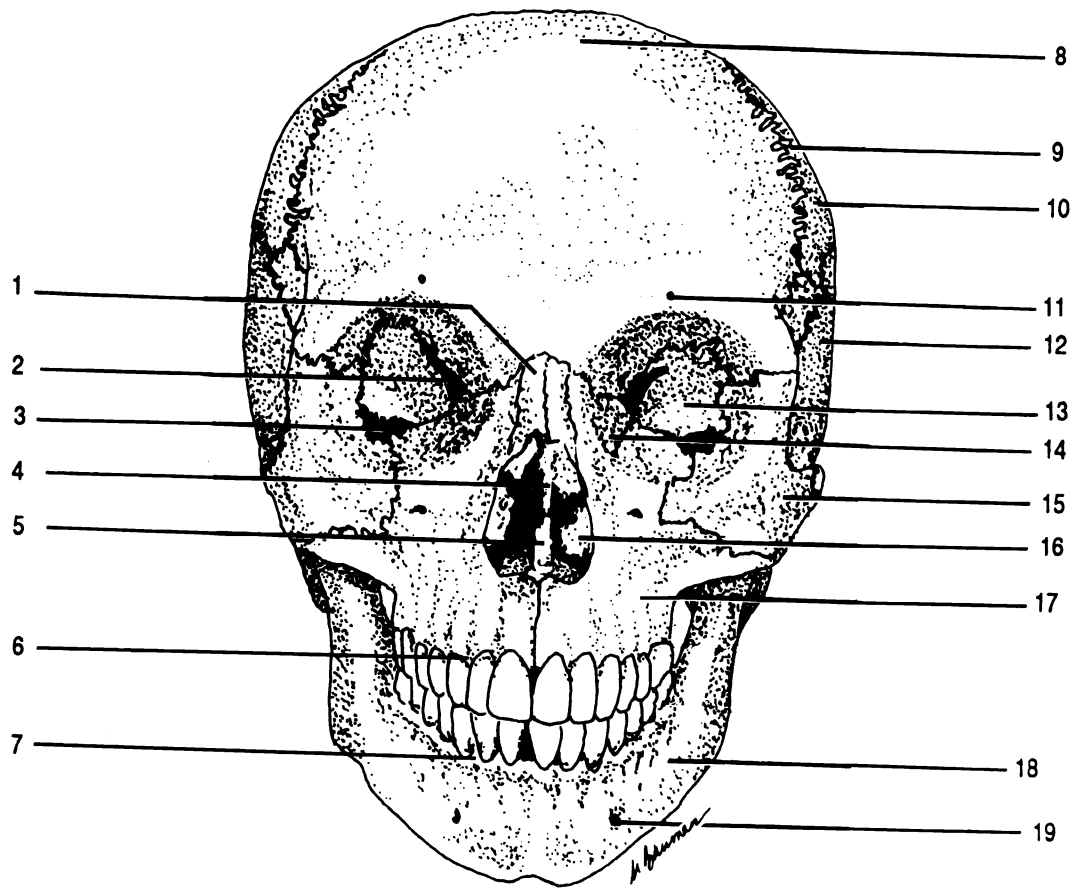


Figure 9.5 Skull, Frontal View

Alveolar process of maxilla Alveolar process of mandible Coronal suture Frontal Inferior nasal concha Inferior orbital fissure Lacrimal Mandible Maxilla Mental foramen Nasal Parietal Perpendicular plate of ethmoid Sphenoid Superior orbital fissure Supraorbital foramen Temporal Vomer Zygomatic

The nasal cavity contains the **vomer** and the two **inferior nasal conchae**. The vomer lies on the midline of the nasal cavity and forms the inferior portion of the nasal septum. The inferior nasal conchae are situated to form part of the lateral walls of the nasal cavity.

Typically, these three fragile bones are broken in the laboratory skulls, though you should be able to find at least a portion of each of them.

The two **palatine** bones can be seen on the inferior surface of the skull. They form the posterior portion of the hard palate. The anterior hard palate is formed by the palatine processes of the maxillae.

The final facial bone is the **mandible**. This is the only movable bone of the skull and the only skull bone which is not joined by a suture. The mandible forms a joint with the temporal bones at the mandibular fossae. The processes of the mandible which join the temporals are the **mandibular condyles**. The vertical parts of the mandible are the **rami** (sing. - ramus). The horizontal portion is the **body**. The rami and the body are joined at the **angles of the mandible**. The body has alveolar processes to hold the inferior teeth. On either side of the chin can be seen the **mental foramina** (*mentum* = L. chin). The notch at the top of each ramus is a **mandibular notch**. On the medial surface of each ramus is a **mandibular foramen** where the nerve enters to innervate the teeth.

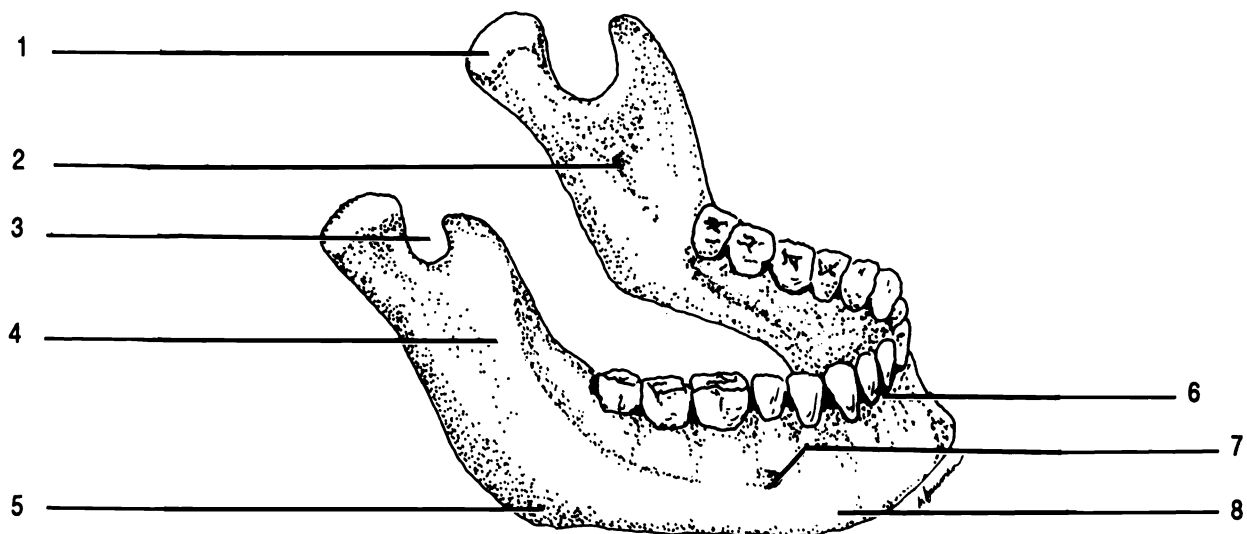


Figure 9.6 Mandible

Alveolus Angle of mandible Body Mandibular condyle Mandibular foramen Mandibular notch Mental foramen
Ramus

SUTURAL BONES

In some individuals there are small bones located within the sutures called **sutural bones**. These are not present in all skulls.

Exercise 9.2

Examine the laboratory skull for sutural bones.

PARANASAL SINUSES

Five bones of the skull, the frontal, ethmoid, sphenoid, and two maxillae, contain **paranasal sinuses** which are paired cavities lined with mucous membranes and connected to the nasal cavity. These cavities lighten the bones of the skull and serve to provide resonance when we speak or sing.

Exercise 9.3

Locate the paranasal sinuses in the bones of the disarticulated skull. You will not be able to see the frontal sinuses. Label the sinuses on Figure 9.7.

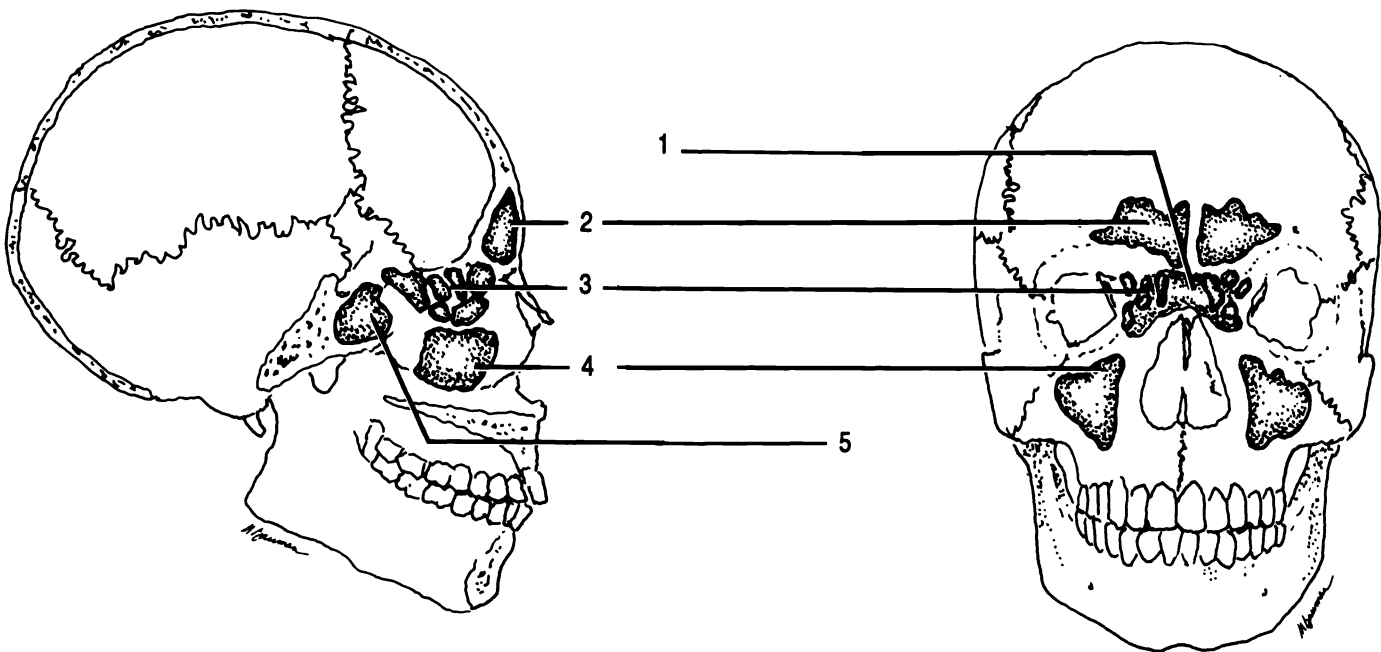
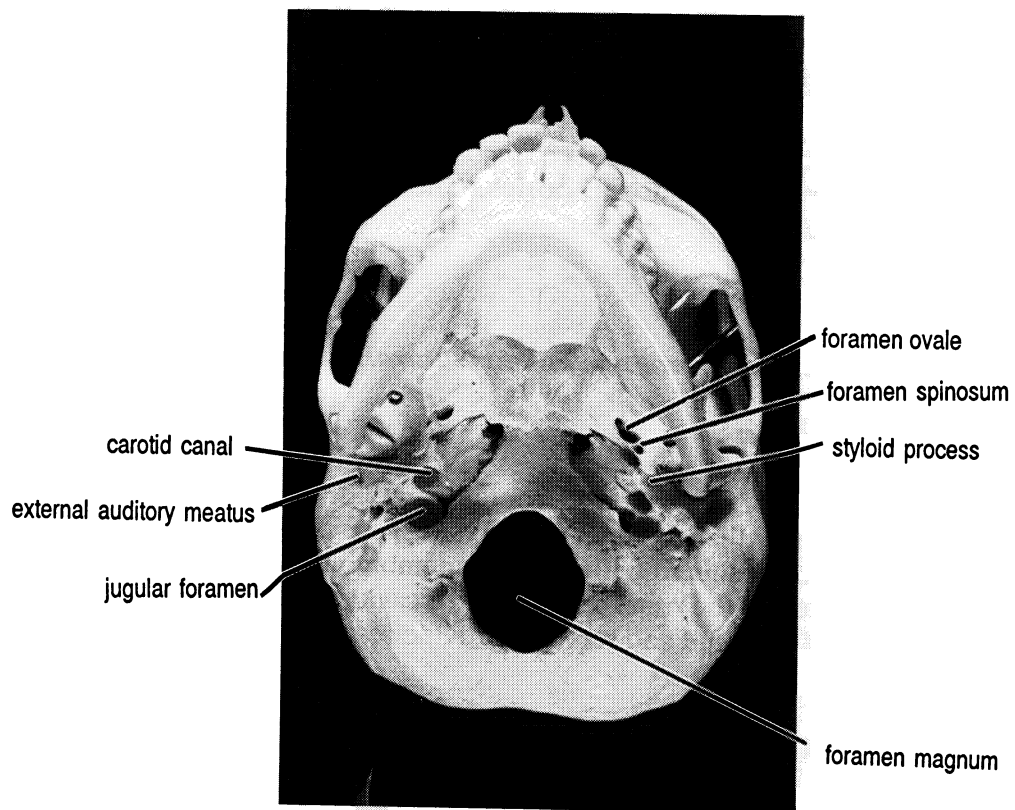
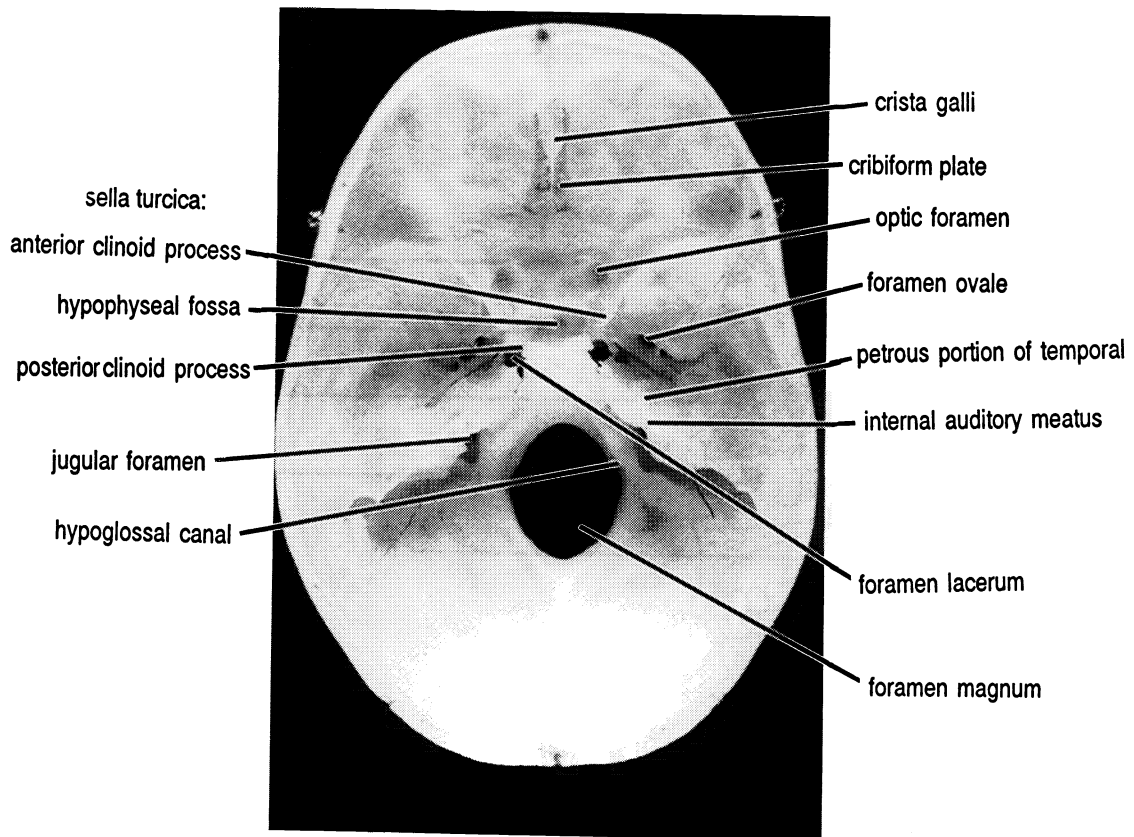


Figure 9.7 Sinuses

Ethmoidal air cells (sinuses) Frontal sinus Maxillary sinus Sphenoidal sinus (X2)



Base of Skull



Floor of cranium

THE FETAL SKULL

The human skull is not completely composed of bone at birth, but still contains a significant amount of fibrous membrane. This dense connective tissue forms "soft spots" called fontanel in the skull of the baby. The largest of these spots is the **anterior fontanel**. Note that the frontal bone begins in the fetus as two bones, but ossification (replacement of cartilage by osseous tissue) causes the two halves to fuse to form the frontal bone. The **posterior fontanel** is the smaller fontanel located at the lambdoidal suture. The sagittal suture connects the posterior and anterior fontanel. There are two smaller fontanel on each side of the skulls, making a total of six fontanel.

Exercise 9.4

Carefully examine the fontanel on the laboratory fetal skull. DO NOT PUSH ON THE FONTANELS! THEY ARE NO LONGER SOFT! Label the fontanel on Figure 9.8.

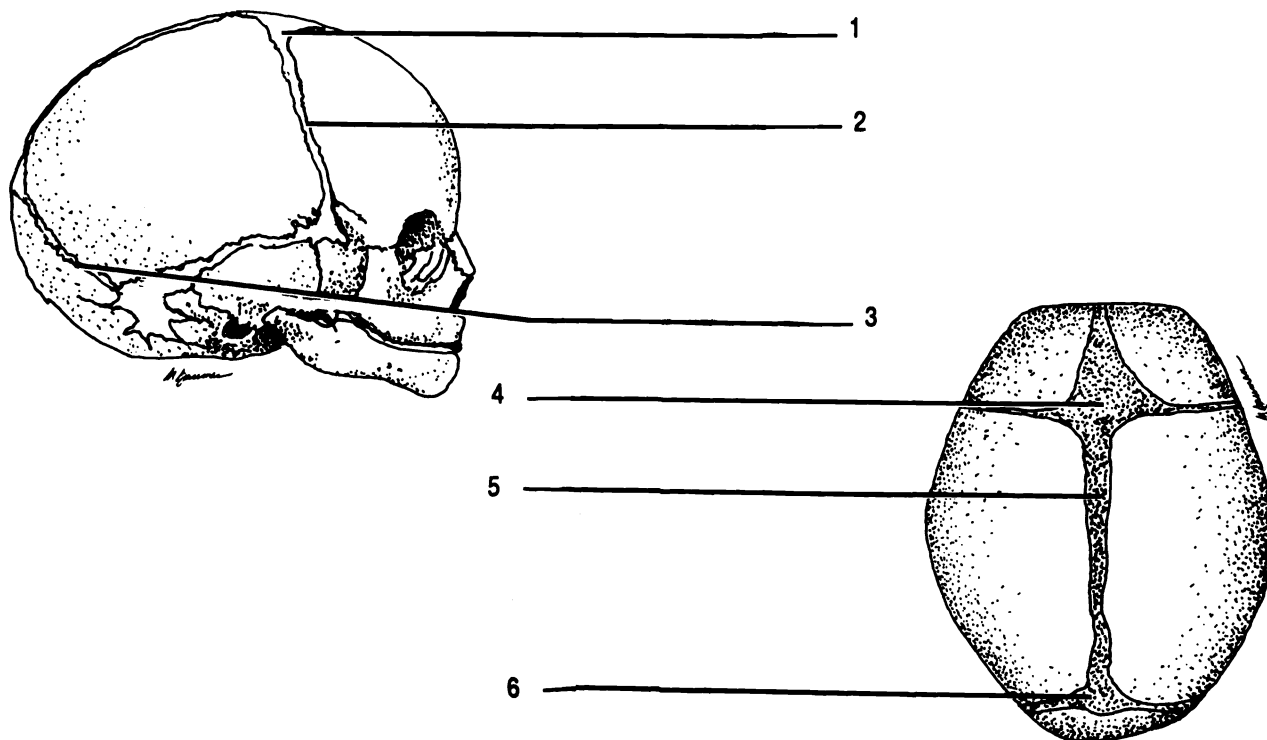


Figure 9.8 Fetal Skull

Anterior fontanel (X2) Coronal suture Lambdoidal suture Posterior fontanel Sagittal suture

CHAPTER 9 REVIEW

List the bones of the cranium in alphabetical order.

1. _____

2. _____

3. _____

4. _____

5. _____

6. _____

7. _____

8. _____

List the bones of the face in alphabetical order.

1. _____

2. _____

3. _____

4. _____

5. _____

6. _____

7. _____

8. _____

9. _____

10. _____

11. _____

12. _____

13. _____

14. _____

1. _____ Which bone of the skull does not articulate at a suture?
2. _____ Bones which surround the brain are called (2) bones.
3. _____ Which bones articulate at the lamboidal suture?
4. _____
5. _____ Which bones join at the sagittal suture?
6. _____ Name the largest foramen in the skull.
7. _____ Small bones found within sutures are (7) bones.
8. _____ The inferior portion of the lateral walls of the nasal cavity are formed by the (8) bones.
9. _____ The pituitary gland rests in which bone?
10. _____ What portion of the occipital bone articulates with the vertebral column?
11. _____ What two processes make up the zygomatic arch?
12. _____
13. _____ Which bones articulate with the mandible?
14. _____ Which foramina provides access for a nerve to travel to the roots of the teeth in the mandible?
15. _____ What is a vertical portion of the mandible?
16. _____ The sockets for the teeth are the (16).

THE AXIAL SKELETON PART TWO

VERTEBRAL COLUMN

RIB CAGE

HYOID

The axial skeleton consists of the skull, the vertebral column, the ribs and sternum which compose the rib cage, and the hyoid bone. All of these bones lie on the vertical axis of the body.

THE VERTEBRAL COLUMN

Exercise 10.1

As you read, label Figure 10.1 and identify each part on the vertebrae available in the laboratory.

The **vertebral column** is composed of bones called **vertebrae** (**sing. - vertebra**) stacked on top of each other and resting on the hip bones. In general, vertebrae have certain distinct parts. The hole in the center of the vertebra is the **vertebral foramen**. All of the vertebral foramina together make up the **vertebral canal** which contains the spinal cord.

The vertebral foramen is surrounded by five bony processes. The large round process is the **body**. Extending posteriorly from the body are two **pedicles**. The spaces between the pedicles of adjacent vertebrae allow spinal nerves to exit the vertebral canal. These spaces can only be seen from the side and are called the **intervertebral foramina**. Unlike other foramina we have observed,

these foramina are not holes in a bone, but rather exist between two vertebrae.

The final two processes which complete the structure around the vertebral foramen are the **laminae (sing. - lamina)** which are posterior extensions of the pedicles. The semicircle formed by the laminae and the pedicles is called the **neural arch**.

Extending laterally from the pedicles are the **transverse processes**. Extending posteriorly from the neural arch is the **spinous process**.

The vertebrae articulate (*arthros* = Gr. joint) with one another at their bodies and at special processes on the neural arch termed **articular facets**. The **intervertebral disk**, composed of fibrocartilage, lies between the body of one vertebra and the body of the next. There are two types of articular facets located on the pedicles: superior articular facets and inferior articular facets. The superior articular facets of a vertebra join to the inferior articular facets of the vertebra superior to it.

Vertebrae from each region of the vertebral column differ from the generalized vertebra presented here.

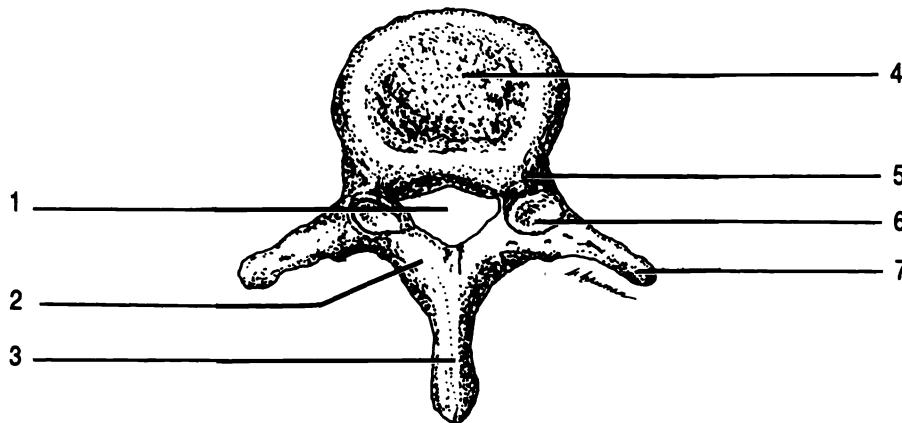


Figure 10.1 Generalized vertebra

Body Lamina Pedicle Transverse process Spinous process Superior articular facet Vertebral foramen

Exercise 10.2

Label Figure 10.2 and identify all of the features on the laboratory vertebral column as you read.

The vertebral column has four distinct areas when viewed from the side. These four areas are manifested as curves of the column.

The upper curve is anteriorly convex, is located in the neck, and is known as the **cervical curve**. The seven vertebrae in this region are known as the cervical vertebrae. They are named cervical one, cervical two, etc. or abbreviated C1, C2, C3, . . . C7. Cervical vertebrae one through six are characterized by having a **bifid spinous process**, that is, the spinous process has two points on its end. These are not always clearly visible. C7 does not have this feature. All of the cervical vertebrae have **transverse foramina** in the transverse processes. Transverse foramina are unique to the cervical region.

Two of the cervical vertebrae have additional names and special features. The first cervical vertebra is also known as the **atlas**. The atlas has no body. Like the mythical Atlas who held the world on his shoulders, the atlas bone holds the skull. The atlas articulates with the occipital condyles of the occipital bone.

C2, the **axis**, has a superiorly directed process extending from its body. This process, the **odontoid process**, extends up into the atlas and allows the head to rotate from side to side on its axis.

The second curve of the vertebral column is anteriorly concave. This region is the **thoracic curve** as it lies in the chest or thorax. There are twelve thoracic vertebrae. They are numbered one through twelve and have no other special names. These vertebrae are characterized by having an inferiorly directed spinous process and flat processes, the **facets** and **demifacets**, to hold the ribs (see RIBS below).

The **lumbar curve** is inferior to the thoracic curve and is anteriorly convex. There are five lumbar vertebrae characterized by large bodies, blunt, thick spinous processes, medially directed superior articular facets, and laterally directed inferior articular facets.

The last curve of the vertebral column is the **sacral curve**. It is anteriorly concave, and composed of two bones, the **sacrum** and the **coccyx** or tailbone. The sacrum is composed of five vertebrae which fuse together to form one bone during the later teen years. The coccyx is formed from a fusion of four or five vertebrae which have rudimentary bone markings.

RIBS

There are twelve pair of ribs corresponding to the twelve thoracic vertebrae. The ribs join the thoracic vertebrae at the facets and demifacets. The demifacets are half facets found on the bodies of some vertebrae. Two demifacets form a facet when the bodies of the vertebrae are put together. The ribs curve posteriorly away from the bodies, join the facets on the transverse processes, and then curve toward the front of the body. Like the vertebrae the ribs are numbered beginning with the superior pair.

Rib pairs one through seven articulate with the breastbone through a cartilaginous extension of the ribs and are called the **vertebrosternal ribs**. The next three pair of ribs attach to the cartilage of rib pair seven. These three pair of ribs are called the **vertebrochondral ribs**. The last two pair of ribs are not anteriorly attached and so they are termed the **vertebral ribs** or floating ribs.

STERNUM

The breastbone is the **sternum**. It consists of three portions: the upper **manubrium**, the central **body**, and the inferior **xiphoid process**. The xiphoid process is composed of cartilage during childhood, and is not completely ossified until about age 40.

HYOID

The last of the bones of the axial skeleton is the horseshoe shaped **hyoid**. This bone is unique in that it does not articulate with any other bone. It is located inferior to the mandible, and provides a floor of support for the tongue.

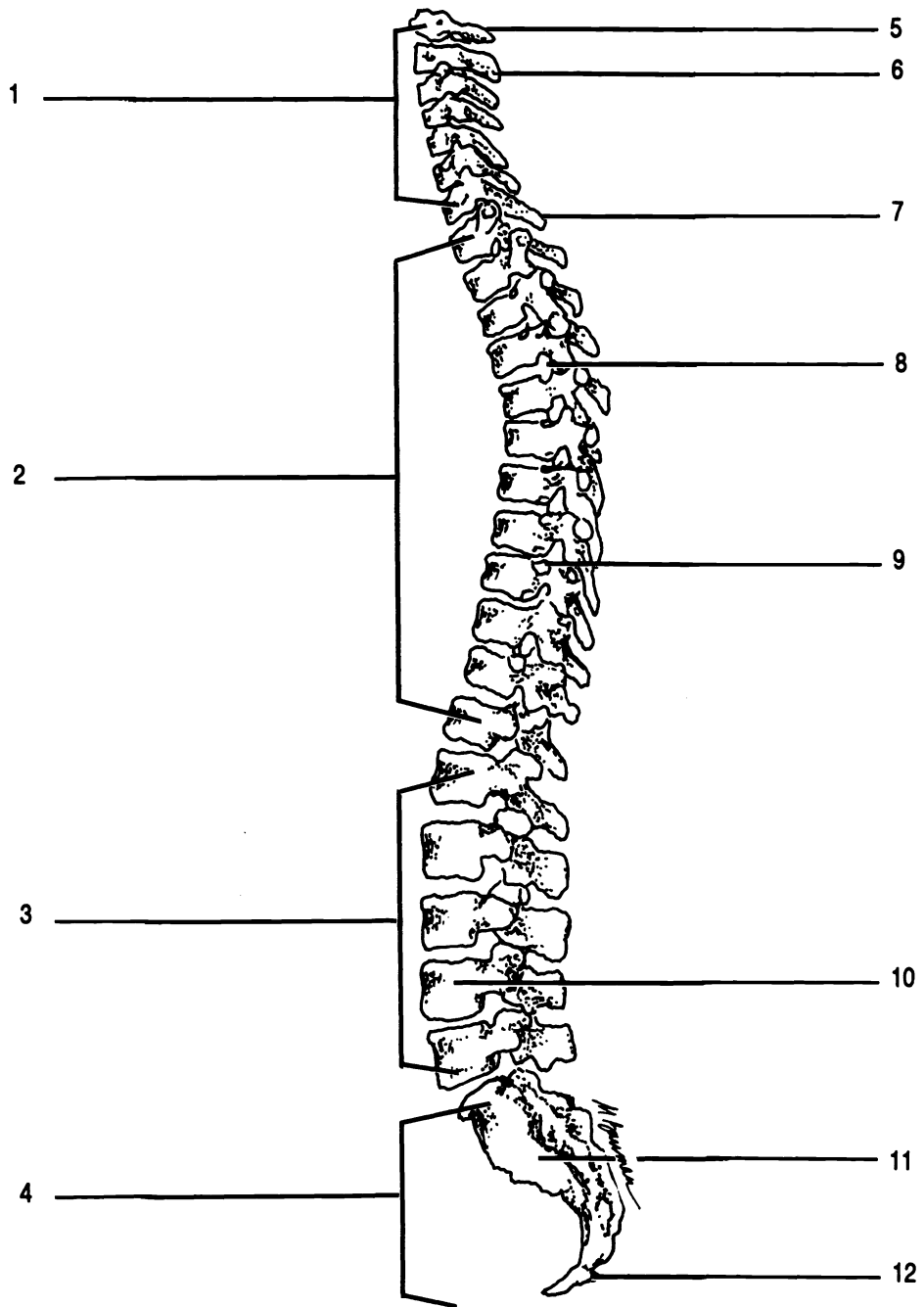


Figure 10.2 Vertebral column

Atlas Axis C7 Cervical curve Coccyx Facet Intervertebral foramen Lumbar curve L4 Sacral curve
 Sacrum Thoracic curve

Exercise 10.3

Label Figure 10.3, comparing the figure to the laboratory specimens. Take careful note of the attachments of the ribs to the thoracic vertebrae and the sternum. Locate the hyoid on the full skeleton and on Figure 8.2.

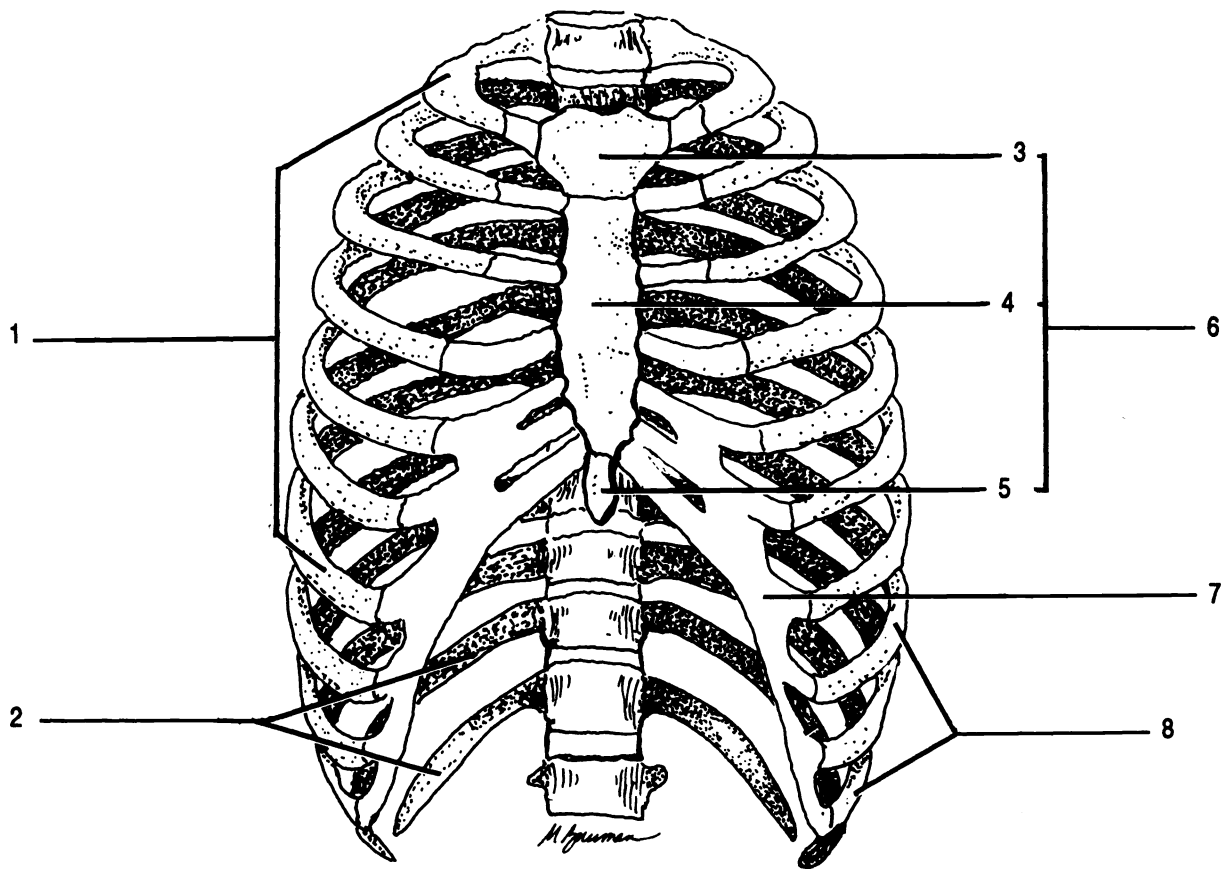


Figure 10.3 Rib Cage

Body Cartilage Manubrium Sternum Vertebral ribs Vertebrosteral ribs Vertebrochondral ribs Xiphoid process

CHAPTER 10 REVIEW

1. _____ Name the regions of the vertebra column in order, superior to inferior.
2. _____
3. _____
4. _____
5. _____ Which foramen is a hole between vertebrae?
6. _____ The vertebrae join each other at their bodies and (6).
7. _____ The vertebra which articulates with the head is the (7).
8. _____ The first vertebra is C1, also known as the (8).
9. _____ Which vertebra allows rotation of the head?
10. _____ What is the scientific name for the tailbone?
11. _____ The spinal cord is in the (11) canal.
12. _____ C1 through C6 are characterized by a (12) spinous process.
13. _____ Which vertebrae have transverse foramina?
14. _____ Which vertebrae have facets for ribs?
15. _____ How many pair of ribs are there?
16. _____ Which ribs do not articulate anteriorly?
17. _____ Name the three parts of the sternum from superior to inferior.
18. _____
19. _____
20. _____ Which ribs articulate with the sternum?
21. _____ Which bone of the body does not articulate with another bone?

22. _____ Which vertebrae have an inferiorly directed spinous process?
23. _____ Which bone provides a floor of support for the tongue?
24. _____ Which bone articulates with the two os coxae?
25. _____ Which bone is made up of five fused vertebrae?

THE APPENDICULAR SKELETON

The appendicular skeleton consists of the 126 bones of the shoulders, hips, and appendages.

Exercise 11.1

As you read, label Figures 11.1 through 11.5. Find each feature on the laboratory bones.

Determine whether each laboratory bone belongs to the right or left side of the body.

As you study each bone, "build" the skeleton on your lab table.

THE UPPER EXTREMITIES

The two **shoulder girdles** are each composed of two bones, the **scapula** and the **clavicle**. The scapula is a triangular bone with a lateral socket, the **glenoid cavity**, for the humerus of the arm. There are two processes which project above the level of the glenoid cavity. The superior of these processes is the **acromion** (*acros* = Gr. topmost, height). The acromion is an extension of the posterior **spine** and articulates with the clavicle.

The second process, the **coracoid process**, lies superior and anterior to the glenoid cavity. The coracoid process is a site of muscle attachment.

The clavicle, or collarbone, is an S-shaped bone which articulates with the acromion of the scapula and the manubrium of the sternum. The **sternal extremity** is more rounded in shape than the **acromial extremity**. A roughened **conoid tubercle** is located on the inferior, posterior surface of the clavicle.

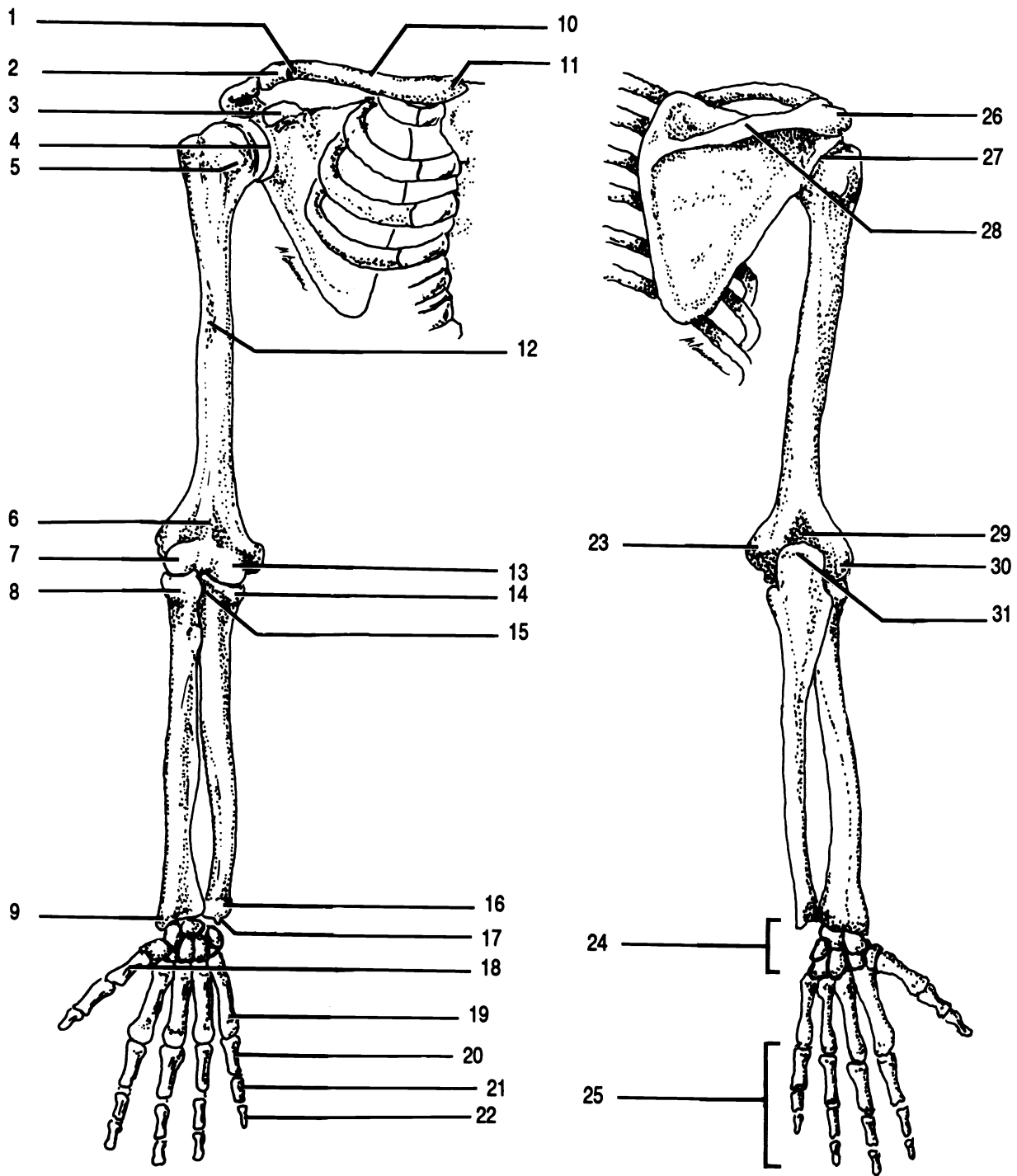


Figure 11.1 Shoulder Girdle and Arm

Acromial extremity Acromion Capitulum Carpus Clavicle Conoid tubercle Coracoid process Coronoid fossa
 Coronoid process Deltoid tuberosity Distal phalanx Glenoid cavity (X2) Head of humerus Head of radius
 Head of ulna Lateral epicondyle Medial epicondyle Metacarpal 1 Metacarpal 5 Middle phalanx Olecranon process
 Olecranon fossa Phalanges Proximal phalanx Radial notch Spine Sternal extremity Styloid process of radius
 Styloid process of ulna Trochlea

The upper arm bone is the **humerus**. (Please note the spelling of this word, it does not contain an “o”!) The **head** of the humerus is a spherical projection which articulates with the glenoid cavity of the scapula. Approximately half way down the anterior surface of the humerus is the **deltoid tuberosity**, the site of attachment of the deltoid muscle.

There are a number of bone markings on the distal end of the humerus. The most prominent of these is the large **olecranon fossa** on the posterior surface of the distal end. On the anterior surface are the medial **trochlea** and the lateral **capitulum**. It will help you to realize that the trochlea has two “bumps” and is on the same side as the head. Just proximal to the trochlea is the **coronoid fossa**. The capitulum has only one rounded “bump”. The final two processes on the distal end of the humerus are the **lateral epicondyle** and the **medial epicondyle**.

The distal bones of the arm are the lateral **radius** and the medial **ulna**. Examine the ulna first.

The proximal end of the ulna has a prominent fossa called the **trochlear notch**. With what structure does this process articulate? _____ The **coronoid process** forms the anterior border of the trochlear notch. Posterior to the trochlear notch is the elbow, known to anatomists as the **olecranon process**. Put the ulna together with the humerus and notice how the olecranon fits into the olecranon fossa and the coronoid process into the coronoid fossa as the ulna hinges around the trochlea. There is a small **radial notch** on the lateral surface of the ulna distal to the trochlear notch. The radius articulates here.

The distal end of the ulna is the **head**. The ulna is the only bone in the body that “stands on its head”. The short, medial projection off the head is the **styloid process of the ulna**.

The radius has fewer markings than the ulna. The proximal end of the radius is the **head** which articulates with the radial notch of the ulna and the capitulum of the humerus. Examine the articulated skeleton to see how the radius rotates around the capitulum. Distal to the head is the **radial tuberosity**, the site of muscle attachments. On the distal end of the radius is the **styloid process of the radius**. Note how the two styloid processes (one on the ulna and the

other on the radius) are arranged to hold the bones of the wrist in place.

There are eight bones of the wrist called **carpals**. Collectively they are known as the **carpus**. They are arranged in two "rows". Examine the anterior surface of the wrist. The carpals of the distal row, from lateral to medial, are the **trapezium**, **trapezoid**, **capitate**, and **hamate**. Returning to the lateral side, the bones of the proximal row are the **pisiform**, **triquetrum** (**triquetral**), **lunate**, and **scaphoid**. You will not be asked to identify the bones of the carpus apart from each other, but you should be able to identify them in an articulated wrist. A mnemonic device which may help you is the phrase "Tiny Tim Could Hardly Pull The Little Sled". Each word begins with the same letter as a carpal beginning with the anterior, distal row, lateral to medial, and then back through the proximal row, medial to lateral. You should be able to name the bones from both the anterior and posterior views.

Distal to the carpals are the five **metacarpals**. These five bones are numbered from lateral to medial, i.e. metacarpal I articulates with the thumb. Note that the metacarpals are the bones of the palm.

Distal to the metacarpals are the fourteen **phalanges** (**sing. - phalanx**). Each finger has three phalanges named proximal phalanx, middle phalanx, and distal phalanx. The thumb has only two phalanges, the proximal and distal.

THE LOWER EXTREMITIES

The pelvic girdle is made of two bones, the **os coxae** (**sing. - os coxa**) or hip bones. Each os coxa is formed from three embryonic bones. These are the large, superior **ilium**, the posterior, inferior **ischium**, and the anterior, inferior **pubis**. The three embryonic bones fuse to form a single os coxa.

The os coxa has several important bone markings. The large fossa in the os coxa is the **acetabulum** which articulates with the femur of the leg. The **obturator foramen** is between the pubis and the ischium. The **sciatic notch** is located on the ilium. The superior ridge of the ilium is the **iliac crest**.

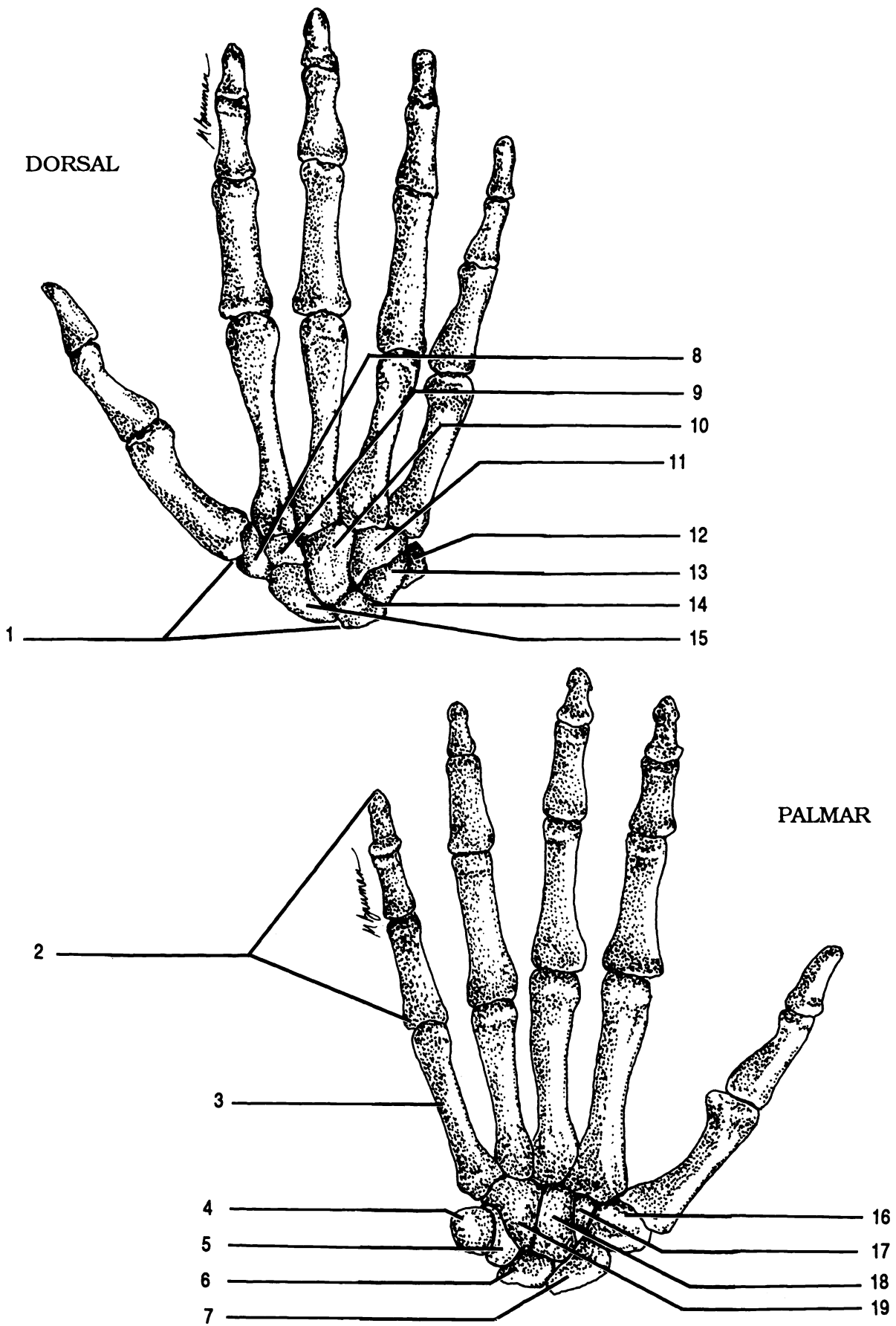


Figure 11.2 Right Hand

Capitate (X2) Carpus Hamate (X2) Lunate (X2) Metacarpal V Phalanges Pisiform (X2) Scaphoid (X2)
 Trapezium (X2) Trapezoid (X2) Triquetrum (X2)

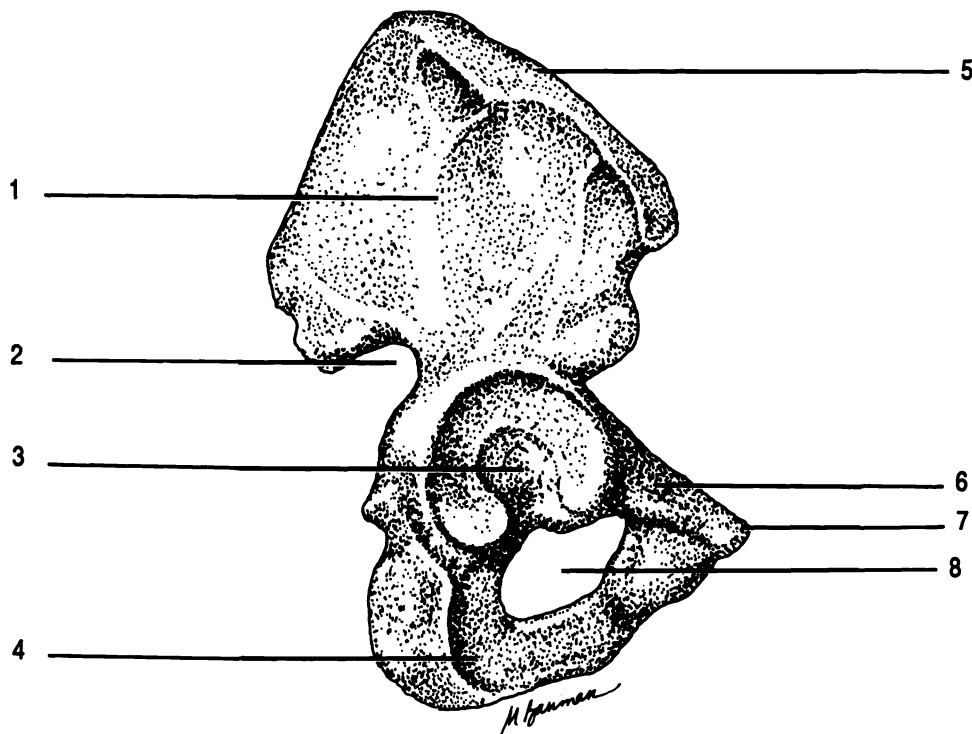


Figure 11.3 Os Coxa, Lateral Aspect

Acetabulum Iliac crest Ilium Ischium Obturator foramen Pubis Symphysis pubis Sciatic notch

The upper leg bone is the **femur**. The head of the femur is a rounded projection which articulates with the acetabulum of the os coxa. Lateral to the head is a large, blunt projection, the **greater trochanter**, which serves as a site for muscle attachment.

At the distal end of the femur are two projections, the **lateral condyle** and the **medial condyle**. Projecting from each condyle is an epicondyle, the **lateral** and **medial epicondyles**.

Articulating with the distal end of the femur is the **tibia**. The tibia has a **lateral condyle** and a **medial condyle** which articulate with the corresponding condyles of the femur. Distal to the condyles of the tibia and on the anterior surface is the **tibial tuberosity**, another site of muscle attachment. At the distal end of the tibia is a prominent, medial projection, the **medial malleolus** which holds the foot in position.

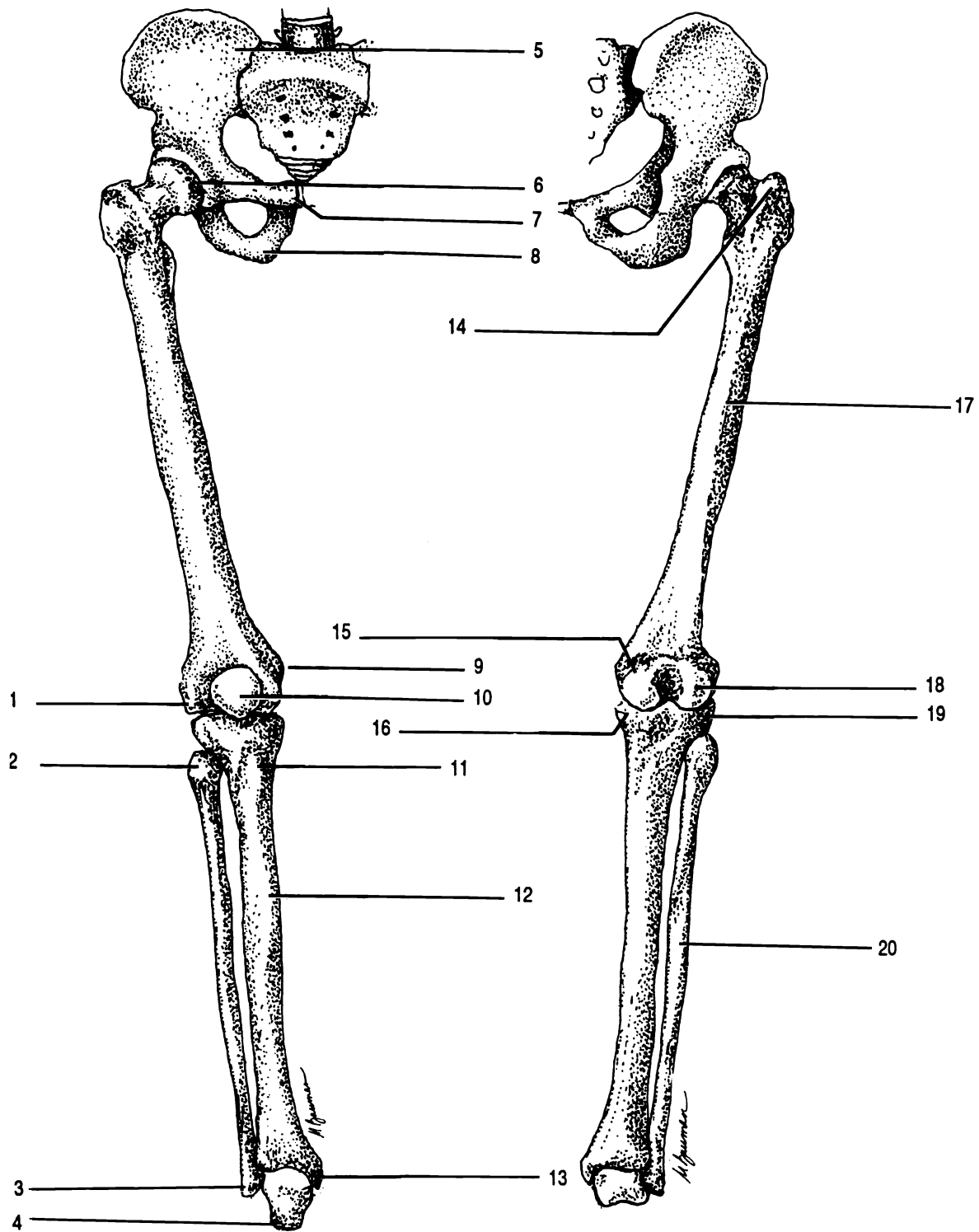


Figure 11.4 Lower Extremities

Femur Fibula Head of femur Head of fibula Greater trochanter Ilium Ischium Lateral condyle of femur
 Lateral condyle of tibia Lateral epicondyle Lateral malleolus Medial condyle of femur Medial condyle of tibia
 Medial epicondyle Medial malleolus Patella Pubis Talus Tibia Tibial tuberosity

Anterior to the joint formed by the femur and the tibia is a sesamoid bone, the **patella**. The knee joint is made of these three bones: femur, tibia, and patella.

The smaller of the lower leg bones is the **fibula**. This bone does not articulate with the femur. Instead, the **head** of the fibula articulates with the tibia, distal to the lateral condyle of the tibia. The distal end of the fibula has a **lateral malleolus** which prevents the bones of the foot from sliding laterally.

There are three groups of bones in the foot: the **tarsus**, the **metatarsus**, and the **phalanges**. There are seven **tarsals** in each tarsus. (Recall that there were eight carpals in the wrist!) The superior tarsal is the **talus**. This is the only bone of the foot which articulates with the tibia and the fibula. The heel bone is the **calcaneus**. Anterior to the talus is the **navicular**. Anterior to the calcaneus is the **cuboid**. The final tarsals are the three **cuneiforms** which are medial to the cuboid and distal to the navicular. The cuneiforms are named first, second, and third from the medial side. A mnemonic phrase to aid in memory of the tarsals is "Charles III Never Climbs Tall Curbs." There are three cuneiforms, a navicular, cuboid, calcaneus, and a talus. The phrase does not deal with the bones in any particular order.

Distal to the tarsals are the five **metatarsals**. The metatarsals are numbered from the big toe, so metatarsal I is medial and metatarsal V is lateral. Note that the metacarpals are numbered from the thumb, so metacarpal I is lateral. This is a difference between the upper and lower extremities.

Attached to the metatarsals are the fourteen **phalanges**. Like the thumb, the big toe has only two phalanges. All other toes have three phalanges: proximal, middle, and distal.

Exercise 11.2

It is interesting to count the number of bones in the hands and feet. There are phalanges in each hand and foot for a total of _____ phalanges. Counting both hands and both feet there are a total of _____ carpals, metacarpals, tarsals, and metatarsals. Thus, the total number of bones in the hands and feet together is _____, more than in the rest of the body put together!

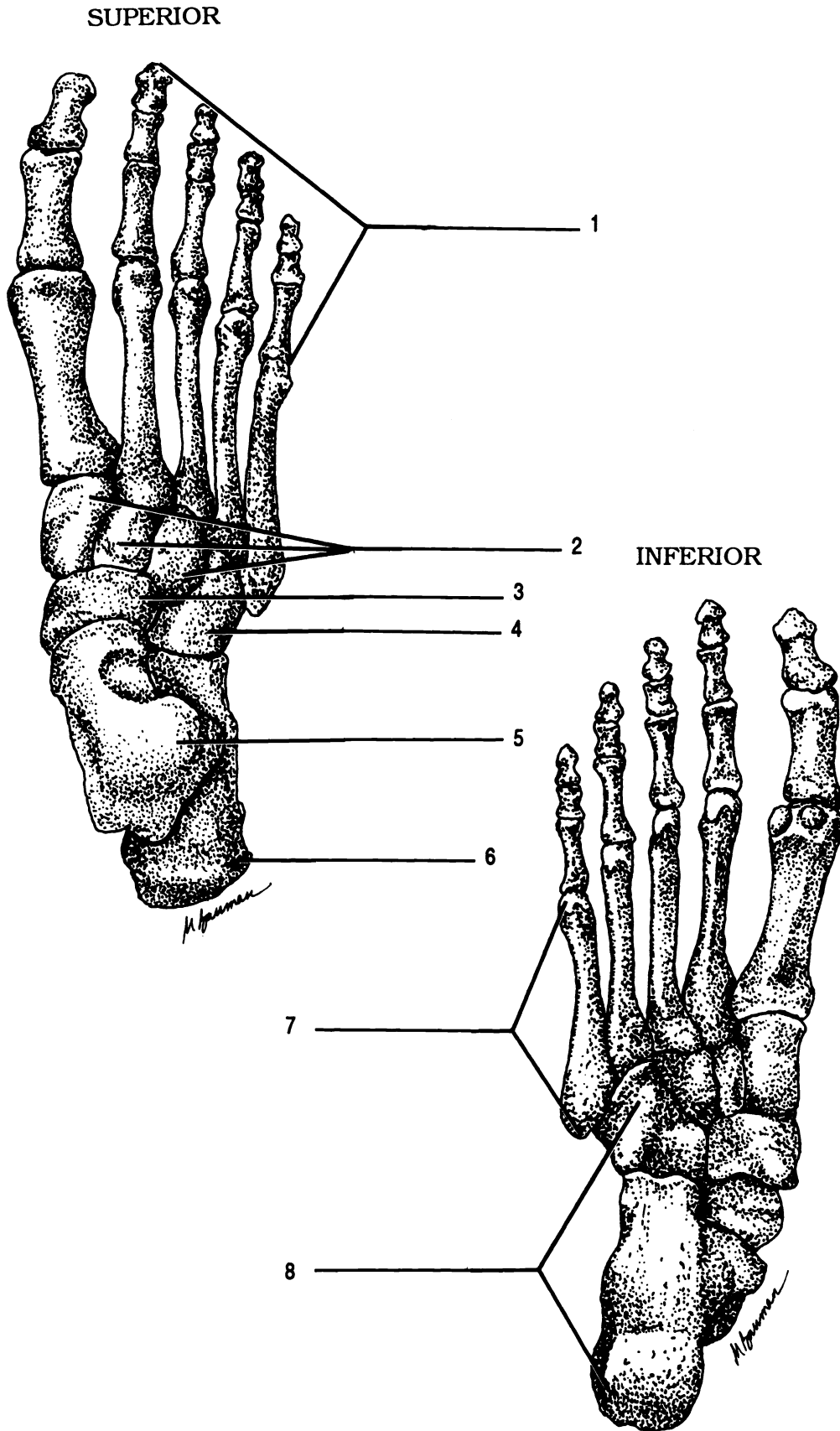
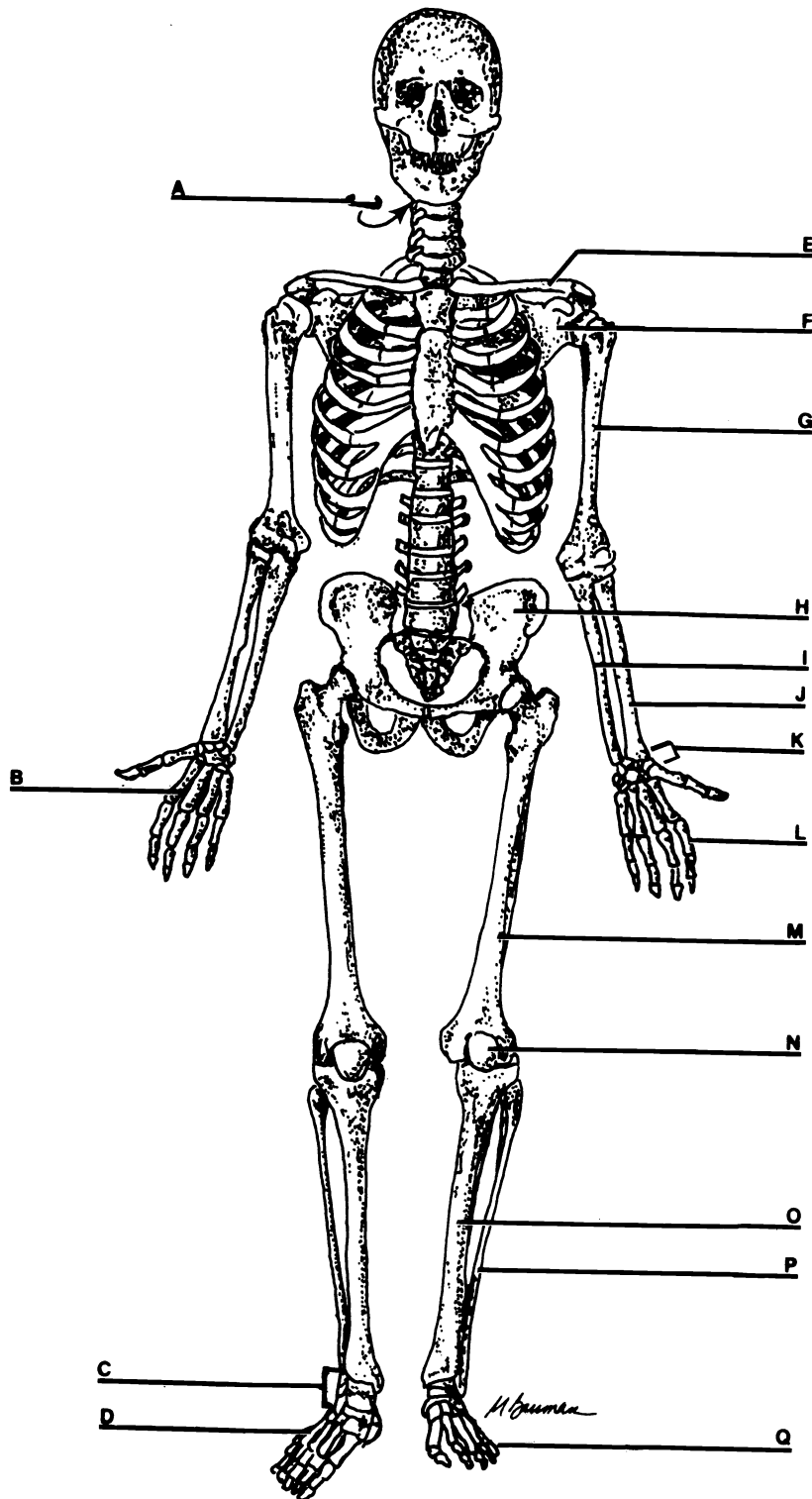


Figure 11.5 Right Foot

Calcaneus Cuboid Cuneiforms Metatarsals Navicular Phalanges Talus Tarsus

CHAPTER 11 REVIEW

1. Label all of the bones on the diagram



2. _____ The hip bone is the (2).
3. _____ The head of the humerus articulates the (3) of the scapula.
4. _____ The head of the femur articulates with the (4) of the hip bone.
5. _____ The head of the ulna is (proximal/distal).
6. _____ The head of the radius articulates with the (6) of the humerus and the (7) of the ulna.
7. _____
8. _____ True or false. The head of the fibula joins the femur at the knee.
9. _____ Which tarsal joins the tibia?
10. _____ Which tarsal joins the fibula?
11. _____ Which bone of the extremities is located within a tendon?
12. _____ How many carpals are there?
13. _____ True or false. The thumb is attached to metacarpal V.
14. _____ Which bone process is the elbow?
15. _____ Which fossa articulates with the trochlea?
16. _____ Which bone process fits into the coronoid fossa?
17. _____ On which bone is this process (#16) located?
18. _____ On which bone is the coronoid fossa located?
19. _____ What is the purpose of the greater trochanter?
20. _____ Describe the exact location of the greater trochanter.
21. _____ Which muscle attaches to the deltoid tuberosity?
22. _____ On which bone would you find the deltoid tuberosity?
23. _____ Which bone is the heel?
24. _____ How many bones are in a tarsus?
25. _____ How is the name of the upper arm bone correctly spelled?

26. _____ In alphabetical order list the two bones of a shoulder girdle.
27. _____
28. _____ The collar bone articulates with the (28) of the scapula.
29. _____ The ridge of bone at the back of the shoulder is the (29).
30. _____ Name the process anterior and superior to the glenoid cavity of the scapula.
31. _____ The medial end of the clavicle is the (31).
32. _____ The two processes which hold the bones of the wrist are the (32).
33. _____ Collectively the bones of the wrist are known as the (33).
34. _____ True or false. The fingers have three phalanges, while the thumb has two.
35. _____ True or false. Unlike the fingers, all the toes have only two phalanges.
36. _____ The longest bone in the body is the (36).
37. _____ Name the large hole in the os coxa.
38. _____ Name the ridge of bone at the hip.
39. _____ Which bone of the axial skeleton articulates with the os coxae?
40. _____ Which part of the os coxa articulates with the other os coxa?
41. _____ Which two processes prevent lateral and medial movement of the talus?
42. _____ The sciatic nerve travels through a groove on the ilium. What is the name of the groove?
43. _____ Name the distal row of carpals from lateral to medial.
44. _____
45. _____
46. _____

47. _____ How many phalanges are there in the entire body?
48. _____ What is the singular of the word "phalanges?"
49. _____ The capitulum articulates with the (49) of the radius.
50. _____ The olecranon of the (50) articulates with the (51) of the humerus.
51. _____
52. _____ What is the purpose of the tibial tuberosity?

CHAPTER 12

ARTICULATIONS

An articulation is a joint, a place where bones or bones and cartilage come together. There are three types of joints based on the amount of movement they allow: synarthrotic, amphiarthrotic, and diarthrotic. Note that these types refer to the physiology of the joints.

Synarthrotic joints are immovable because the bones are held tightly together with fibrous connective tissue or cartilage. There are three types of synarthroses.

Sutures exist between bones of the skull and are held together with collagenous connective tissue continuous with the periosteum. A **synchondrosis** is an articulation held together by cartilage. The joints between the ribs and the sternum are synchondrotic. Some synchondroses are very slightly moveable. A **gomphosis** is a joint in which a peg is held tightly in a socket. An example is the joint between a tooth and the alveolar process.

Slightly moveable joints are termed **amphiarthrotic**.

There are two types of amphiarthroses. **Symphyses** are slightly movable joints with a pad of fibrocartilage between bones held together by ligaments. The joints between the vertebrae and between the os coxae are symphyses. A **syndesmosis** is an amphiarthrotic joint that lacks cartilage, but has a ligament holding the bones together. An example is the articulation between fibula and the tibia.

Diarthroses are freely movable joints. They are also called **synovial** joints. The epiphyses of the bones are covered with articular cartilage. An **articular capsule** holds the two bones together. The articular capsule is made of an outer layer of ligaments and an internal **synovial membrane**. The membrane secretes **synovial fluid** into the **synovial cavity** between the bones. There are six different kinds of diarthrotic joints in the body. They are listed, discussed, and pictured in your textbook.

Exercise 12.1

Label the structures in Figure 12.1.

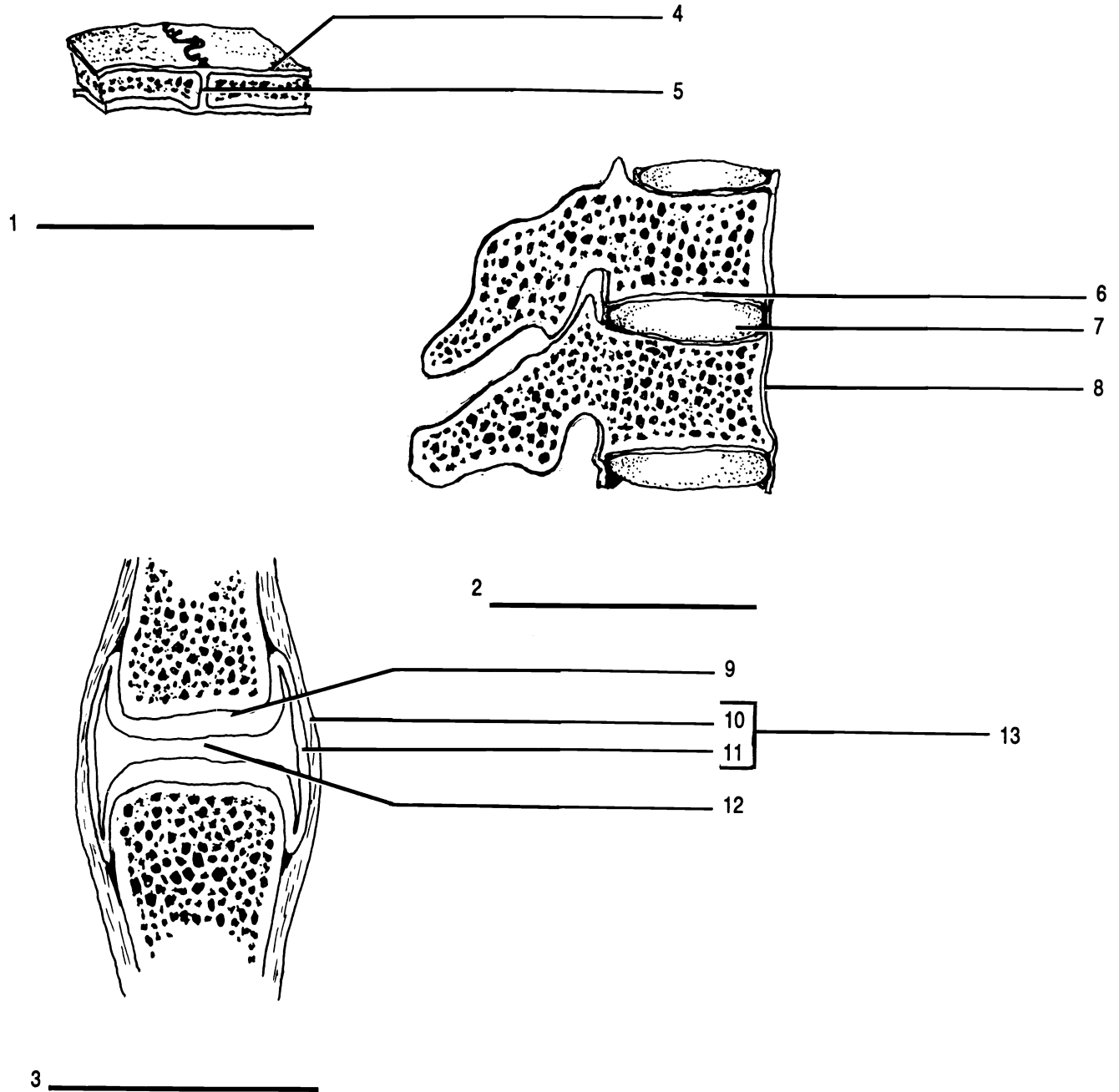


Figure 12.1 Articulations

Articular capsule Articular cartilage (X2) Fibrocartilage pad Fibrous connective tissue Ligament (X2) Periosteum
 Suture Symphysis Synovial cavity Synovial joint Synovial membrane

Exercise 12.2

As you continue reading, label the structures in Figure 12.2.

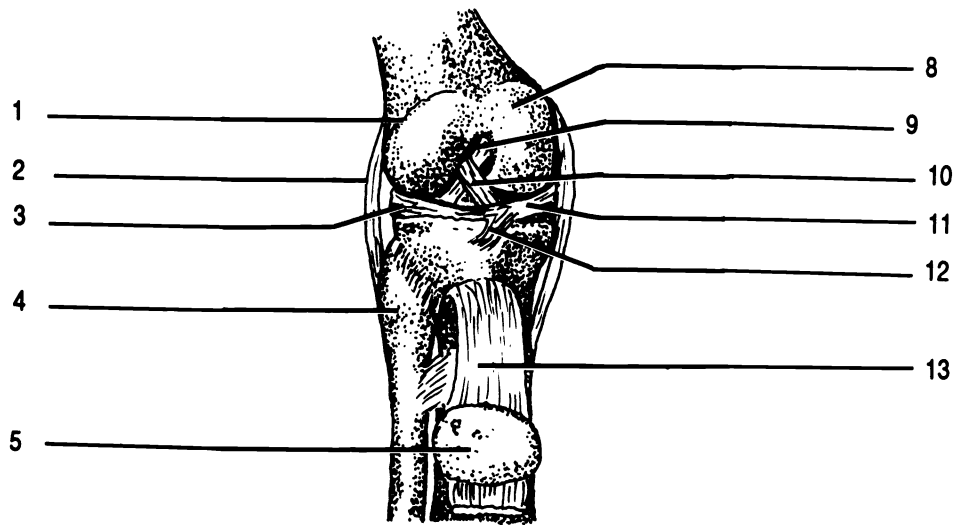
An example of a synovial articulation is the knee joint. Let us examine it in more detail.

To cushion and hold the condyles of the femur and tibia there are two fibrocartilage pads located between the bones. These pads are the **lateral** and **medial menisci** (**sing. - meniscus**). Note that the menisci are thick toward the outside and thin in the middle to provide a socket for the condyles of the femur. The menisci are held together by the **transverse ligament**.

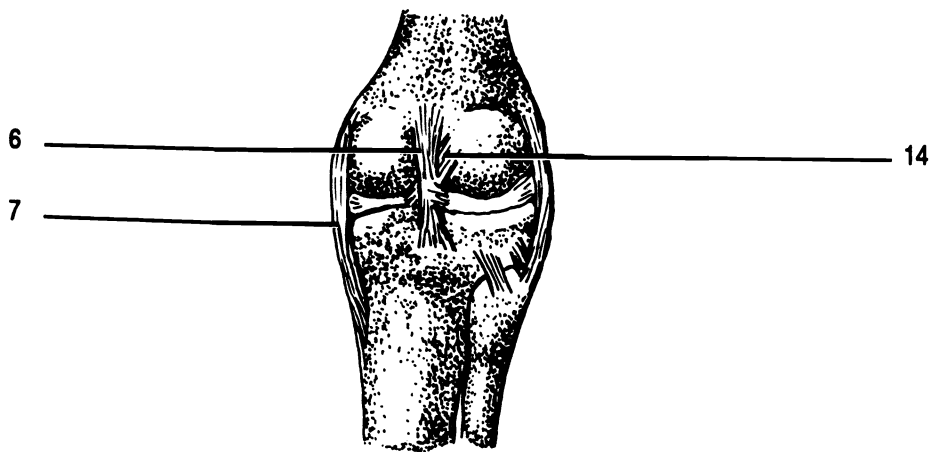
The bones are held together by four main ligaments. The innermost of these ligaments are the **anterior** and **posterior cruciate ligaments**. The word "cruciate" comes from the Latin word *crux* which means cross. Note that the cruciate ligaments form a cross (an X) on the knee. The **fibular collateral ligament** is on the lateral surface and joins the lateral epicondyle of the femur to the head of the fibula. (However, the two bones do not articulate as they have no direct connection.) The **tibial collateral ligament** lies medially and connects the medial epicondyle of the femur to the tibia. There are additional ligaments in the knee joint which we will not discuss.

Anterior to the femur and tibia is the patella. The patella lies inside the **quadriceps femoris tendon**. Between the patella and the leg bones is a cavity, the **suprapatellar bursa**, lined with synovial membrane. The fluid in this bursa acts as a shock absorber in protecting the knee joint.

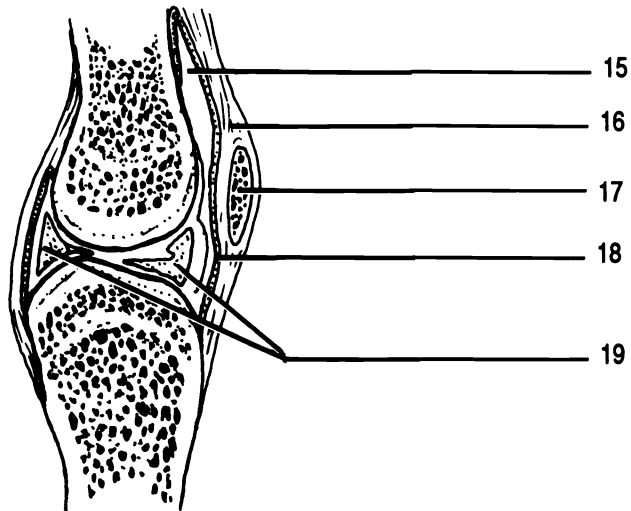
The knee joint is held together almost entirely by soft tissue such as ligaments, synovial membranes, and cartilages. There are no bony projections to prevent dislocations in any direction, thus knee injuries are common among athletes.



ANTERIOR



POSTERIOR



MIDSAGGITAL

Figure 12.2 Right Knee

Anterior cruciate ligament (X2) Fibular collateral ligament Head of fibula Lateral condyle of femur Lateral meniscus
 Medial condyle of femur Medial meniscus Menisci Patella (X2) Patellar ligament Posterior cruciate ligament (X2)
 Quadriceps femoris tendon Suprapatellar bursa Synovial membrane Tibial collateral ligament Transverse ligament

CHAPTER 12 REVIEW

1. _____ The three types of joints are:
2. _____
3. _____
4. _____ Another name for a diarthrotic joint is a (4) joint.
5. _____ What kind of membrane lines a bursa?
6. _____ What does this membrane secrete?
7. _____ What kind of tissue holds suture together?
8. _____ True or false. The pads between vertebrae and the pads in the knee joint are made of the same material, fibrocartilage.
9. _____ The (9) capsule holds diarthrotic joints together.
10. _____ True or false. A symphysis is not moveable.
11. _____ Name the pads located in the knee joint.
12. _____ Name the two ligaments which form a cross in the knee joint.
13. _____ Name a sesamoid bone.
14. _____ What is the function of a bursa?

Classify each of these joints as syndesmosis, synchondrosis, suture, symphysis, or synovial:

15. _____ knee
16. _____ shoulder
17. _____ joint between parietal bones
18. _____ joint between os coxae
19. _____ fibulo-tibial joint
20. _____ joint between the epiphysis and diaphysis in the long bone of a child
21. _____ atlo-occipital joint
22. _____ intervertebral joint
23. _____ hip joint
24. _____ joint between the ulna and the radius

MUSCLE TISSUE AND THE NEUROMUSCULAR JUNCTION

MUSCULAR TISSUE

Muscular and nervous tissues are able to transmit an electrochemical impulse down their cell membranes. These cells are **excitable**. This property sets them apart from other human tissues. In this chapter we will concentrate on muscular tissue and the junction between nervous and muscular tissue. Chapter twenty-one deals more fully with nervous tissue.

In addition to being excitable, muscle cells are **contractile** and **elastic**. That is they can shorten and then return to their original shape. The shortening of muscle cells is responsible for movement in and of the body.

Muscle cells are very long and are often referred to as **muscle fibers**. There are three basic types of muscle fibers (Figure 13.1): skeletal, cardiac, and smooth.

Skeletal muscle tissue is characterized by being multinucleate striated, and voluntarily controlled. **Striated** means that skeletal muscle tissue has regular transverse bands which are visible in the microscope. Skeletal muscles are usually attached to bones which the muscles move.

Cardiac muscle tissue is found only in the heart. These cells are not multinucleate, but they are striated. The striations are not as prominent as those of skeletal muscle. Individual fibers are bound to one another with specialized structures termed **intercalated discs**.

Cardiac fibers contract spontaneously, though the rate of contraction is under involuntary nervous control.

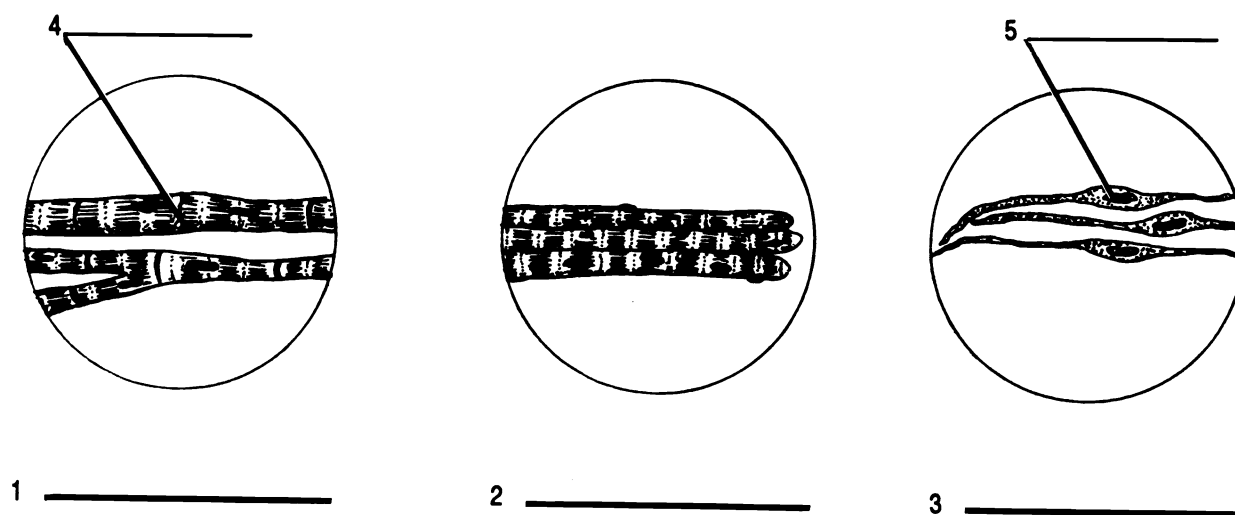


Figure 13.1 Muscle Tissues

Cardiac muscle Intercalated disc Nucleus Skeletal muscle Smooth muscle

Smooth muscle fibers are characterized by the lack of striations and by being involuntary. The fibers contain one nucleus and taper toward the ends from a thickened middle region. Smooth muscles are located in the walls of blood vessels, the stomach, intestines, and other hollow internal organs.

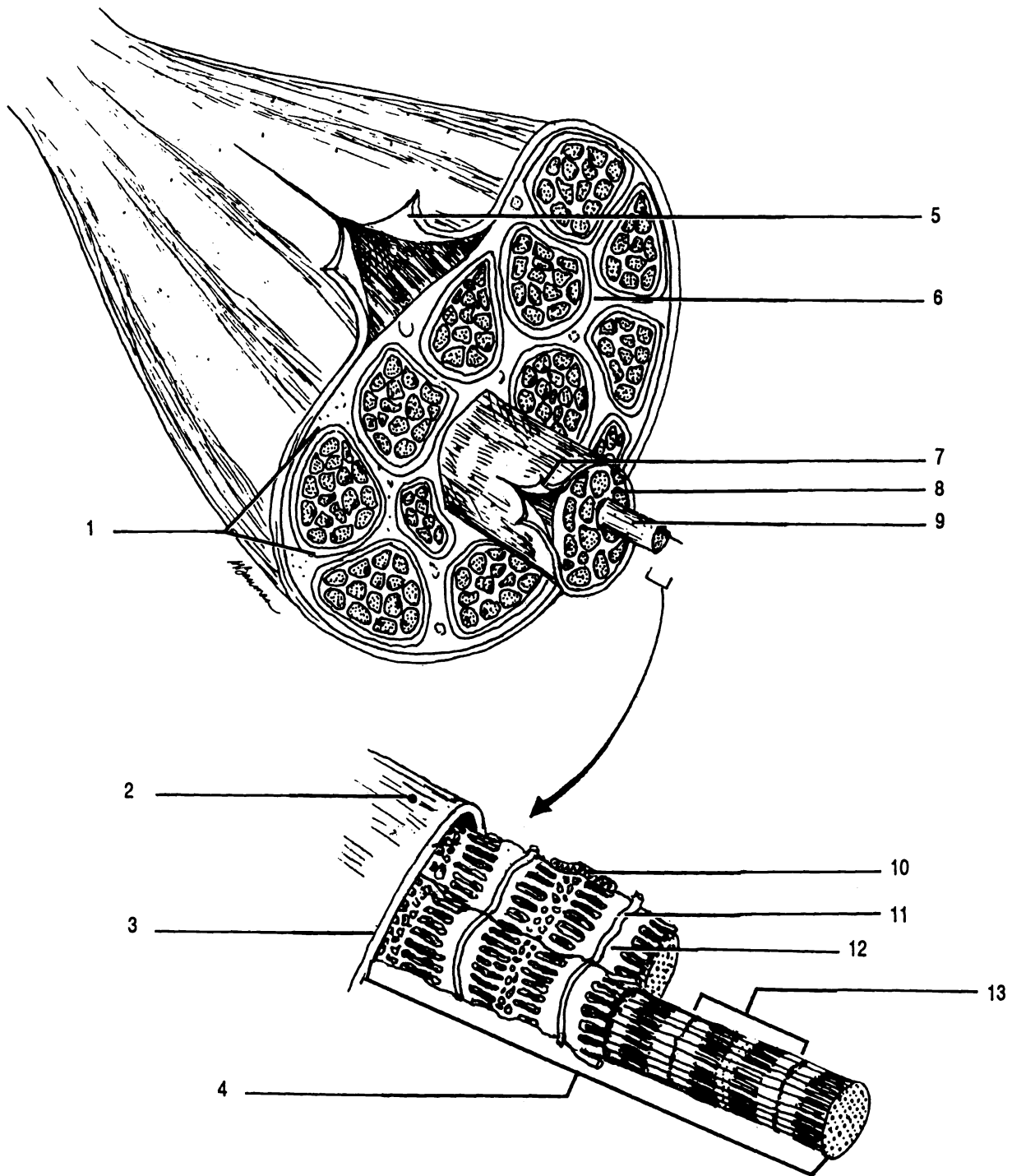


Figure 13.2 Skeletal Muscle

Deep fascia Endomysium Epimysium Fasciculus Mitochondrion Muscle fiber Myofibril
 Opening of a transverse tubule Perimysium Sarcolemma Sarcomere Sarcoplasmic reticulum Transverse tubule

Details of skeletal muscles are shown in Figure 13.2. The muscle is covered with fibrous connective tissue called the **deep fascia**. The deep fascia has been reflected back in Figure 13.2. Underneath the deep fascia is another layer of fibrous connective tissue, the **epimysium**. The muscle can be seen as a bundle of structures termed **fasciculi (sing. - fasciculus)** (L. small bundle) held together by the epimysium. Each individual fasciculus is wrapped in yet another layer of fibrous connective tissue, the **perimysium**. A fasciculus is a bundle of muscle fibers or cells. Each fiber within the fasciculus is embedded in yet another layer of fibrous tissue called the **endomysium**.

Each skeletal muscle cell has a cell membrane called the **sarcolemma**. Extensions of the sarcolemma pass through the cell in the form of tubes called **transverse tubules**. Transverse tubules are also known as **T tubules**.

Inside the sarcolemma are nuclei, mitochondria, and other cell organelles. A special type of endoplasmic reticulum, the **sarcoplasmic reticulum**, surrounds long structures called **myofibrils**. Each myofibril is a stack of small contractile units, the **sarcomeres**, which are the functional unit of the muscle. Each sarcomere is a bundle of alternating **thin and thick myofilaments** (seen in cross section as small and large dots in the sarcomeres of Figure 13.2). Thin myofilaments are primarily composed of a protein called **actin**. The thick myofilaments are made of another protein, **myosin**.

The myofilaments overlap one another in distinctive and repetitive patterns. It is this overlapping that produces the striations visible in the microscope. The various regions of the sarcomere have been given names. The ends of the sarcomeres where the thin myofilaments have their beginnings are the **Z lines**. They have a Z-like arrangement in electron micrographs. The clearer zone flanking the Z lines is an **I band**. The I bands are regions of thin myofilaments without overlapping thick myofilaments. The less dense zone in the center of the sarcomere contains thick myofilaments only. This region is the **H zone**. The band where the thin and thick filaments overlap plus the H zone is the **A band**.

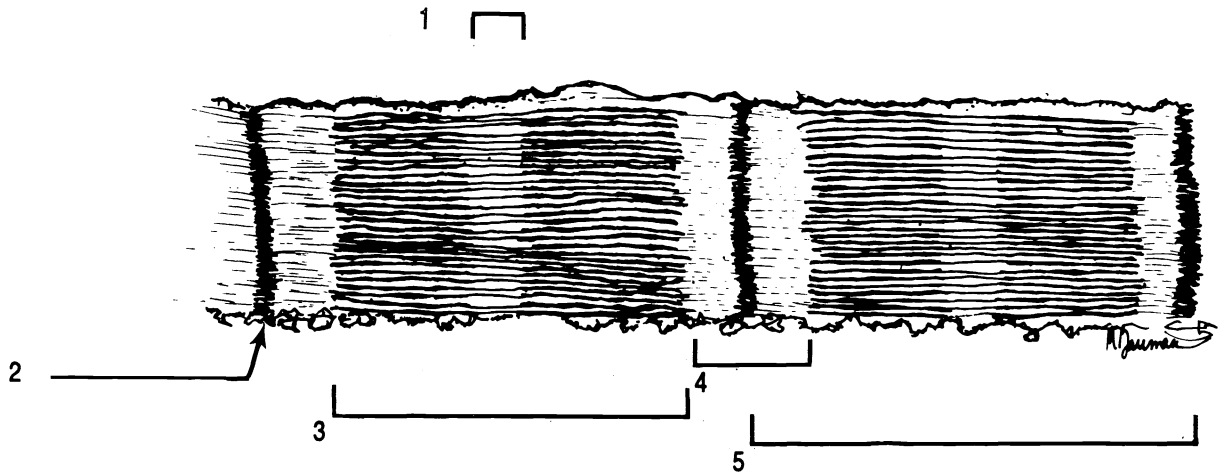


Figure 13.3 Sarcomere

A band H zone I band Sarcomere Z line

We have seen that the muscle is a bundle of fasciculi which are bundles of muscle fibers (cells) which are bundles of myofibrils which are stacks of sarcomeres which are bundles of myofilaments. Go over this material several times until you fully understand it.

Exercise 13.1

Label Figures 13.1, 13.2, and 13.3. Pay special attention to the series of bundles and their "wrappers" which make up a muscle.

Exercise 13.2

Examine microscopic slides of skeletal, smooth, and cardiac muscle tissues. Note the characteristic features of each.

Exercise 13.3

Closely examine the model of the muscle cell. Locate: actin, mitochondrion, myofibril, myosin, opening of transverse tubule, sarcolemma, sarcomere, sarcoplasmic reticulum, and transverse tubule.

NEUROMUSCULAR JUNCTION

Each skeletal muscle fiber is stimulated to contract by a branch of a nerve cell, a **neuron**. The muscle fiber is said to

be **innervated** by the neuron. The neuron and the muscle make contact at the **neuromuscular junction**. Normally, there is one junction at the middle of each muscle fiber, though one neuron may innervate more than one muscle fiber. The neuron and all the muscle fibers it innervates are together called the **motor unit**.

The neuromuscular junction is shown in Figure 13.4. Our knowledge of the junction has been obtained from electron microscopy and biochemical experiments. Do not expect to be able to see this much detail with your microscope.

The long branch of the neuron travelling to the muscle fiber is the **axon**. The axon branches into several **axon terminals** each of which is in close proximity to the sarcolemma of the muscle fiber. The portion of the sarcolemma which is adjacent to the axon terminal is the **motor end plate**. The axon terminal and the sarcolemma do not actually touch, they are separated by a space called the **synaptic cleft**.

The distal end of an axon terminal is expanded into a **synaptic end bulb** filled with mitochondria and **synaptic vesicles**. The vesicles store neurotransmitters, chemicals which are capable of initiating a muscular contraction when they are released by the neuron and received by the muscle cell.

The sarcolemma of the motor end plate is folded into many small invaginations called **subneural clefts**. These folds increase the surface area for the reception of the neurotransmitter.

The **sarcoplasm** (cytoplasm) of the muscle cell and a myofibril can be seen underlying the neuromuscular junction in Figure 13.4.

Exercise 13.4

Correctly label Figure 13.4.

Exercise 13.5

Examine a microscopic slide of a neuromuscular junction. Identify the axon, axon terminal, muscle fiber, and synaptic end bulb.

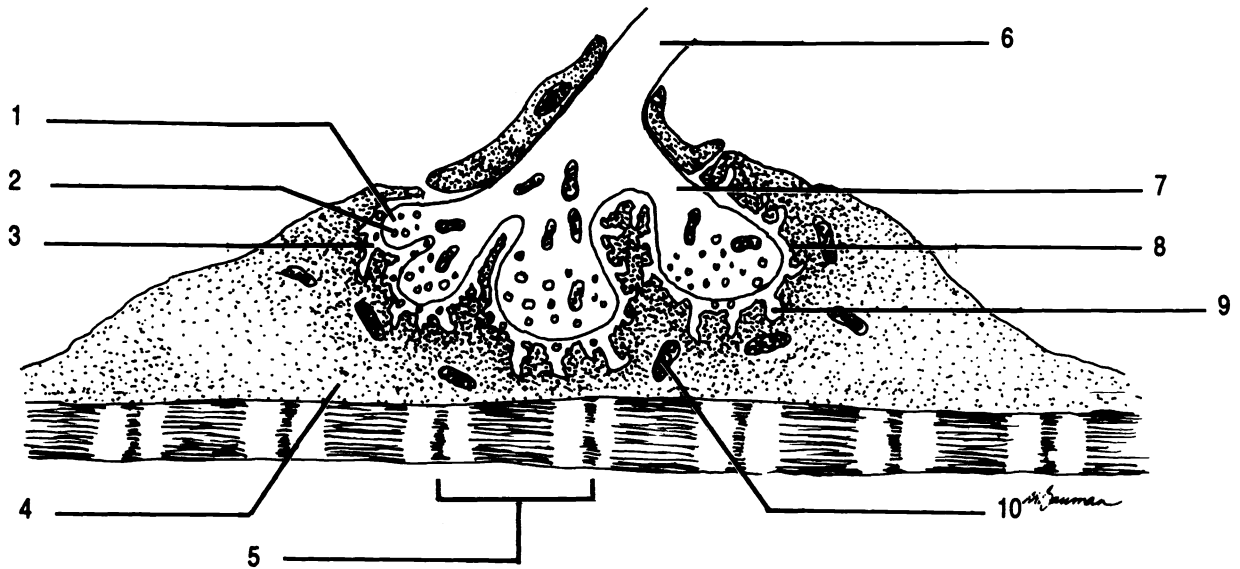
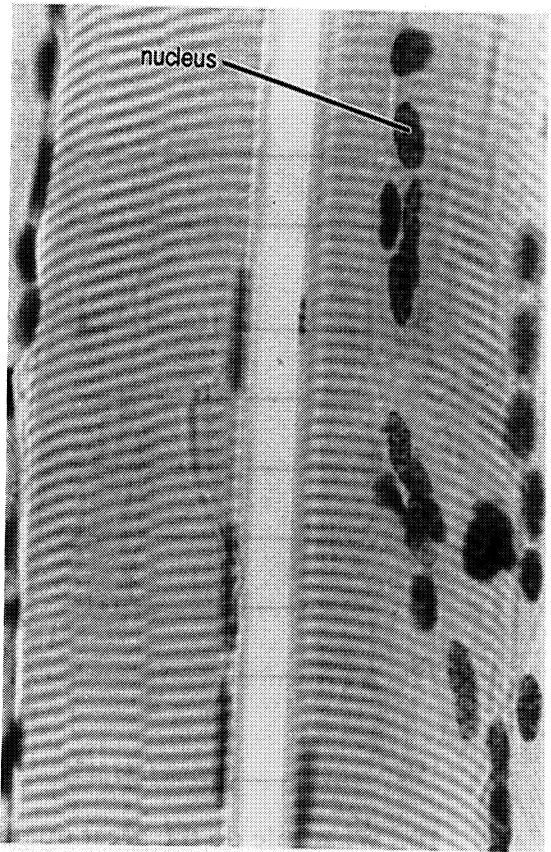


Figure 13.4 Neuromuscular Junction

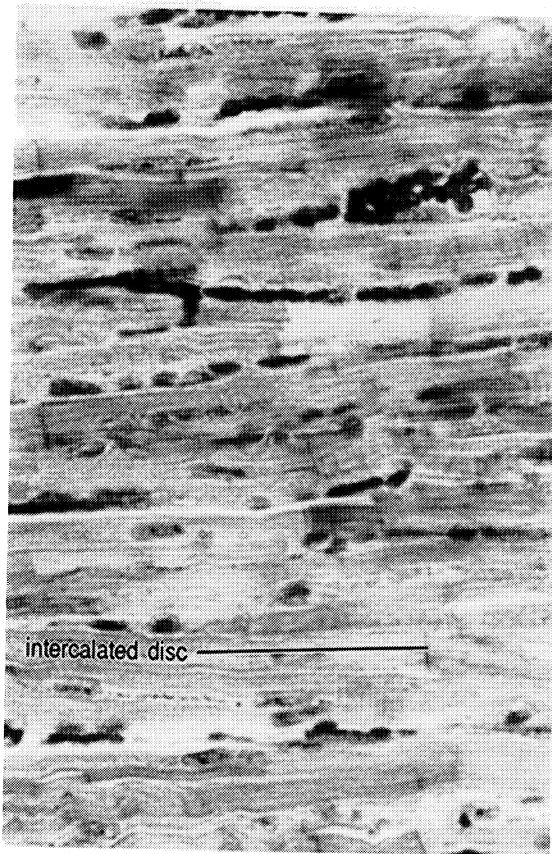
Axon of neuron Axon terminal Mitochondrion Motor end plate Sarcomere Sarcoplasm Subneural cleft Synaptic
 cleft Synaptic end bulb Synaptic vesicle



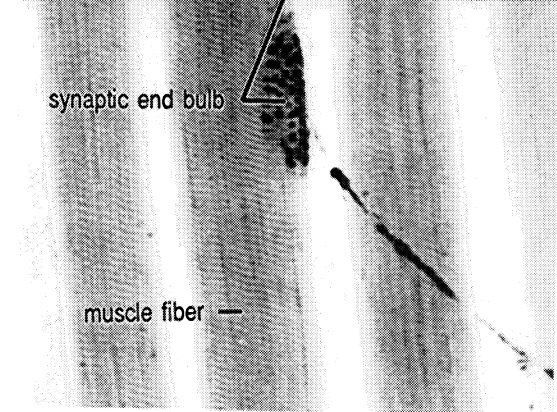

Skeletal muscle



Skeletal muscle



Cardiac Muscle



Neuromuscular junction

CHAPTER 13 REVIEW

1. _____ A fasciculus is a bundle of (1).
2. _____ A tube continuous with the membrane of the muscle cell is the (2).
3. _____ Another name for a muscle cell is a muscle (3).
4. _____ The cell membrane of a muscle cell is the (4).
5. _____ The functional unit of a muscle is the (5).
6. _____ Thick myofilaments are composed of (6).
7. _____ The gap between neuron and muscle is the (7).
8. _____ Invaginations of the motor end plate serve to increase the surface area for the purpose of receiving (8).
9. _____ The invaginations of question eight are called (9).
10. What role do the great number of mitochondria in the axon terminals play in the physiology of the neuromuscular junction?

BODY MOVEMENTS

The action of muscles results in a wide variety of body movements. Knowledge of these movements is essential to an understanding of the skeletal muscles.

Exercise 14.1

As you read the following text, perform the various motions yourself and then label the diagrams in Figure 14.1.

Flexion, Extension, and Hyperextension. In general when two bones are moved closer together from the anatomical position, the motion is flexion. Returning to the anatomical position requires extension. Hyperextension is over extension.

A special kind of flexion is **dorsiflexion**. This is flexion of the foot toward the ankle. Movement of the foot downward or flexion of the toes is **plantar flexion** (as if you were planting your toes in the ground).

Abduction and Adduction. The movement of an appendage away from the midline is abduction. Adduction returns the appendage to the anatomical position. Note that abduction must take place before adduction, just as the letter “b” comes before “d”.

Rotation. Rotation is the movement of a bone or limb around its central axis. An example of rotation is the movement of the radius around the ulna. When the palm is rotated posteriorly the action is **pronation**. **Supination** is the movement of the palm to the anterior.

Circumduction. Circumduction describes the movement of a limb in such a way that the distal end makes a larger circle than the proximal end, for example the movement of a pitcher when he throws a baseball. The arms, legs, and fingers can circumduct.

Inversion and Eversion. Movement of the sole of the foot toward the midline is inversion. Movement of the sole laterally is eversion.

Elevation and Depression. The mandible and the scapulae can be moved up from their horizontal position. Such movement is elevation. Depression is the opposite of elevation.

Protraction and Retraction. The mandible and the scapulae can also be moved forward from the anatomical position. This is protraction. Retraction moves these bones back to the anatomical position.

Sphincter Action. Circular muscles such as those around the eyes and mouth are called sphincter muscles. When the muscles contract they close the opening in a sphincter action.

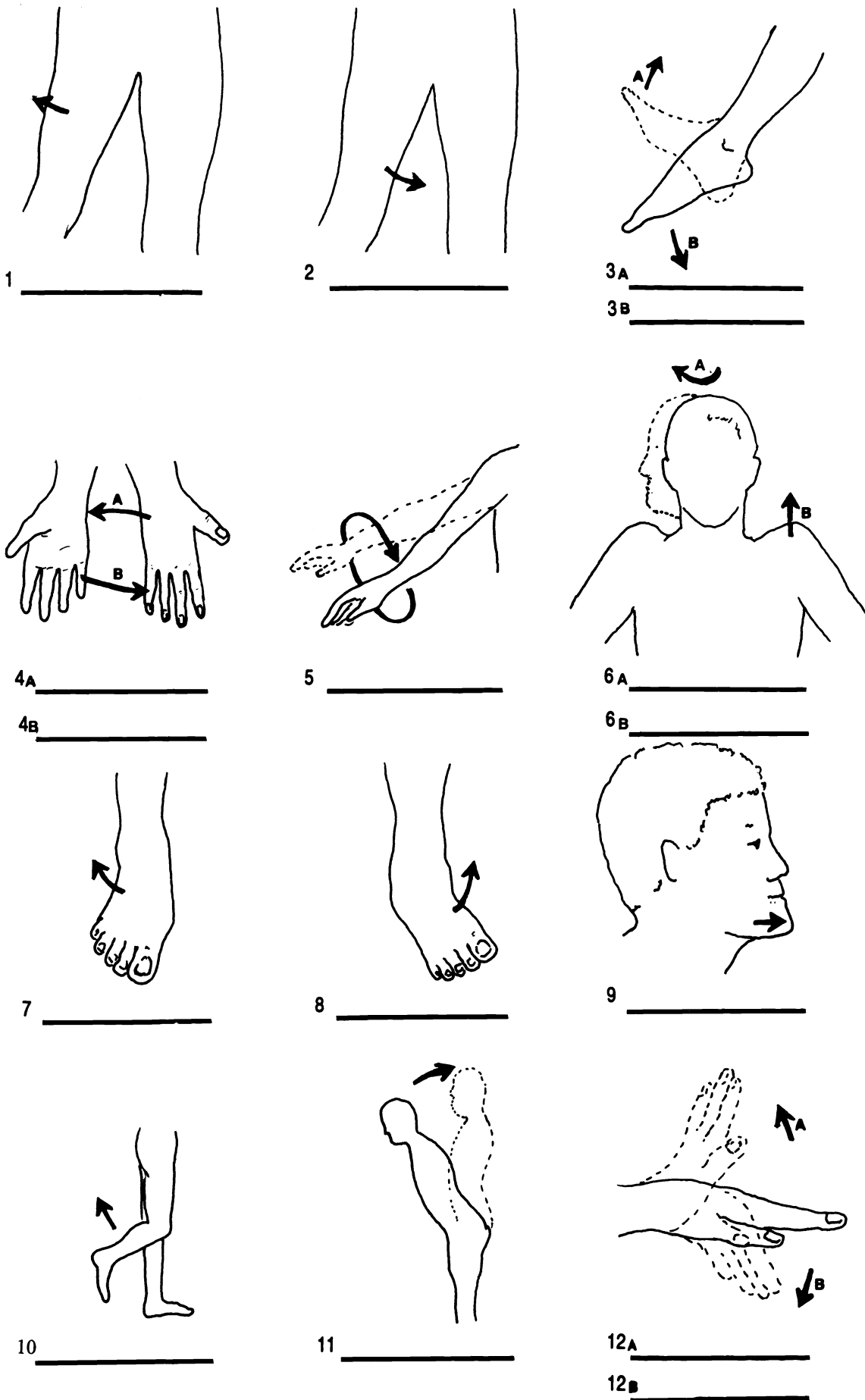


Figure 14.1 Body Movements

Abduction Adduction Circumduction Dorsiflexion Elevation Eversion Extension Flexion (X2) Hyperextension
 Inversion Plantar flexion Pronation Protraction Supination Rotation

CHAPTER 14 REVIEW

For each of the following descriptions write in the word from the list which best describes the action. Each word may be used more than once or not at all. There is of course only one best answer.

1. _____ standing on tiptoes
2. _____ throwing a football
3. _____ looking up at a flying bird
4. _____ bending the knee
5. _____ bending the toes toward the knee
6. _____ pursing the lips
7. _____ moving the arm laterally
8. _____ returning that arm medially
9. _____ clenching the hand into a fist
10. _____ shrugging the shoulders
11. _____ drooping the shoulders
12. _____ flexing the forearm to show off your muscles
13. _____ bending over to touch your toes
14. _____ standing back up
15. _____ movement of the radius around the ulna

abduction
adduction
circumduction
depression
dorsiflexion
elevation
eversion
extension
flexion
hyperextension
inversion

plantar flexion
pronation
rotation
sphincter action
supination

CAT DISSECTION: SKIN REMOVAL

The muscles of the cat are very similar in location, name, and function to those in the human body. We will study the cat muscles to better understand human musculature.

Laboratory cats are preserved with a mixture of alcohol, phenol, and formaldehyde. These preservatives may upset your nose and eyes, but they are necessary if your cat is to be preserved from the growth of fungi and bacteria. The preservatives also eliminate any germs the cats may have been carrying. You may protect your hands from the effect of the preservatives by wearing latex gloves. You may purchase gloves at the college bookstore.

It is important that you use proper laboratory technique during dissections:

1. Remember, the scalpel is sharp! If it will cut a cat, it will cut you. Even if it will not cut a cat, it will cut you! Do not cut toward yourself or your partners!
2. Remove and replace a scalpel blade according to the directions shown below. Avoid injuring yourself and others during this procedure.
3. Discard all solid waste including fat and hair into the trash cans.
4. Clean your laboratory table after use by washing it with alcohol first and then with "sloppy wet" paper towels. Dry your table.
5. Remove all cat fat and hair from the floor. Discard it into the trash cans. Do not wash the floor.

6. Clean all dissecting instruments and trays with soap and water and return them to the proper place.
7. Do not eat or drink while working on the cat.
8. Remember, the scalpel is sharp.

Some anatomical terms for four-legged animals are different from those used for humans. The terms ventral and dorsal refer to the belly and back respectively. The term **caudad** means toward the tail and **cephalad** means toward the head.

Removal of Scalpel Blade:

Grasp the scalpel blade from the back with your right hand.

Release the blade from the handle by pushing the bottom of the blade away from the handle with your left hand (#1).

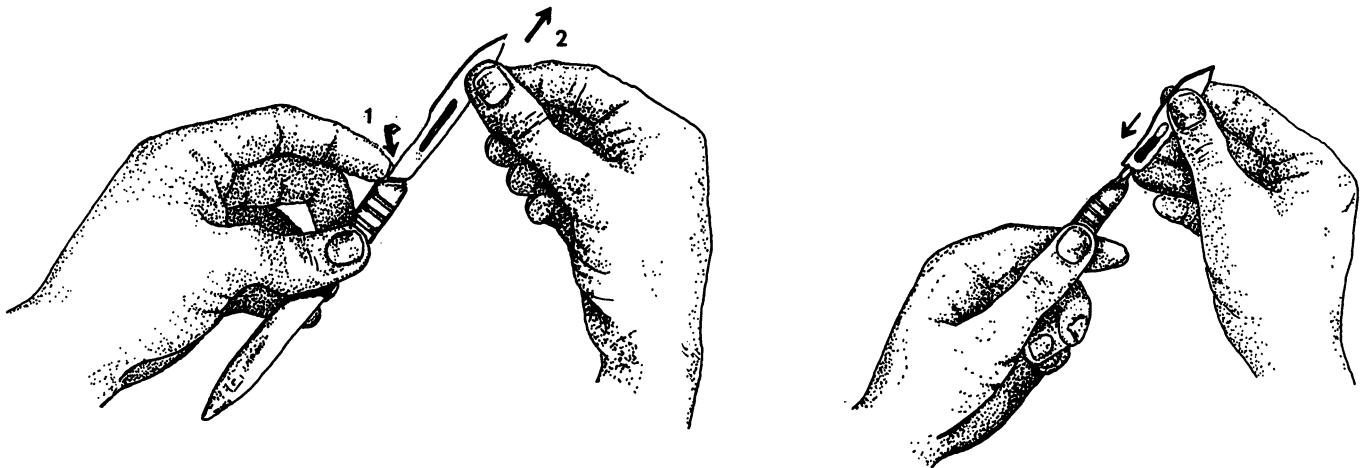
Pull the blade carefully off of the handle (#2).

Installation of Scalpel Blade:

Hold the blade from the back so that the angle at the end of the blade matches the angle on the handle.

Put the small end of the handle into the hole on the blade making sure that the blade fits into the grooves on the handle.

Carefully slide the blade down into place.



Exercise 15.1

Before you begin dissection, fill out the form below.

LABORATORY RULES

1. What is rule eight?

2. What is rule one?

3. _____ True or false: When replacing a dull scalpel blade, one should hold the blade with the back side facing the palm.
4. _____ Discard solid waste into the (4).
5. _____ Wash the table first with (5) and then with (6).
6. _____
7. _____ True or false: Cat hair on the floor is the responsibility of the custodians.
8. _____ True or false: The preservatives in the cats may irritate your eyes.
9. _____ True or false: You can get diseases from preserved cats.
10. _____ True or false: Returning dissection instruments and trays to the proper place is your mother's responsibility.

Exercise 15.2

In order to study the muscles of the cat it will be necessary to remove the skin from the cat. As the proverb correctly states, this can be done in variety of ways. Follow the method preferred by your teacher.

Equipment needed:

dissecting tray

dissecting instruments: scalpel and scissors

name tag and twist tie

rubber gloves

rubber band

METHOD ONE

1. *Lay your cat ventral side down on the dissecting tray. Make a short incision in the cervical region with a sharp scalpel blade. Cut only through the skin which is about 1/8 of an inch thick here. Do not cut the underlying muscles.*
2. *With the scissors or a scalpel continue the incision along the midline to the tail.*
3. *Cut around the tail, be careful not to cut anything sexual! Leave the skin on the tail and the scrotum of the male.*
4. *Separate the skin from the muscles by pulling on it and carefully cutting the superficial fascia (fibrous connective tissue) with the scalpel.*
5. *Examine the cat skeleton to locate the ankles. Make an incision from the tail down each hind leg to the ankles and cut around each ankle.*
6. *Cut the skin around the neck. The neck has already been cut to allow for the injection of plastics into the veins and arteries. Do not cut into the muscles!*
7. *Cut down each foreleg to the wrist. Cut around the wrists.*
8. *Gently remove the skin from the body. If your specimen is a female, locate the mammary glands which will probably be attached to the skin. Remove the mammary glands and discard them into the trash can.*
9. *As time is available remove the connective tissue, fascia, from your cat's muscles. You will have to be "picky" to do this. Use your scalpel sparingly and carefully so as not to cut through muscles.*
10. *Wrap the cat back in its skin.*
11. *Place the wrapped cat back in its bag. Remove as much air as possible and seal the bag with the rubber band or twist tie.*
12. *Label the bag with your names or the name of your cat.*
13. *Replace the cat in the receptacle.*
14. *Clean up your work area according to the laboratory rules.*

METHOD TWO

1. *Place your cat on a dissecting tray with the ventral surface up, dorsal side down.*
2. *Make a midline incision from the chin to the groin. Make sure that you do not cut too deeply. There may be an area in the neck where the skin has already been removed. This area was used to inject colored latex into the arteries and veins of the cat. Since the skin is the thickest in the neck you can see that you need not cut very deep.*
3. *Cut carefully along the mandible, just under the ears and, around the back of the head.*
4. *Make an incision from the midline incision out each arm and leg to the wrist and ankle respectively.*
5. *Cut the skin around each wrist and ankle.*
6. *Gently use a probe or the back edge of a scalpel to separate the skin from the underlying muscle working from the ventral surface to the dorsal surface. If you have a male cat, exercise caution in the groin area to insure that the spermatic cords are not cut. Leave the skin on the scrotum. On both the male and female cat, leave the skin on the tail.*
7. *Once finished, the skin should come off in one piece.*
8. *Wrap the cat back in its skin.*
9. *Place the wrapped cat back in its bag. Remove as much air as possible and seal the bag with the rubber band or twist tie.*
10. *Label the bag with your names or the name of your cat.*
11. *Replace the cat in the receptacle.*
12. *Clean up your work area according to the laboratory rules.*

CHAPTER 16

MUSCLES OF THE TRUNK AND SHOULDER

There are considerable similarities between the muscles of the cat and the human. There are also some differences. We will concentrate on the muscles which are the same. Use the photographs and drawings of the cat to help you locate the muscles.

Surface Muscles

Exercise 16.1

Remove the fat and fascia from the muscles of the thoracic and abdominal areas on both surfaces of your cat.

Then as you read, locate and separate the muscles on the cat.

To separate muscles, carefully cut the connective tissue between them. Do not cut through muscles or underlying structures. Do not cut the muscles from the bones unless instructed to so.

Ventral Thoracic Muscles

There are four surface muscles in the thoracic region of the cat but only one on the human. The four muscles in the cat are called the pectoralis group. They are the pectoantibrachialis, pectoralis major, pectoralis minor, and xiphohumeralis.

The most caudal ("inferior") muscle of the group is the xiphohumeralis. This narrow muscle has no homologue in humans (homologue = a structure with the same position

and/or function). The **pectoralis minor** is cephalad (“superior”) to the **xiphohumeralis** on the cat and is wider than the **pectoralis major**. On the human the **pectoralis minor** is a deep muscle with three parts underneath the **pectoralis major**.

The **pectoralis major** of the cat may appear to have two parts. This is because the **pectoantebrachialis** runs superficially over the **pectoralis major**. There is no homologue to the **pectoantebrachialis** in humans.

Abdominal Muscles

There are four muscles of the abdominal wall of the cat and of the human. Over these muscles are broad flat tendons, known as **aponeuroses** (sing. - **aponeurosis**).

The outermost muscle is the **external oblique**. Note the direction of the fasciculi in this muscle. The fasciculi are oblique to the trunk. Deep to the **external oblique** is the **internal oblique**. The fasciculi of the **internal oblique** run almost perpendicular to the fasciculi of the **external oblique**. The long segmented muscle running from the rib cage to the pubis is the **rectus abdominis**. The fibers of the **rectus abdominis**, like those of all “rectus” muscles, run parallel to the trunk.

The deepest muscle is the **transverse abdominis**. The fasciculi of the **transverse abdominis** run transverse to the trunk. Extra care must be taken to separate the extremely thin **transverse abdominis**, or you will cut through into the abdominal cavity. If you do cut into the abdominal cavity, stop! You will examine the digestive organs later.

Dorsal Muscles

In cats there are three muscles on each side of the dorsal thorax: the **clavotrapezius**, **acromiotrapezius**, and **spino-trapezius**. In humans these three muscles are represented by one muscle, the **trapezius**.

The **clavotrapezius** is the most cephalad of the group in the cat. This muscle joins with the **clavodeltoid**. The **acromiotrapezius** lies superficial to the scapula. The **spino-trapezius** is a triangular muscle extending caudally down the vertebral column.

There is one large muscle on each side of the lower back, the **latissimus dorsi**. This muscle wraps around the side of the body to partially cover the external oblique and the pectoralis group.

Shoulder Muscles

The cat has three shoulder muscles, the deltoid group, homologous to the one **deltoid** muscle of the human. The three deltoid muscles of the cat are the **clavodeltoid**, **acromiodeltoid**, and the **spinodeltoid**.

The clavodeltoid inserts on the proximal end of the ulna of the cat. None of the fibers of the human deltoid muscle insert on the ulna. The clavodeltoid joins with the clavotrapezius. The clavodeltoid is also called the clavobrachialis.

The acromiodeltoid is a small muscle lying between the clavodeltoid and the spinodeltoid. The latter has its origin on the spine of the scapula.

Remember that these three deltoid muscles in the cat are homologues of the single deltoid muscle in the shoulder of the human.

Deep Muscles

Exercise 16.2

On one side of the ventral surface, remove the four muscles of the pectoralis group. Remove the fat and fascia to expose the underlying muscles.

On one side of the dorsal surface remove the trapezius group.

Ventral Thoracic Muscles

There are two major deep muscles to find in the ventral thoracic region. The **serratus ventralis** of the cat is homologous to the serratus anterior in the human. This muscle has a number of divisions coming from the ribs.

Between the serratus anterior and the scapula is subscapularis. This muscle lies on the medial/ventral surface of the scapula.

Deep to the serratus anterior are the external and internal intercostals. As their name implies, the intercostal muscles are between the ribs and the external ones are superficial to the deeper internal intercostals. These muscles assist the diaphragm in breathing.

Dorsal Muscles

We will study the deep muscles of the thoracic region only. These muscles include the rhomboid, rhomboid capitis, supraspinatus, infraspinatus, and teres major.

Connecting the vertebral column with the scapula is the many-portioned rhomboid. This muscle is homologous to the rhomboid major and the rhomboid minor of the human.

The rhomboid capitis of the cat extends from the rhomboid to the head. There is no homologue to the rhomboid capitis in the human.

The supraspinatus, as its name suggests, lies above the spine of the scapula. The infraspinatus lies below the spine of the scapula. The **teres major** runs along the inferior edge of the scapula connecting the scapula to the humerus. The teres major can be seen on both the ventral and dorsal views of the cat.

You are expected to be able to identify all of the muscles of the cat and human in bold print and the additional optional muscles as your teacher requires. For a list of all of the requisite muscles see pages 137 to 139.

Exercise 16.3

Using your textbook as a guide, label the muscles of the human trunk as listed on Figure 16.1.

Exercise 16.4

Examine the model of the human torso. Be able to identify all of the muscles on the model which have been covered in this chapter.

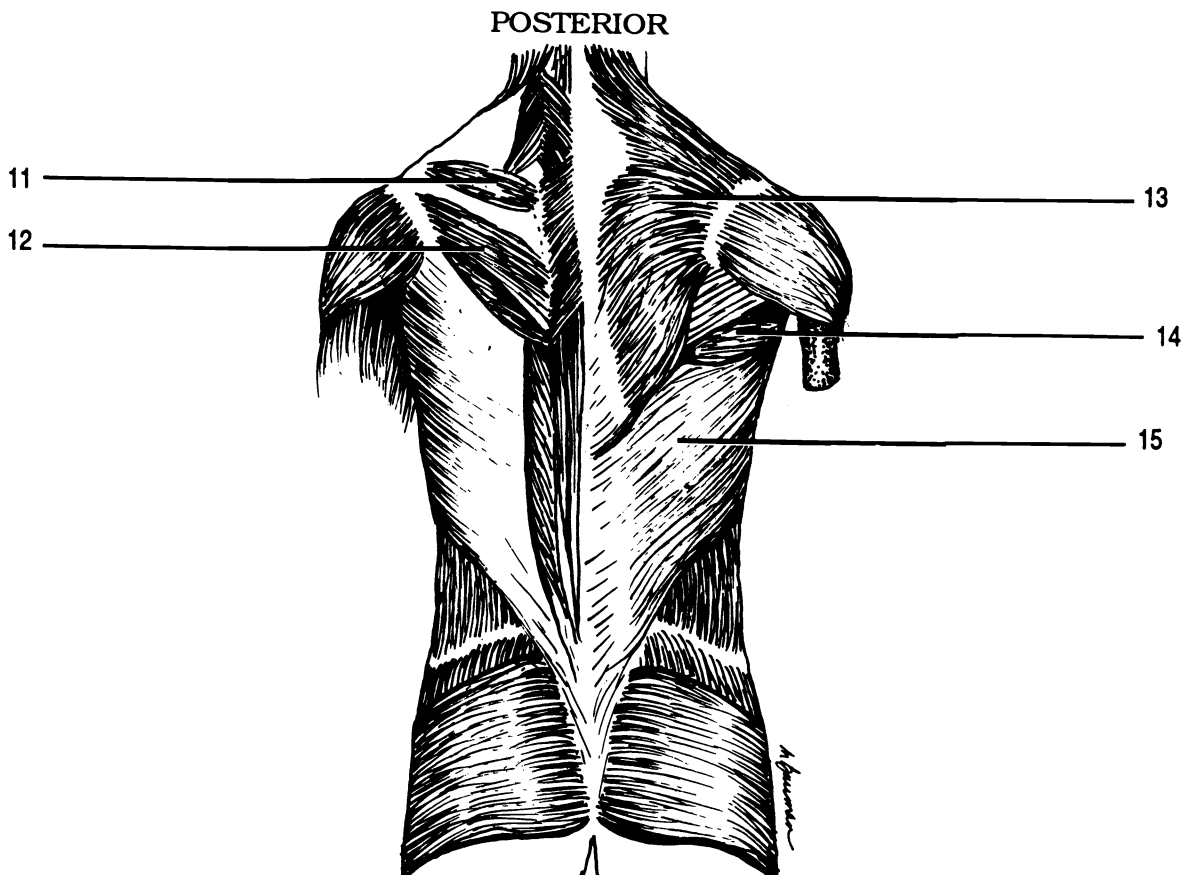
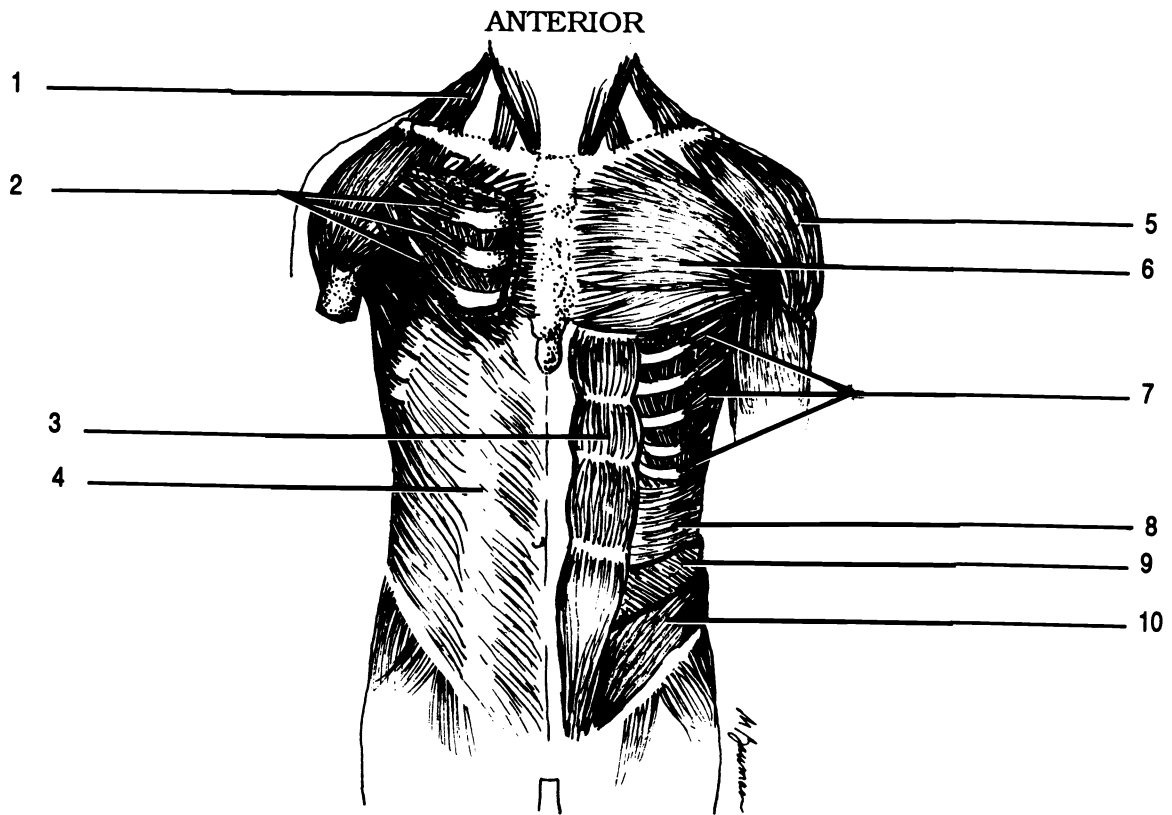
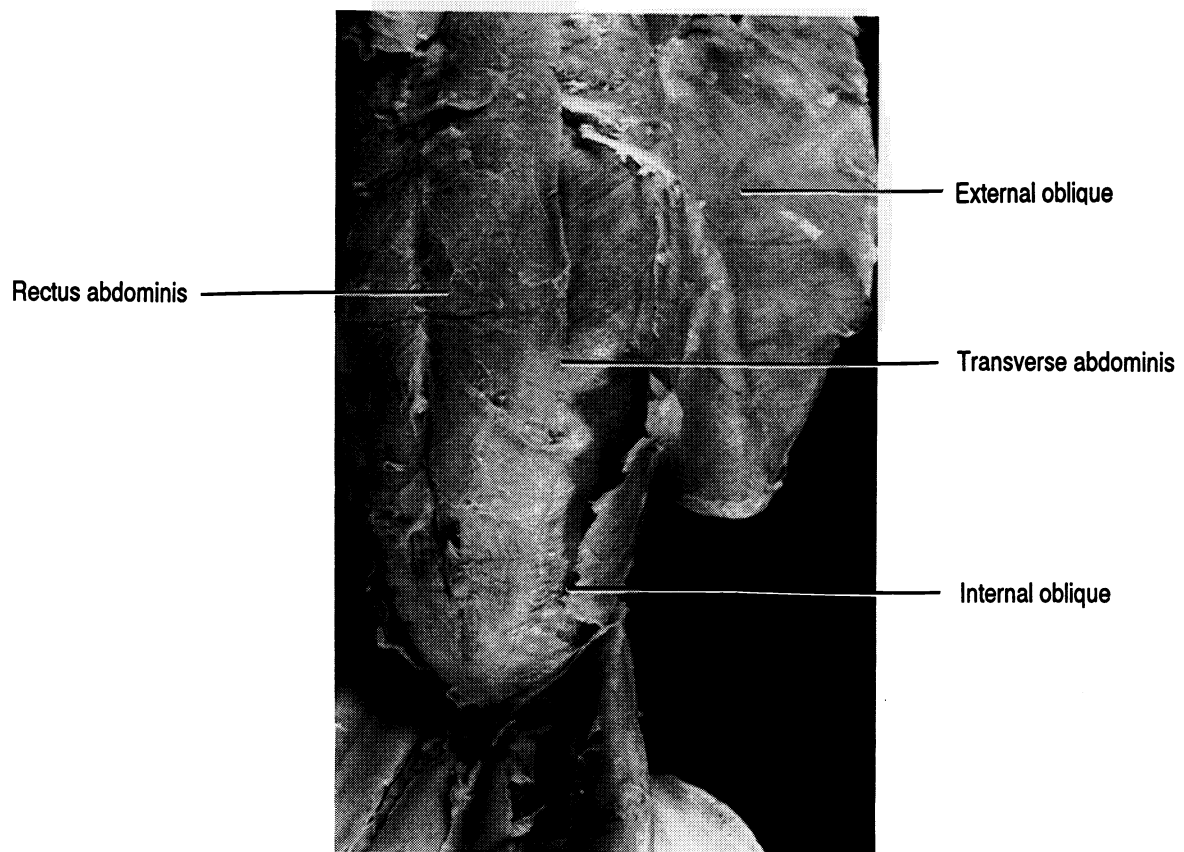
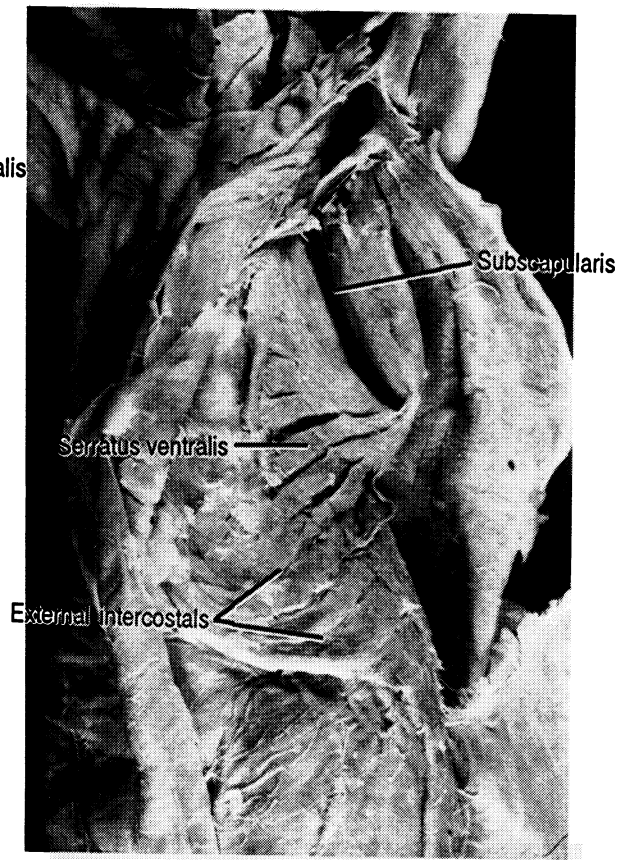
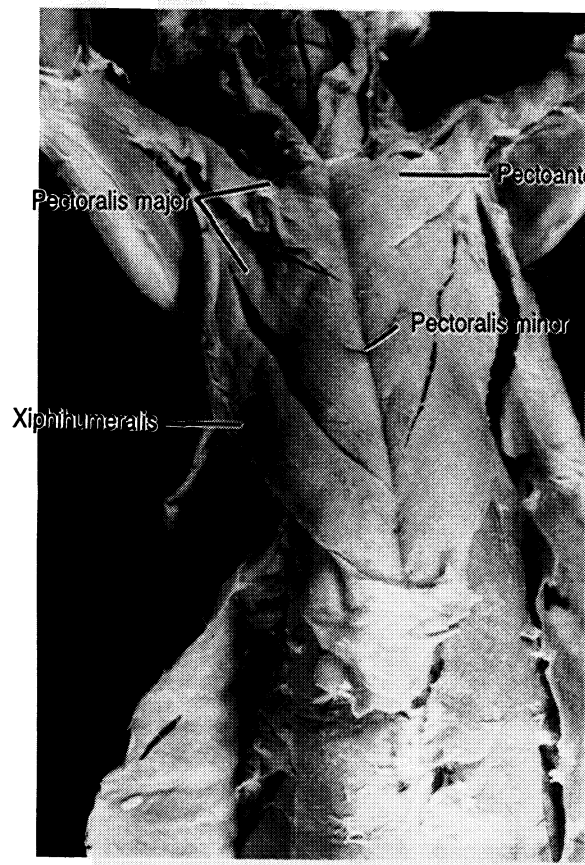
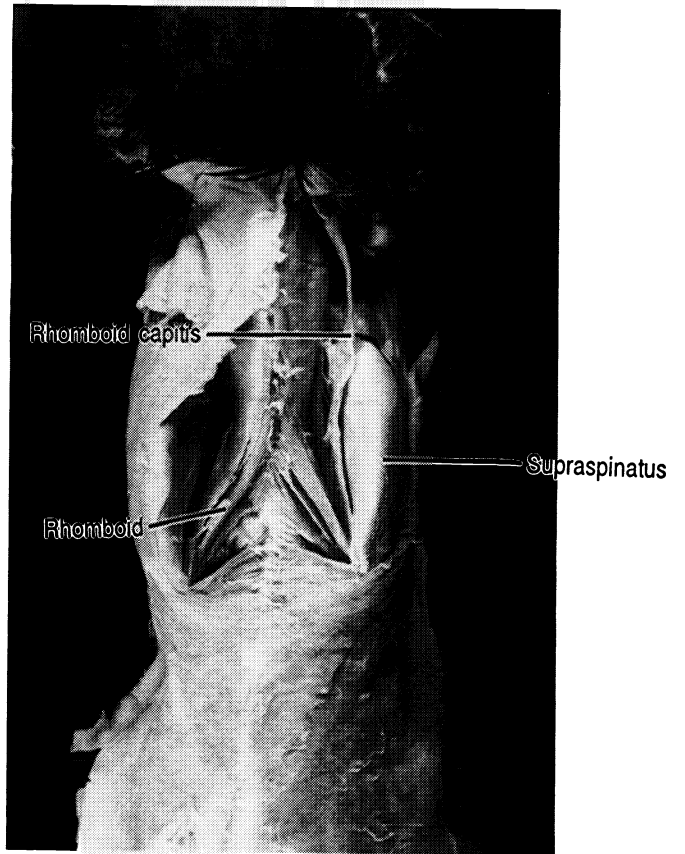
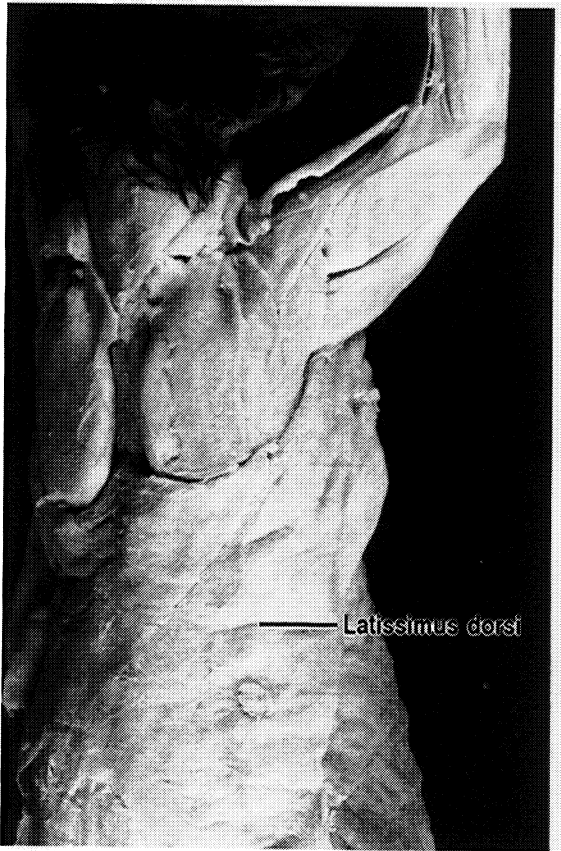
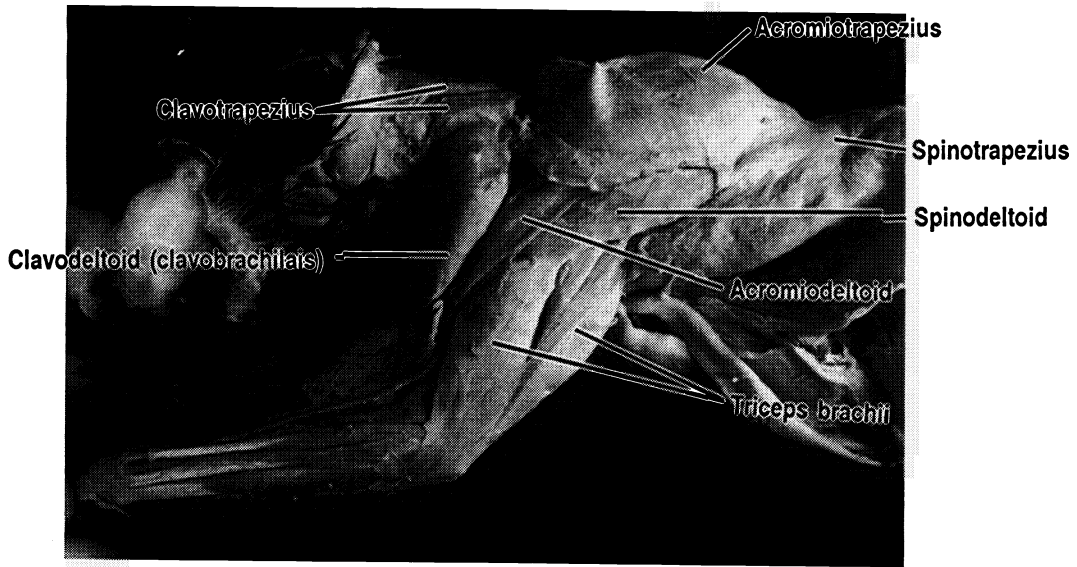


Figure 16.1 Muscles of the Human Trunk

Aponeurosis of external oblique Deltoid External oblique Infraspinatus Internal oblique Latissimus dorsi Pectoralis major
 Pectoralis minor Rectus abdominis Serratus anterior Supraspinatus Teres major Transverse abdominis
 Trapezius (X2)





MUSCLES OF THE HEAD AND NECK

Exercise 17.1

Carefully cut the skin away from the ventral surface of the neck of the cat up to body of the mandible. A portion of the neck may have been mutilated when plastic was injected into the veins and arteries. Do not cut the veins. Do not remove the glands of the neck.

Neck Muscles

Many of the muscles of the neck are named for their sites of origin and insertion. Beginning at the sternum locate the first of these muscles, the **sternomastoid** which begins at the sternum and ends at the mastoid process of the temporal bone. This muscle is homologous to the **sternocleidomastoid** of humans which originates on both the sternum and the clavicle.

Moving toward the head from the sternomastoid find the **sternohyoid**, then the **mylohyoid**, and finally the **digastric**. Lateral to the digastric is the primary muscle for chewing, the **masseter**. Lateral and caudal to the masseter find the submandibular and parotid salivary glands. You may also see lymph nodes in this region.

Optional: Deep Muscles of the Neck

Exercise 17.2

To examine the deep muscles of the neck, cut the sternomastoid and sternohyoid from the sternum on the side of the cat which was most damaged during injection. Be careful not to cut the small underlying muscles.

Deep to the sternohyoid are the sternothyroid and the thyrohyoid. The sternothyroid begins on the sternum and

ends at the thyroid cartilage. The thyrohyoid begins on the thyroid cartilage and ends on the hyoid bone.

All of these neck muscles of the cat are also found in the human. In addition, the human has another muscle, the omohyoid, which runs obliquely from the scapula to the hyoid. It has a tendon which also connects it to the clavicle."

Exercise 17.3

Label the muscles in Figure 17.1. Use your textbook as a guide.

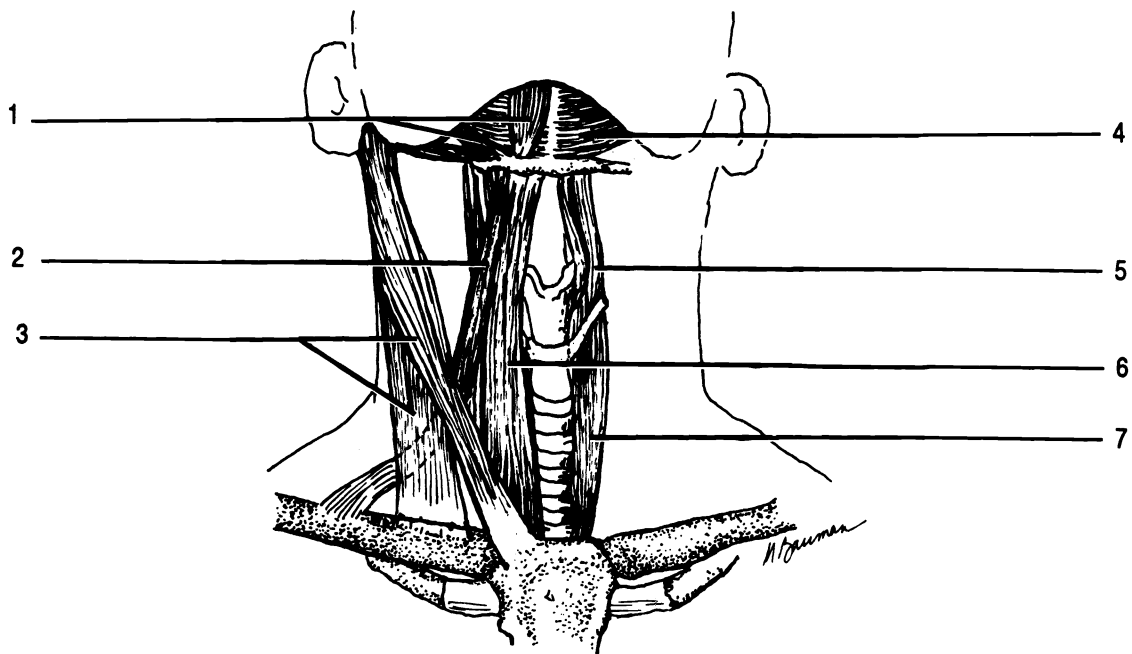


Figure 17.1 Muscles of the Neck

Digastric Mylohyoid Omohyoid Sternocleidomastoid Sternohyoid Sternothyroid Thyrohyoid

Muscles of the Face

Exercise 17.4

Label the muscles of Figure 17.2 as you read.

There are many muscles in the face. We will not concern ourselves with these muscles on the cat, but only on the human.

Underlying the scalp are the **frontalis** and the **occipitalis** muscles. These muscles are named for the bones which lie under them. The two muscles are connected by a broad flat tendon, the **galea aponeurotica**. The frontalis raises the eyebrows and wrinkles the forehead, while the occipitalis pulls the scalp posteriorly.

There are three circular muscles on the face. These muscles are sphincters. They contract with a drawstring-like action. The muscles are the two **orbicularis oculi** which surround and close the eyes and the **orbicularis oris** which closes and puckers the lips.

The **zygomaticus** extends from the zygomatic bone to the corner of the mouth. This muscle pulls the corner of the mouth toward the zygomatic bone, into a smile. Sometimes this muscle is called the **zygomaticus major**.

The **levator labii superioris** is a muscle consisting of three parts. Some books label the lateral third of the levator labii superioris as the **zygomaticus minor**. The levator labii superioris pulls the upper lip up in an expression of disdain.

The **depressor labii inferioris** pulls the lower lip down.

An antagonist is a muscle which works against another. The antagonist of the zygomatic is the **triangularis** which pulls the corners of the mouth down as in a sadness.

The **platysma** is a broad flat muscle covering all of the muscles of the neck. It is listed here with the facial muscles because of its profound effect on facial expression. Contraction

tion of the platysma pulls lower lip downward and posteriorly as in horror.

Masticatory Muscles

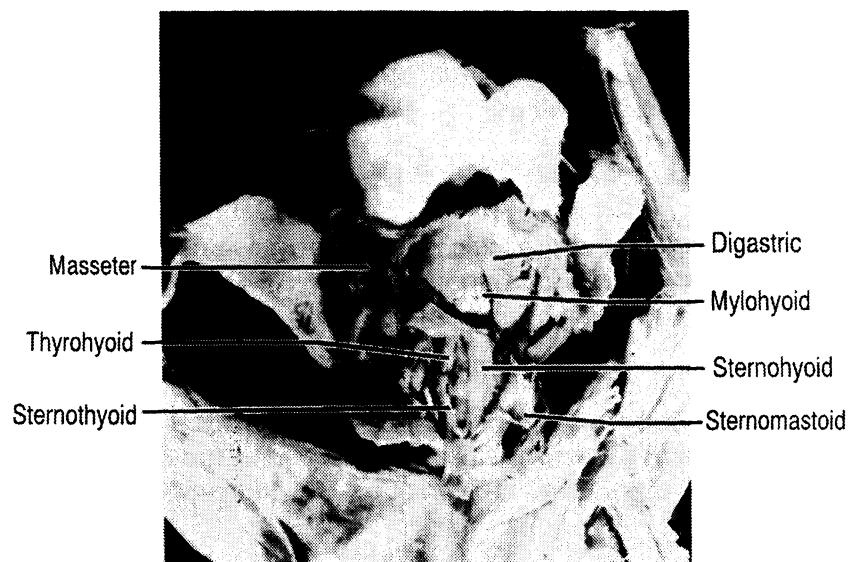There are five major muscles for mastication, chewing, on each side of the head. The primary muscle for elevation of the mandible is the **masseter**. The **temporalis** lying over the temporal bone acts synergistically with the masseter. Another muscle working with the masseter to elevate the mandible is the **medial pterygoid**. The medial pterygoid is medial to the ramus of the mandible, and so cannot be seen in Figure 17.2.

Depression of the mandible is greatly assisted by gravity and there is only one major pair of muscles involved. These muscles are the **lateral pterygoids**. They are hidden by the surface muscles in Figure 17.2.

The final set of muscles involved in mastication are the **buccinators**. These muscles form the cheeks, and function to push food between the teeth for chewing. The buccinator is barely visible in Figure 17.2, deep to the masseter and zygomaticus.

Exercise 17.5

Closely examine the models of the human head. Be able to correctly identify the muscles which have been covered in this chapter.



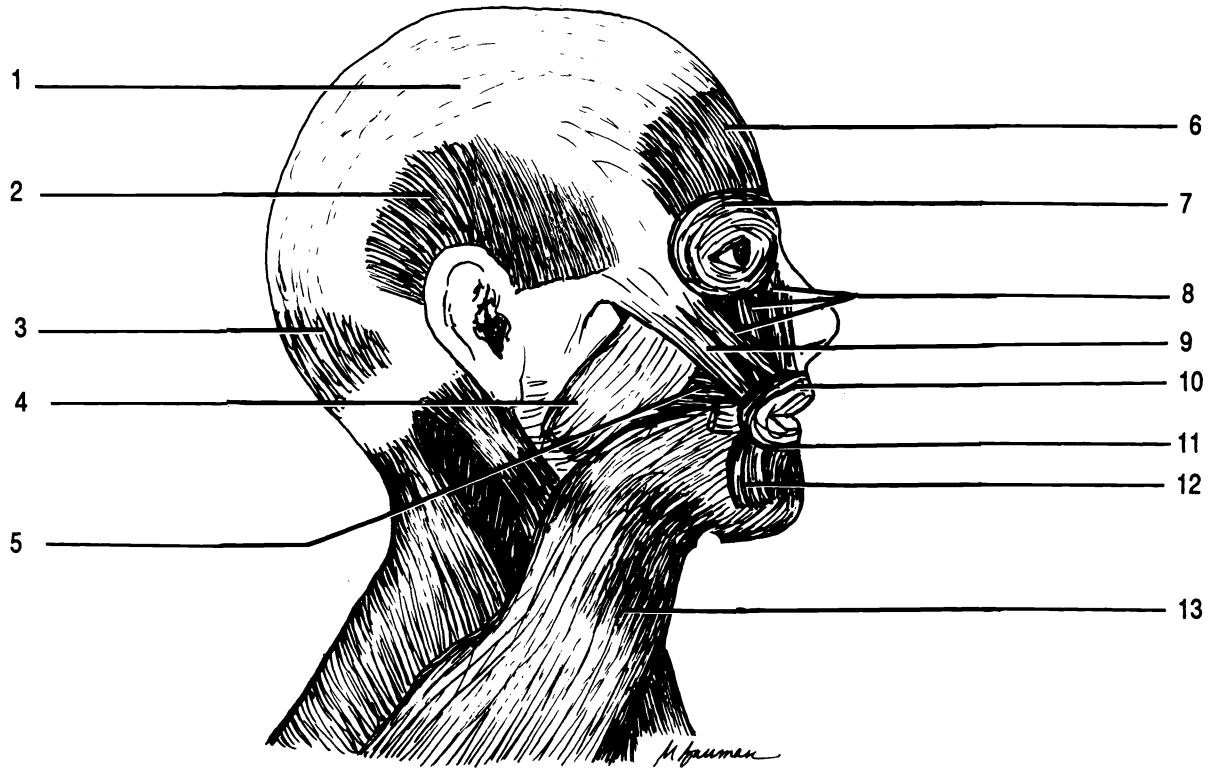


Figure 17.2 Muscles of the Face

Buccinator Depressor labii inferioris Frontalis Galea aponeurotica Levator labii superioris Masseter Occipitalis
 Orbicularis oculi Orbicularis oris Platysma Temporalis Triangularis Zygomaticus

MUSCLES OF THE ARM

Exercise 18.1

Remove excess fascia from the muscles of one forelimb of the cat. Separate the surface muscles from one another. You should find and separate six muscles and the radial nerve on one surface and see six muscles and the same nerve from the other side of the leg as well. Identify the muscles using the drawings and photographs.

Muscles of the Brachium (Upper Arm)

The large muscle on the anterior surface of the upper arm is the **biceps brachii**. This muscle has two origins, thus its name “biceps”. The function of the biceps brachii is to flex the foreleg. In the cat the **pectoantibrachialis** extends from the sternum across the **pectoralis major** and the **biceps brachii** to end on the ulna. The **pectoantibrachialis** has no homologue in humans as was discussed in chapter sixteen. Deep to the **pectoantibrachialis** is the **brachialis**.

The antagonist of the **biceps brachii** is located on the posterior surface. It is the **triceps brachii**. As you might suspect it has three origins.

The **biceps brachii**, **brachialis**, and **triceps brachii** are also found on the human arm.

Muscles of the Forearm

The surface of the forelimb of the cat shows a series of almost parallel muscles. These can be learned in order from lateral to medial on each side of the arm. Their homologues are found in the human.

Examination of the forelimb on the medial/anterior surface should reveal the presence of six muscles and a nerve. The **brachioradialis** muscle is easily separated

from the muscles of the forelimb. It is “up in the air”. The brachioradialis is a synergistic muscle to the biceps brachii, because it flexes the forelimb. Running along this muscle is the radial nerve.

The five muscles on the surface of the forearm from lateral to medial are: extensor carpi radialis, pronator teres, flexor carpi radialis, palmaris longus, and the barely visible flexor carpi ulnaris.

The “carpi” muscle flex and extend the carpus. The palmaris longus flexes the wrist, and the pronator teres pronates the limb.

Exercise 18.2

Examine the pronator teres to note that its fibers extend from the ulna to the radius in such a way that contraction of the muscle will draw the radius across the ulna: pronation!

On the lateral/posterior surface you will again see six muscles and the radial nerve. The muscle next to the nerve is the brachioradialis which can be seen on the cat from both sides.

The five other muscles from lateral to medial are: extensor carpi radialis (it too is visible from both sides), extensor digitorum communis, extensor digitorum lateralis, extensor carpi ulnaris, and again the barely visible flexor carpi ulnaris.

The “digitorum” muscles extend the digits (phalanges) and the “carpi” muscles extend and flex the wrist.

Once you have mastered these muscles on the cat you should have no major problems learning them on a human. However, note the following differences between the cat and the human:

1. The extensor carpi radialis may be hidden on the anterior surface by the brachioradialis of the human.
2. The deep flexor digitorum superficialis is visible in the distal anterior forearm.
3. In the posterior view the brachioradialis is not as easily visible.

4. There are two extensor carpi radialis muscles in the human: extensor carpi radialis longus and extensor carpi radialis brevis.
5. The extensor muscles for the digits have different names in the human. They are the lateral extensor digitorum and the medial extensor digiti minimi.

Exercise 18.3

Examine the model of the human arm and locate all of the muscles discussed in this chapter.

Label the drawings in Figure 18.1.

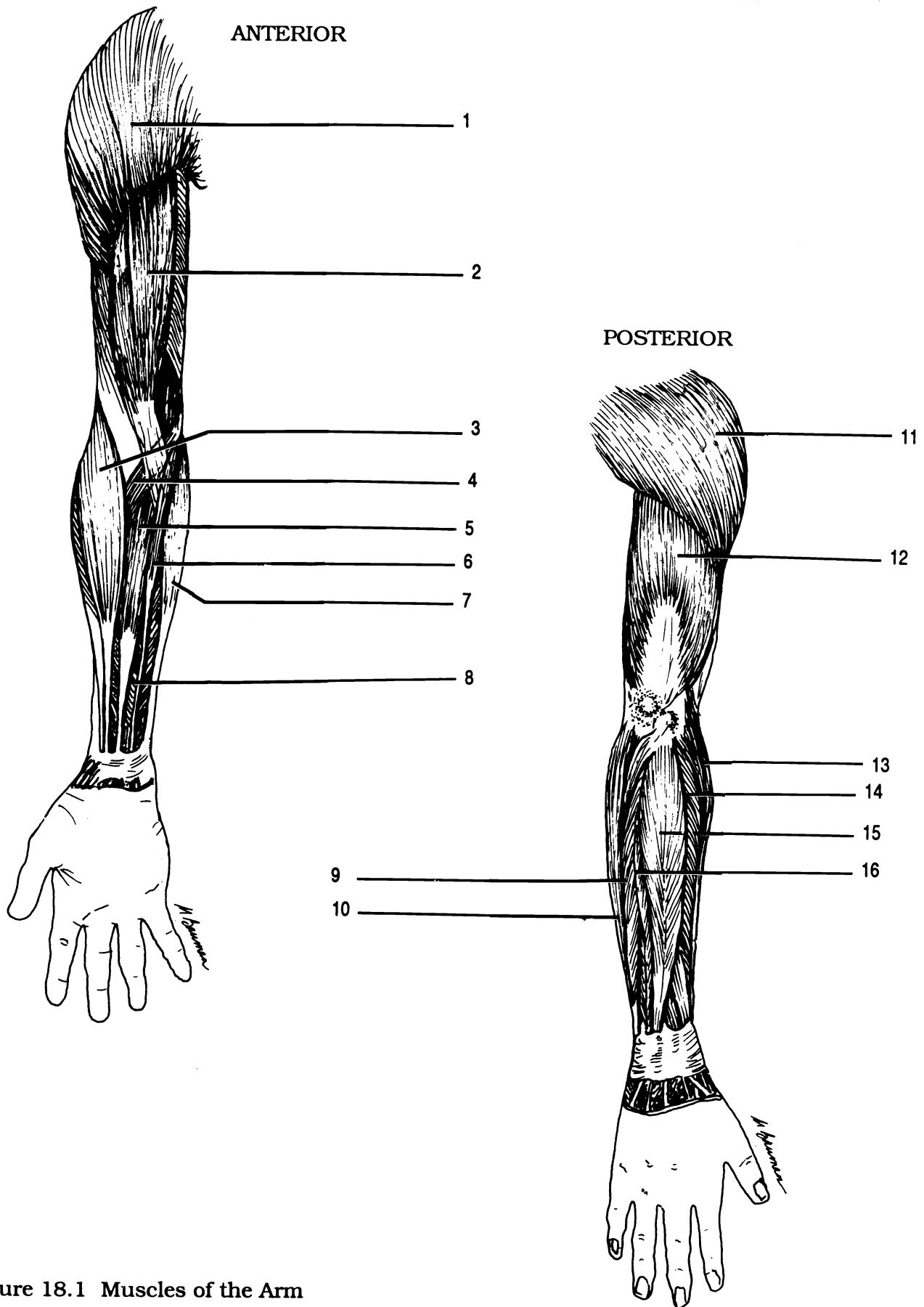
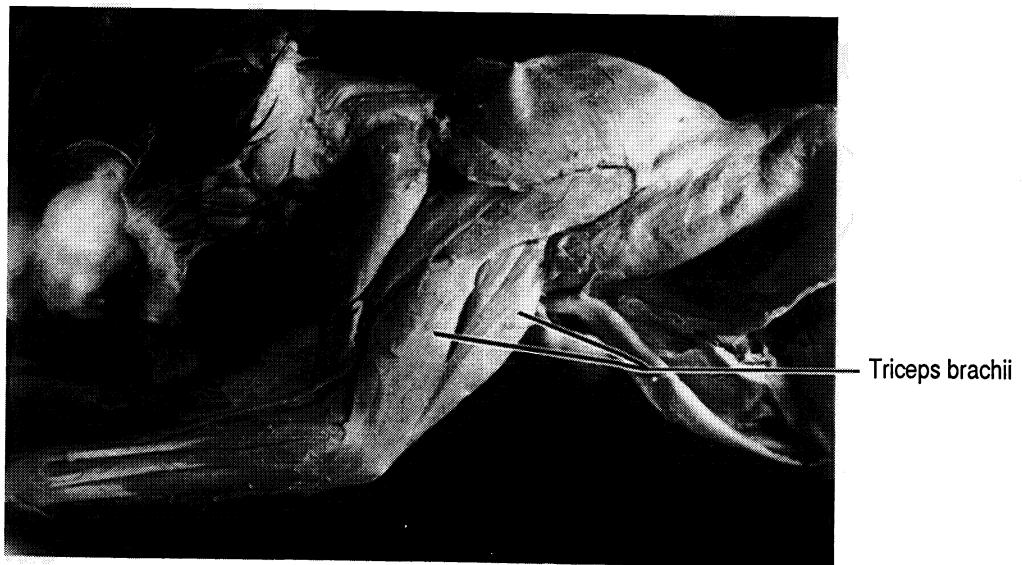
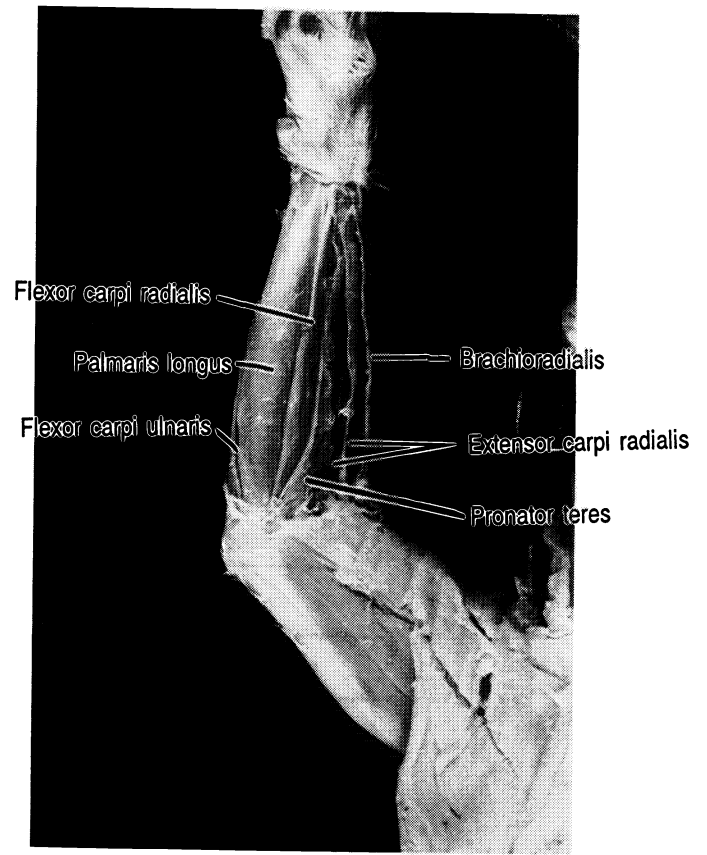
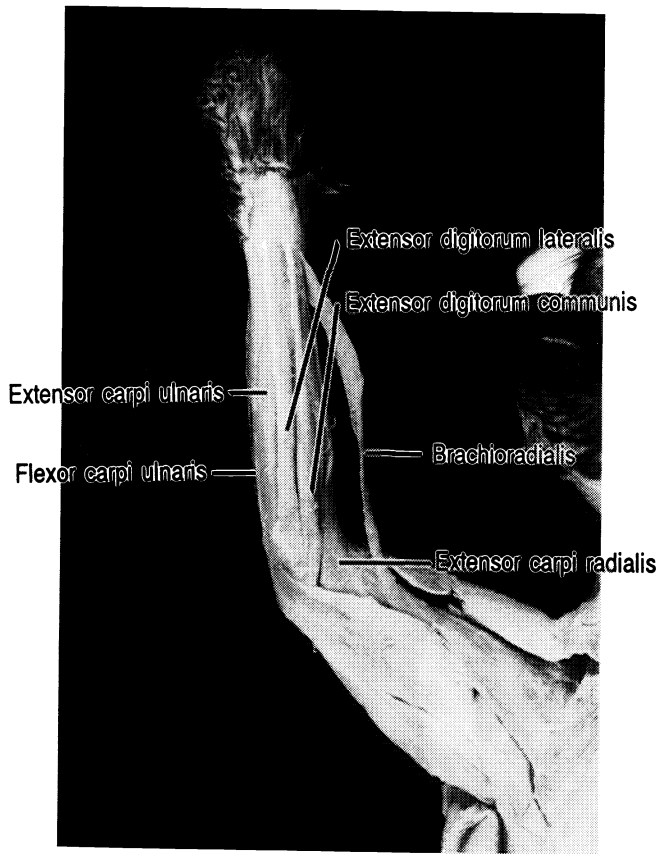


Figure 18.1 Muscles of the Arm

Biceps brachii Brachioradialis Deltoid (X2) Extensor carpi radialis brevis Extensor carpi radialis longus
 Extensor carpi ulnaris Extensor digiti minimi Extensor digitorum Flexor carpi radialis Flexor carpi ulnaris (X2)
 Flexor digitorum superficialis Palmaris longus Pronator teres Triceps brachii



MUSCLES OF THE LEG

Exercise 19.1

Remove the fascia and fat from one leg and hip. Follow the directions to expose, separate, and learn the muscles of the hindlimb of the cat. Compare your cat with the drawings and photographs.

Muscles of the Upper Leg

Begin with the muscles on the medial side. Note the presence of two large wide surface muscles. The lateral muscle is the **sartorius**, the medial muscle is the **gracilis**. On a human these two muscles are relatively narrow and do not hide the underlying muscles as they do in the cat. Furthermore the sartorius is an anterior muscle in the human.

Remove the gracilis and sartorius from the hip on one side to expose the deeper muscles.

Deep to the sartorius are the lateral **tensor fascia lata** muscle with its broad, coarse tendon and the quadriceps femoris. The quadriceps femoris as its name suggests is composed of four parts. Each part is a muscle with its own name. These four are the **vastus lateralis** (located laterally), **rectus femoris** (central), **vastus medialis** (medial) and the deep vastus intermedius which cannot be seen unless you pull or cut the rectus femoris out of the way.

Deep to the gracilis are two of the hamstrings and the adductors. The **semitendinosus** is barely visible on the medial surface close to the knee. The **semimembranosus** is located medial to the semitendinosus. The semitendinosus and semimembranosus are two of the hamstrings. The third hamstring will be discussed below.

Cephalad to the semimembranosus are the adductors. The adductors are **adductor femoris**, **adductor longus**, and the small pectineus. In humans the medial adductor is the **adductor magnus** rather than the adductor femoris.

On the lateral surface of the leg in the cat is the large **biceps femoris**. The biceps femoris is the third hamstring. On a human all of the hamstrings are located posteriorly. Anterior to the biceps femoris are the vastus lateralis and the tensor fascia lata which were observed from the medial side.

Muscles of the Hip

Running from the tail of the cat to the femur, proximal to the biceps femoralis is the caudofemoralis. This muscle moves the tail and has no homologue in humans.

Two other muscles are located in the hip. These are the **gluteus maximus** and the **gluteus medius**. The gluteus maximus is puzzlingly often smaller than the gluteus medius of the cat. In the human the gluteus maximus is larger and superficial to the gluteus medius.

Muscles of the Lower Leg

There are three large muscles in the lower leg. The **gastrocnemius** (pronounced *gastrocnemius*) and the **soleus** lie posteriorly and make up the calf of the leg. The soleus is deep to the gastrocnemius. Both muscles attach to the calcaneus through the **Achilles' tendon**.

On the anterior surface is the **tibialis anterior**.

There are many other flexors and extensors just as there were in the arm, but we will not study them.

Exercise 19.2

Correctly label the muscles in Figure 19.1.

Exercise 19.3

Identify the muscles on the model of the human leg.

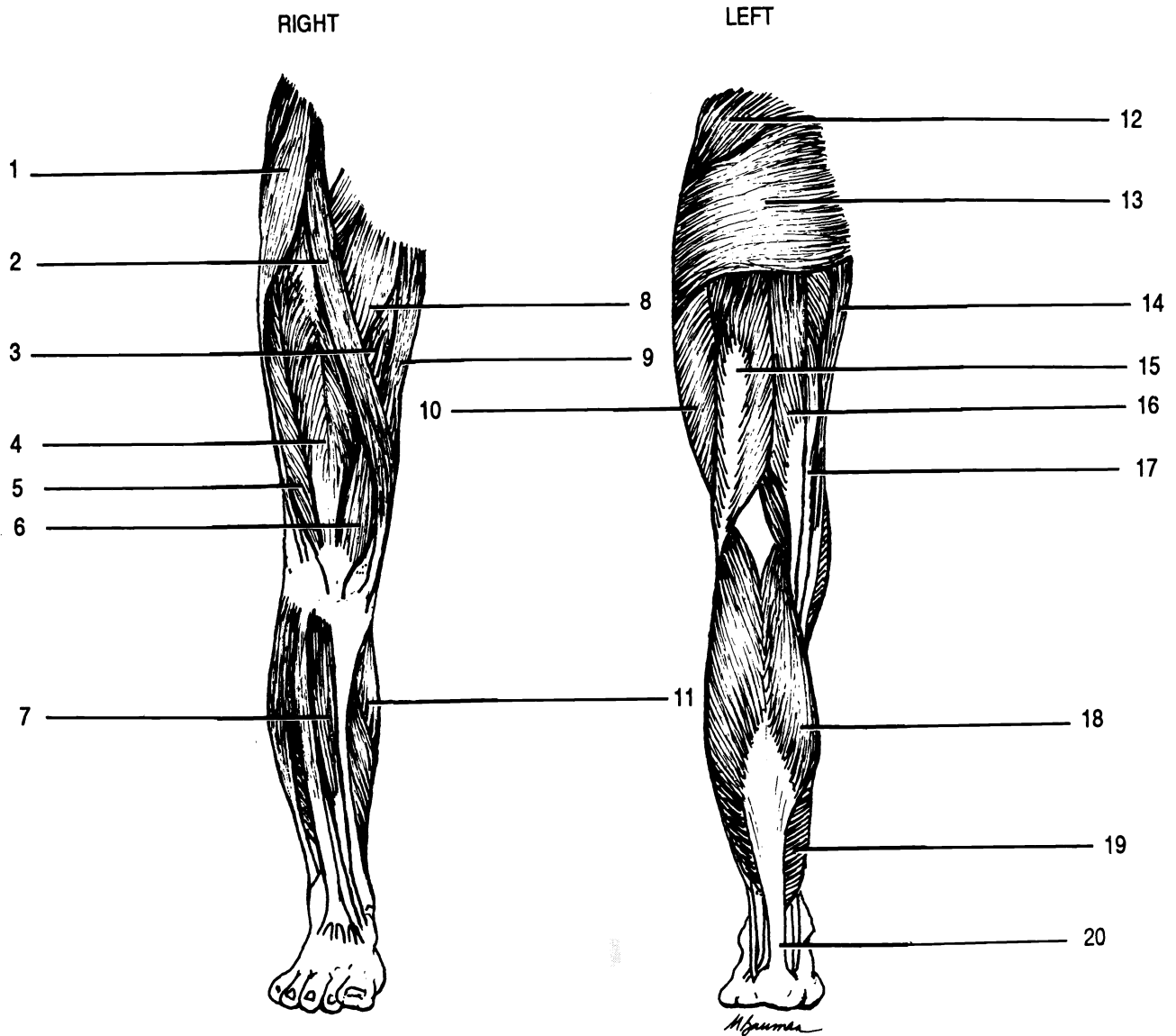
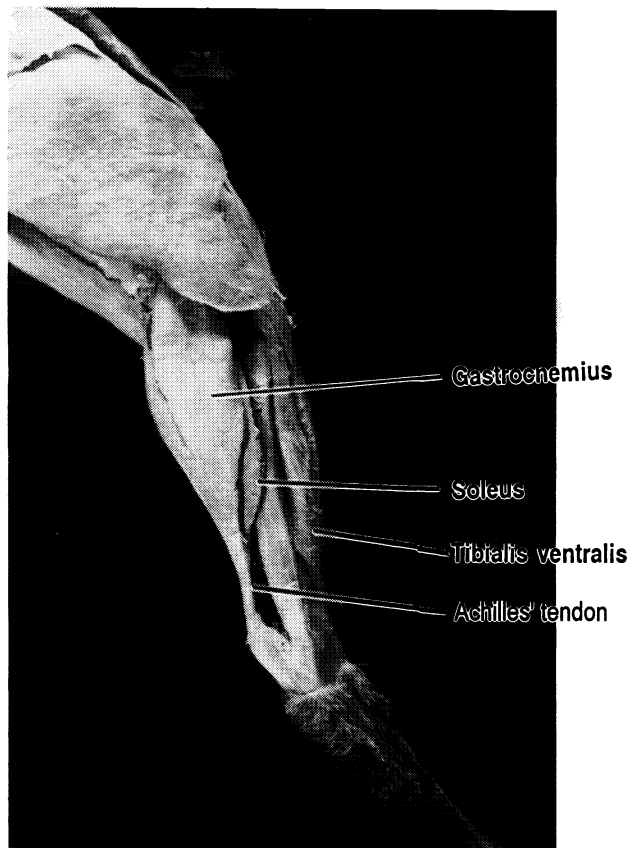
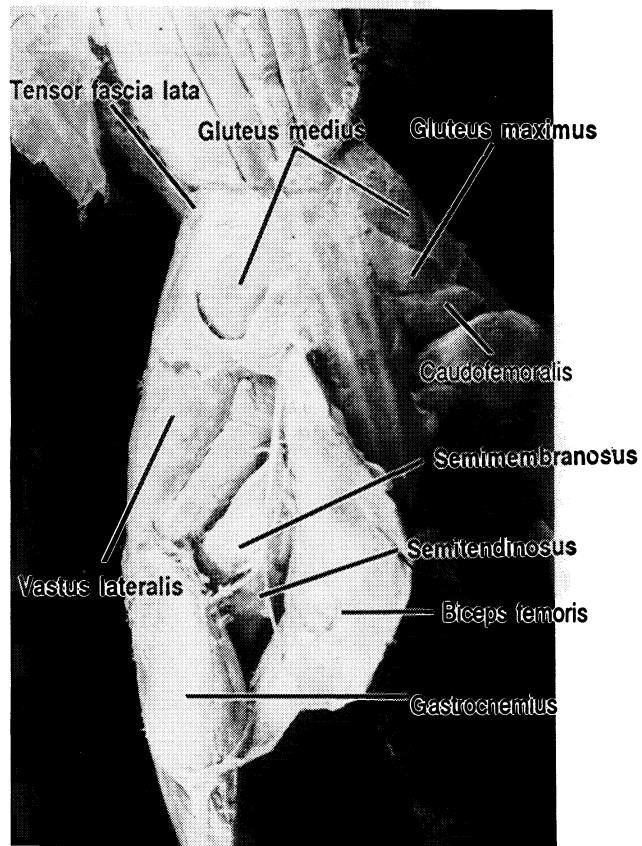
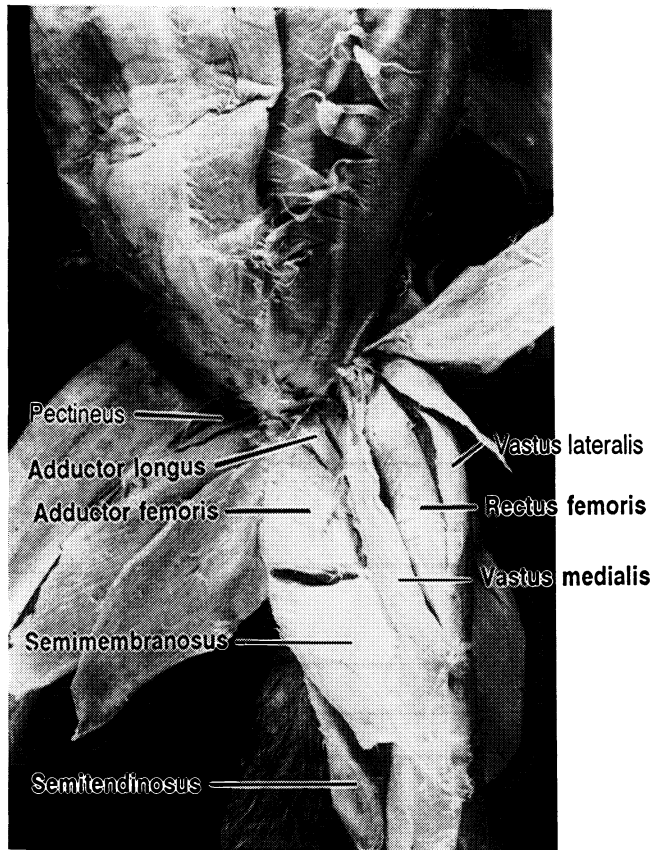
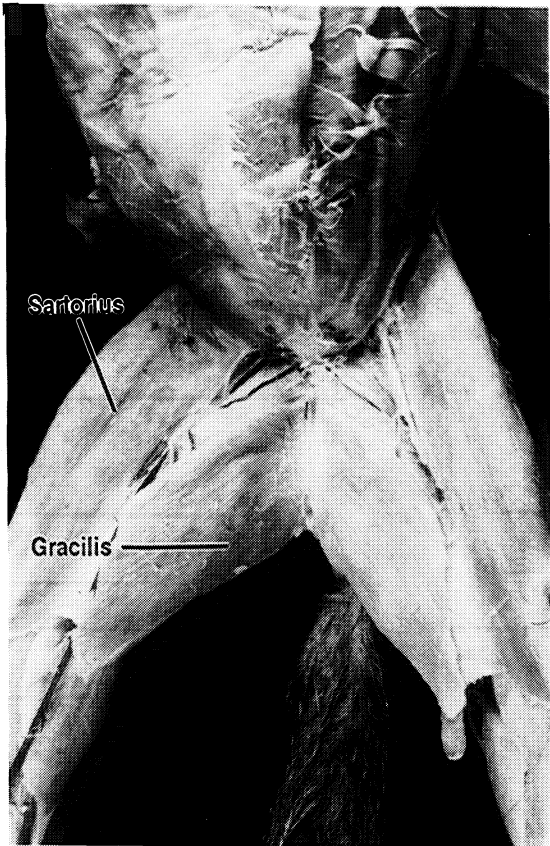


Figure 19.1 Muscles of the Leg

Achilles' tendon Adductor longus Adductor magnus Biceps femoris Gracilis (X2) Gastrocnemius (X2) Gluteus
 maximus Gluteus medius Rectus femoris Sartorius Semimembranosus Semitendinosus Soleus Tensor fascia lata
 Tibialis anterior Vastus lateralis (X2) Vastus medialis



MUSCLES OF THE CAT

TRUNK AND SHOULDER

Deltoid Group:

Acromiodeltoid

Clavodeltoid (clavobrachialis)

Spinodeltoid

External oblique

Internal oblique

Latissimus dorsi

Pectoralis major

Pectoralis minor

Rectus abdominis

Serratus ventralis

Teres major

Transverse abdominis

Trapezius Group:

Acromiotrapezius

Clavotrapezius

Spinotrapezius

Optional:

External intercostals

Infraspinatus

Internal intercostals

Pectoantebrachialis

Rhomboid

Rhomboid capitis

Supraspinatus

Subscapularis

Xiphohumeralis

NECK AND HEAD

Digastric

Masseter

Mylohyoid

Sternohyoid

Sternomastoid

Sternothyroid

Thyrohyoid

FORELEG

Biceps brachii

Brachialis

Brachioradialis

Triceps brachii

Extensor carpi radialis

Extensor carpi ulnaris

Extensor digitorum communis

Extensor digitorum lateralis

Flexor carpi radialis

Flexor carpi ulnaris

Palmaris longus

Pronator teres

MEDIAL SIDE OF LEG

Achilles's tendon (not a muscle)
Adductor femoris
Adductor longus
Gastrocnemius
Gracilis
Rectus femoris
Sartorius
Semimembranosus
Semitendinosus
Soleus
Tensor fascia lata
Tibialis ventralis
Vastus lateralis
Vastus medialis

Pectineus
Vastus intermedius

LATERAL SIDE OF LEG

Achilles' tendon (not a muscle)
Biceps femoris
Gastrocnemius
Gluteus medius
Gluteus maximus
Sartorius
Semimembranosus
Semitendinosus
Soleus
Tensor fascia lata
Vastus lateralis

Caudofemoralis

MUSCLES OF THE HUMAN OTHER THAN THOSE ON THE CAT

TRUNK AND SHOULDERS

Deltoid, (only one on the human)

Pectoralis minor is deep to pectoralis major

Rhomboid major

Rhomboid minor

(There is no rhomboid capitis on the human.)

Serratus anterior

Teres minor

Trapezius (only one on the human)

NECK AND HEAD

Buccinator

Depressor labii inferioris

Frontalis

Galea aponeurotica(not a muscle)

Lateral pterygoid

Levator labii superioris

Medial pterygoid

Occipitalis

Orbicularis oculi

Orbicularis oris

Platysma

Sternocleidomastoid

Temporalis

Triangularis (lateral third is sometimes called the zygomaticus minor)

Zygomaticus (major)

Optional:

Omohyoid

ARM

Extensor carpi radialis brevis

Extensor carpi radialis longus

Extensor digitorum communis

Extensor digiti minimi

Flexor digitorum superficialis

LEG

Adductor magnus

THE DIGESTIVE SYSTEM

The purpose of the organs of the digestive system is to take in food, break it down into small particles which can be absorbed into the blood, and eliminate waste. The core of the system is the **alimentary canal** or **gastrointestinal tract (GI tract)** which is a tube extending from the oral cavity (mouth) to the anus.

The alimentary canal is composed of the oral cavity, oropharynx, esophagus, stomach, small intestine, large intestine, and rectum. Accessory organs, including the teeth, salivary glands, pancreas, liver, and gall bladder, assist in the mechanical and chemical digestion of food.

Gross Anatomy

Exercise 20.1

Using the models and your textbook identify and label all of the organs and structures of the digestive system in Figures 20.1, 20.2, and 20.3.

The **oral cavity** has as its walls the cheeks, for its roof the anterior **hard palate** and posterior **soft palate**, and for its floor muscles of the throat and neck. Hanging from the posterior border of the soft palate is the **uvula**.

When food is taken into the oral cavity it is broken into smaller particles by the action of the teeth and tongue (mechanical digestion) and then mixed with saliva which begins the process of chemical digestion. Saliva is secreted by three pairs of salivary glands (discussed below).

The teeth from anterior to posterior on each side are **two incisors, one cuspid, two premolars (bicuspid), and three molars** (including the often extracted third molar or wisdom tooth).

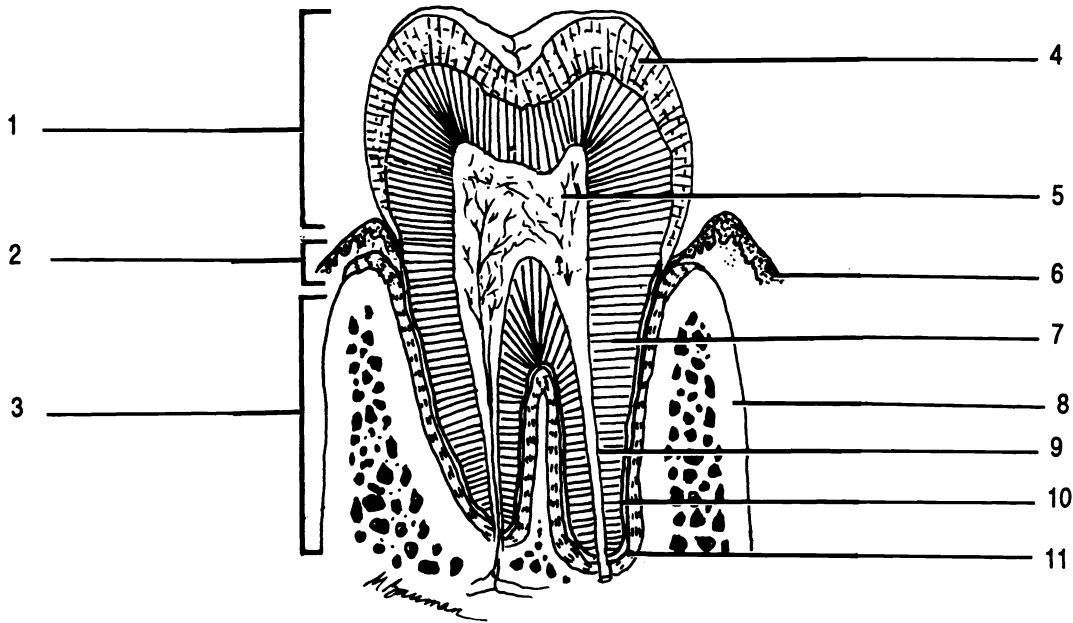


Figure 20.1 Tooth

Alveolar process Cementum Crown Dentin Enamel Gingiva Neck Periodontal ligament Pulp cavity Root
 Root canal

Each tooth is held firmly in place by the **periodontal ligaments** within the sockets formed by the alveolar processes of the jaw bones. The alveolar processes are covered with **gingivae** or gums. Each tooth typically consists of three principal portions: the **crown** is the exposed part of the tooth, the **root(s)** which extend(s) into the socket, and the **neck** which connects the crown and the root(s). The bulk of the tooth is composed of a calcified connective tissue called **dentin**. Within the dentin is a **pulp cavity** containing pulp with nerves and blood vessels. Narrow extensions of the pulp cavity extend down the root(s). These narrow extensions are the **root canals**. Dentin is held to the ligaments by **cementum**, another bone-like substance. A final very hard substance called **enamel** covers the crown.

The tongue is composed of skeletal muscle covered with mucous membrane. The superior surface of the tongue is covered with numerous **papillae** (sing. - **papilla**). These small bumps are classified into three types: **filiform**, **fungiform**, and **circumvallate**. The filiform papillae are located in parallel rows on the anterior two thirds of the tongue. They are whitish, contain no taste buds, and provide some small amount of friction for the

movement of food by the tongue. The fungiform papillae are mushroom-shaped (hence their name) and are distributed among the filiform papillae. Most of them contain taste buds. The circumvallate papillae are located in a V-shaped row on the posterior surface of the tongue. All of them contain taste buds.

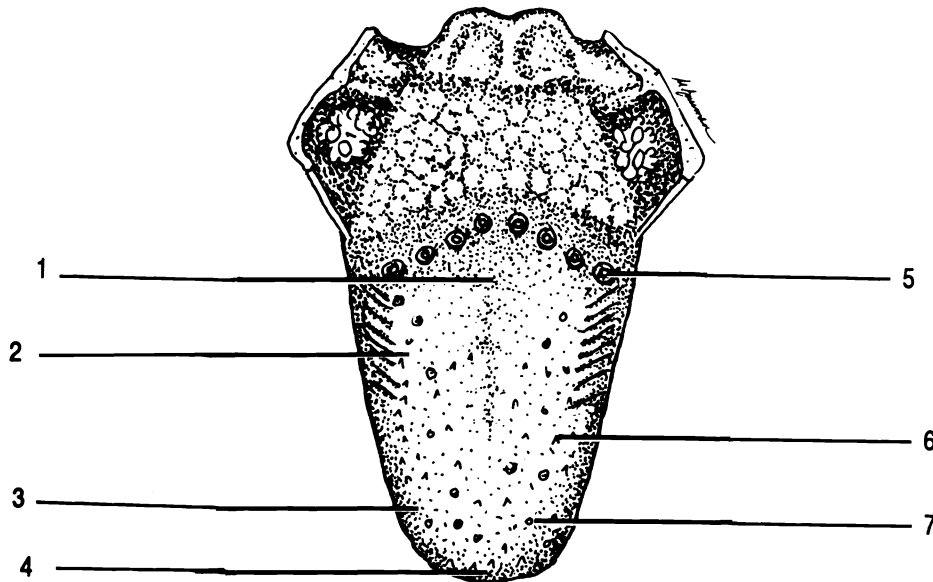


Figure 20.2 The Tongue

Bitter receptors Circumvallate papilla Filiform papilla Fungiform papilla Salt receptors Sour receptors
Sweet receptors

The **parotid salivary glands** are located in the cheeks anterior to the ears. Saliva is secreted into ducts which empty into the roof of the mouth from these glands.

The **submandibular salivary glands** are located in the floor of the mouth just inside the body of the mandible. Anterior to the submandibular glands are the **sublingual salivary glands** located underneath the tongue.

After food has been chewed and mixed with saliva it is passed into the **oropharynx** through an opening called the **fauces** by the action of the tongue and other

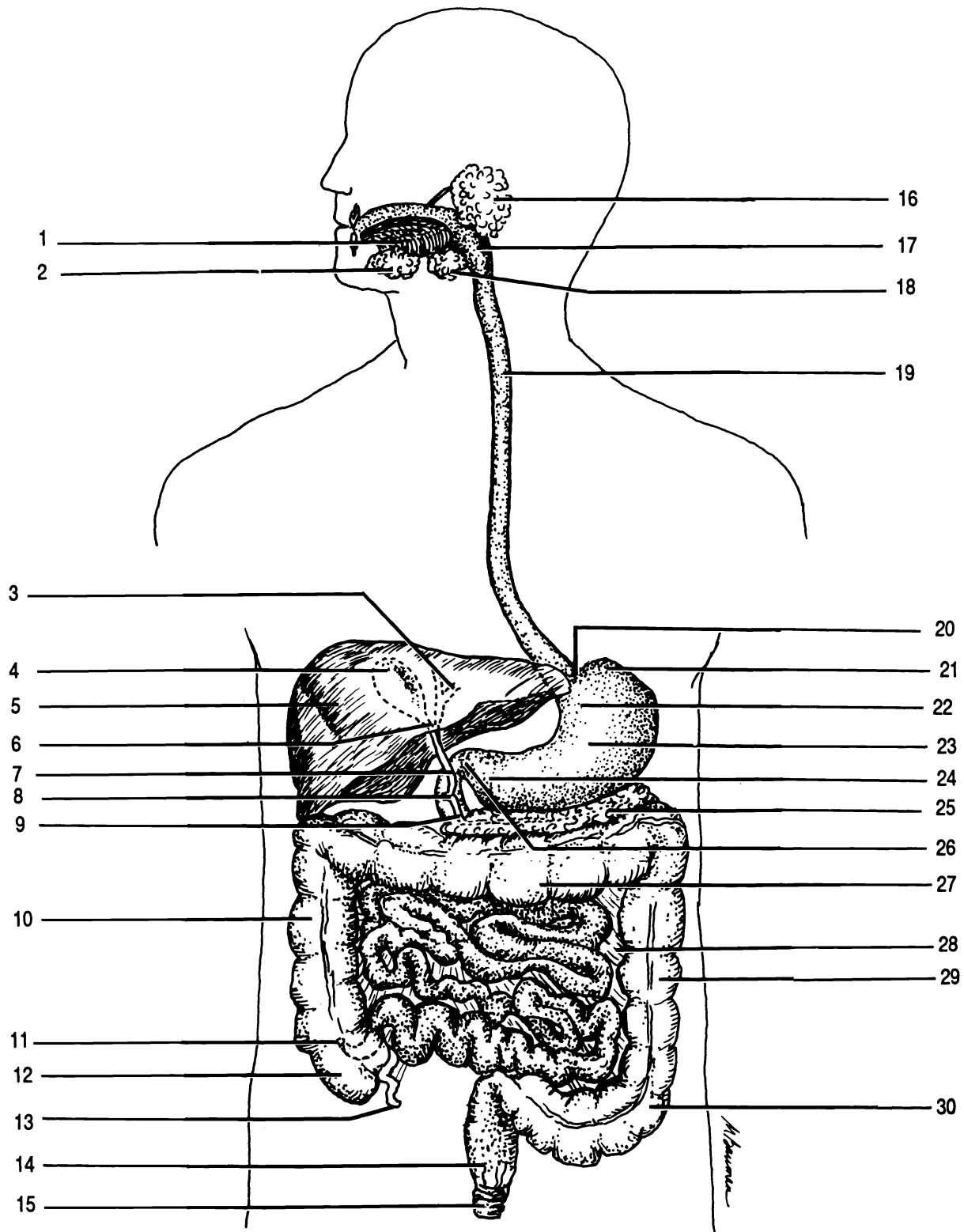


Figure 20.3 Alimentary Canal and Accessory Structures

Ampulla of Vater Anal sphincter Appendix Ascending colon Body of Stomach Cardia Cardiac sphincter Cecum
 Common bile duct Cystic duct Descending colon Esophagus Fundus Gall bladder Hepatic duct Ileocecal valve
 Liver Mesentery Oropharynx Pancreas Pancreatic duct Parotid salivary gland Pyloric sphincter Pylorus
 Rectum Sigmoid colon Sublingual salivary gland Submandibular salivary gland Tongue Transverse colon

muscles. The **pharynx** or throat is the tube joining the oral cavity, nasal cavity, esophagus, and larynx. It is divided into three regions: the nasopharynx, oropharynx, and laryngopharynx.

The **esophagus** is a tube extending from the pharynx to the stomach. Food passes through the esophagus by the action of its muscular wall.

The opening into the stomach is through the **cardiac valve**, a sphincter muscle. The stomach has four regions. The first region, where food enters from the esophagus, is the **cardia**. The upper, rounded portion to the left of the cardia is the **fundus**. The bulk of the stomach is the **body** and the inferior, narrow portion is the **pylorus**. The food passes into the small intestine through another sphincter muscle, the **pyloric valve**. The wall of the stomach has many wrinkles, termed **rugae** (pronounced roo-jee), which assist in the churning of food.

The **small intestine** is a muscular tube approximately twenty-one feet long. It is divided into three regions: the upper ten inches form the **duodenum** which joins to the stomach at the pyloric sphincter, the **jejunum** which accounts for the next eight feet of the intestine, and the final twelve feet, the **ileum**. (Note the spelling of "ileum": "ilium" is part of the os coxa; "ileum" is a portion of the small intestine.)

Liquids enter the duodenum through ducts from the **pancreas, liver, and gall bladder**. The pancreas is located posterior to the body of the stomach. It secretes digestive juices which aid in the chemical breakdown of food.

The liver is composed of two principal lobes, the **right lobe** and the **left lobe**, separated by the **falciform ligament**. Another ligament, the **round ligament**, extends from the falciform ligament to the umbilicus. The liver excretes bile, a waste product, and bile salts which aid in the digestion of lipids. Bile and bile salts are stored in the gall bladder until needed.

Most food absorbed in the digestive system passes to the liver through the **portal vein** before moving on to the rest of the body. Carbohydrates, proteins, vitamins, minerals, and other nutrients enter the liver and are either stored, processed, or sent on to the body via the **hepatic veins**.

Poisons are detoxified or stored in the liver. Other functions of the liver include the destruction of dead/dying red blood cells (a major component of bile) and the activation of vitamin D.

Bile from the liver passes through the **hepatic duct** to the gall bladder. The gall bladder is emptied by the **cystic duct** which becomes the **common bile duct** where it joins the hepatic duct. The hepatic duct joins with the **pancreatic duct** from the pancreas. The short tube connecting the common bile and pancreatic ducts to the duodenum is the **ampulla of Vater**.

The wall of the small intestine is characterized by the presence of many finger-like extensions called **villi** (**sing. - villus**). The villi greatly increase the surface area of the small intestine for absorption of food into the blood.

Each villus contains blood vessels which transport small molecules from the intestine to the liver for processing and a lymph vessel called a **lacteal**, which transports lipids into the lymphatic system (see chapter thirty).

The ileum empties into the **large intestine** or **colon** through the **ileocecal valve**, another sphincter. The large intestine has four parts, the ascending, transverse, descending, and sigmoid colons.

The **ascending colon**, the portion into which the ileum empties, ascends up the right side of the abdominal cavity to the liver. The lower end of the ascending colon is the **cecum**. Extending inferiorly from the cecum is a narrow tube the **appendix** or vermiform appendix.

The **transverse colon** crosses the body to the **descending colon** which descends down the left side of the body to the **sigmoid colon**. (The Greek letter "sigma" is "S"-shaped, like the colon).

The sigmoid colon empties waste into the **rectum** where it is stored until eliminated. Two inferior anal sphincters control the release of waste from the rectum.

The organs of the digestive system are held in place by a two-layered serous membrane, the **peritoneum**. The layer of the peritoneum which is closest to the organs of the abdominal cavity is the **visceral peritoneum**. The layer which is closest to the body wall is the **parietal**

peritoneum. As was discussed in chapter one, the peritoneum is a single membrane which is folded so as to appear to be two membranes (see Figure 1.8).

The peritoneum has several divisions. The **mesentery** contains blood vessels for, and holds the small intestine. The **mesocolon** performs the same functions for the large intestine.

Other extensions of the peritoneum form the **falciform ligament, greater omentum, and lesser omentum.** The falciform ligament attaches the liver to the anterior abdominal wall and to the diaphragm. The lesser omentum suspends the stomach and duodenum from the liver. The greater omentum drapes over and folds behind the small intestine.

Exercise 20.2

Study the model of the digestive system. Be able to identify the following structures on the model: appendix, ascending colon, cardiac sphincter, cecum, common bile duct, descending colon, duodenum, esophagus, falciform ligament, gall bladder, hard palate, hepatic artery, ileocecal valve, ileum, jejunum, liver, pancreas, pancreatic duct, pharynx, portal vein, rectum, round ligament, sigmoid colon, soft palate, spleen (not part of the digestive system), stomach (including: cardia, fundus, body, pylorus, and rugae), transverse colon, and uvula.

Study the models of teeth. Identify: alveolar process, cementum, crown, dentin, enamel, neck, pulp, pulp cavity, root, and root canal.

Identify the following on the model of the pancreas, duodenum, and gall bladder: common bile duct, cystic duct, duodenum, hepatic duct, gall bladder, pancreas, pancreatic duct, portal vein, and spleen.

Be able to identify the following on the model of the liver: common bile duct, cystic duct, falciform ligament, gall bladder, hepatic duct, left lobe, portal vein, right lobe, and round ligament.

On the model of the intestinal villus identify: lacteal, mucosa, muscularis, serosa, and submucosa (discussed later).

On the model of the lower jaw identify: alveolar process, bicuspid (premolar), body of mandible, buccinator, caries (tooth decay), cementum, crown, cuspid, dentin, enamel, gingiva, incisor, masseter, molar, neck, pulp, ramus of mandible, and root.

Exercise 20.3

Carefully open the abdominal cavity of the cat by making two transverse and one longitudinal incision in the shape of a capital "I". Reflect the muscles to examine the digestive system. Do not open the thoracic cavity.

Carefully pull the lower end of the greater omentum from behind the small intestine. Note how it forms a pouch to hold the intestine. The greater omentum is also called the fatty apron. Why? Leave the greater omentum attached to the stomach.

Identify the stomach, small intestine, three parts of the large intestine (the cat does not have a sigmoid colon), rectum, liver, falciform ligament, gall bladder, and the pancreas. (The spleen is also visible, but it is part of the lymphatic system.)

Identify the cardia, fundus, body, and pylorus of the stomach.

Cut the stomach open longitudinally. Note the rugae and the pyloric sphincter.

Expose the pancreatic duct by cutting away a portion of the pancreas. The duct lies within the pancreas.

Remove a two inch section of the jejunum. Slit it open and dispose of the contents. Examine the wall with a magnifying glass for villi.

Cut open the cecum to reveal the ileocecal valve.

Histology

The wall of the alimentary canal is composed of four layers of tissue. The **mucosa** is a mucous membrane which lines the **lumen** or hole in the canal. The **submucosa** consists of connective tissue which binds the mucosa to the third layer, the **muscularis**. In the

mouth, pharynx, and upper esophagus the muscularis is partly skeletal muscle. In the rest of the gastrointestinal tract the muscularis is composed of smooth muscle tissue. The muscularis of the stomach is composed of three layers of muscle tissue, while in the lower esophagus and intestines the muscularis has only two layers. The muscular layers of the muscularis run at angles to one another. In the intestine for instance there is an inner, circular layer and a deeper, longitudinal layer.

The deepest layer is the **serosa**, also known as the visceral peritoneum. The peritoneum has been discussed above.

Taste buds are embedded in the surfaces of fungiform and circumvallate papilla on the tongue as well as in the soft palate and throat. The taste buds contain **gustatory cells** which have chemically sensitive **gustatory hairs** on their free ends. The hairs protrude into the **gustatory pore** where they come in contact with chemicals dissolved in saliva. These cells generate nerve impulses which are sent to the brain. Between the gustatory cells are **supporting cells**.

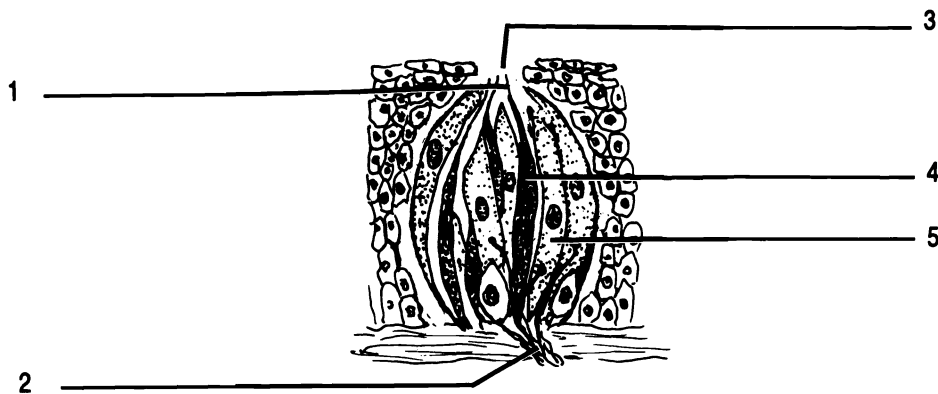


Figure 20.4 Taste Bud

Gustatory cell Gustatory hair Gustatory pore Nerve fibers Support cell

There are four types of taste buds. Each is sensitive to a different type of chemical. Taste buds for sweet are located at the apex of the tongue. Taste buds for sour are on the sides. The taste buds for salt overlap both sour and sweet. The taste buds for bitter are located on the circumvallate papillae at the back of the tongue.

A cross section through a salivary gland reveals two kinds of cells, the mucus-producing cells and the enzyme-producing cells. The mucus helps to lubricate the food for swallowing while the enzyme salivary amylase begins the chemical digestion of starches.

A photomicrograph of the wall of the stomach shows narrow pits in the mucosa. These pits are known as gastric pits and are lined with mucus-producing cells. Deeper within the mucosa are two other secretory cells. The **parietal cells** secrete hydrochloric acid. The **zymogenic cells** secrete an enzyme involved in the digestion of protein. The enzyme is pepsinogen. The muscularis of the stomach has three layers rather than the usual two layers.

The wall of the small intestine has villi. The surface of the villus is composed of a single layer of columnar epithelial cells. Small glands deep to the villi secrete digestive juices into the intestine. Each columnar cell has microscopic folds of its cell membrane called **microvilli**. The microvilli further increase the surface area of the intestine allowing for greater absorption of nutrients.

The liver is composed of small functional units called **lobules**. Each lobule contains numerous canals which channel blood between the cells of the lobule into a central vein.

Exercise 20.4

Examine microscopic slides of: taste bud, salivary gland, stomach, small intestine, and liver. Note the following structures:

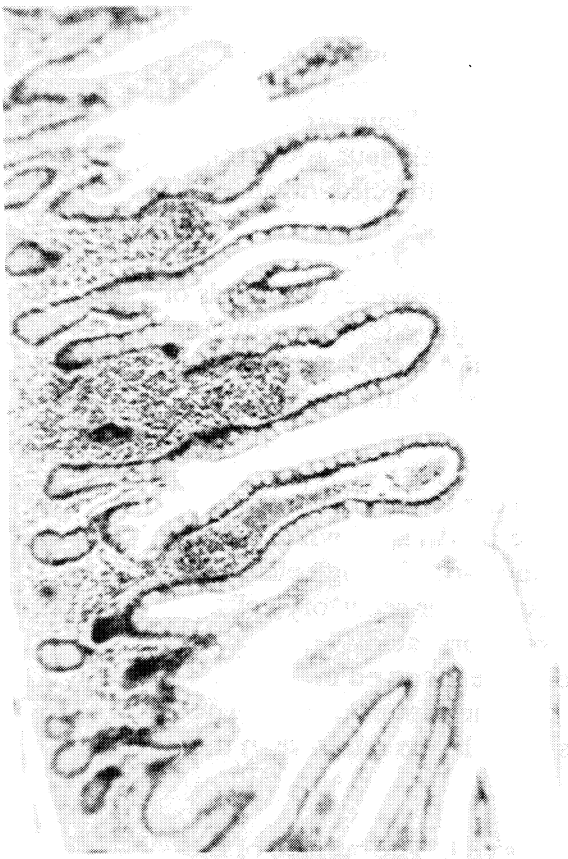
taste bud - gustatory cell, gustatory hair, gustatory pore, and supporting cell

salivary gland - two types of cells

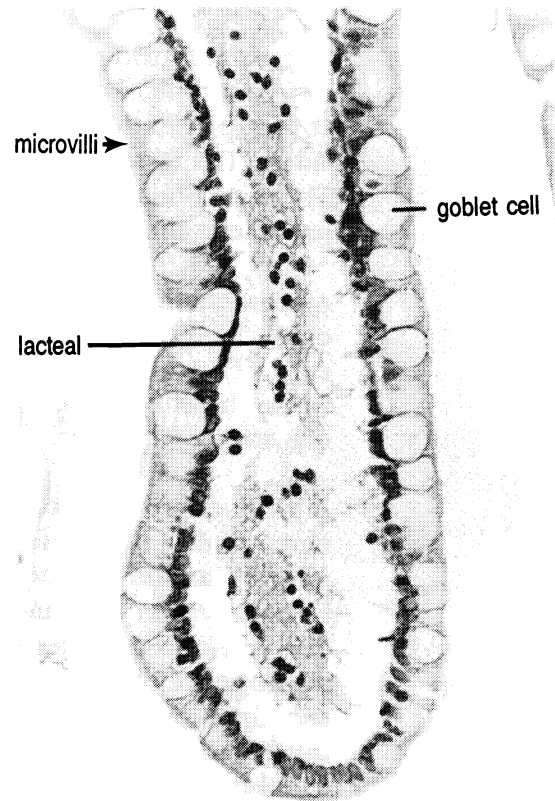
stomach - gastric pit, parietal cell, and zymogenic cell

small intestine - microvilli, simple columnar epithelium, and villus


liver - central vein



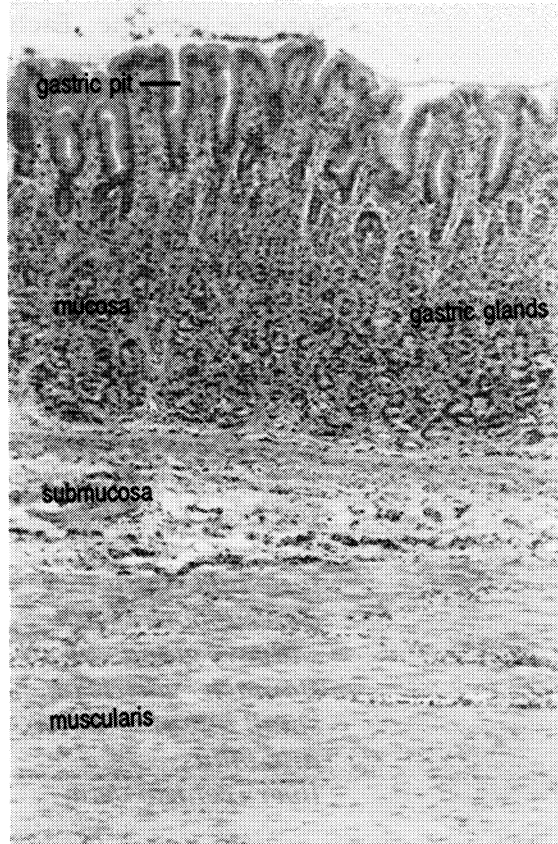
Villi



Villus



Colon



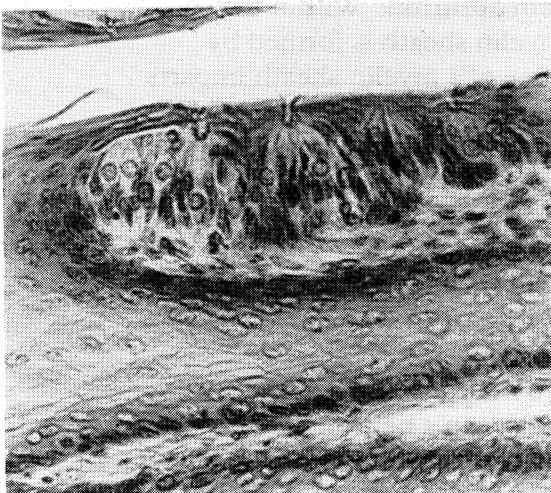
Stomach

CHAPTER 20 REVIEW

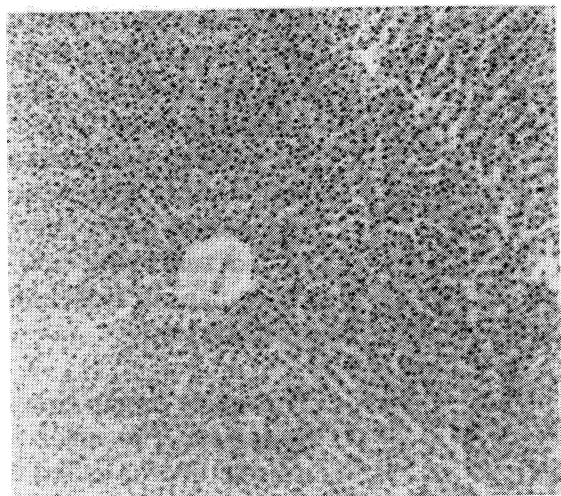
1. _____ The teeth are held in the socket by cementum and (1).
2. _____ The papillae at the back of the tongue are (2) papillae.
3. _____ The bones which make up the hard palate are the two palatine and two (3).
4. _____ Name the salivary glands in order from posterior to anterior.
5. _____
6. _____
7. _____ Which part of the peritoneum holds the liver to the diaphragm?
8. _____ The folds inside the stomach are the (8).
9. _____ Name the three divisions of the small intestine in order.
10. _____
11. _____
12. _____ The layer of the GI tract which is located between the muscularis and the mucosa is the (12).
13. _____ What is the function of the greater omentum?
14. _____ The inferior end of the ascending colon is the (14).
15. _____ Which duct empties the gall bladder?

Name the structures:

Name the tissue:



16. _____



17. _____

CHAPTER 21
NERVOUS TISSUE

NEURONS

The **neuron** serves as the basic anatomical and physiological unit of the nervous system. It consists of the **perikaryon** or cell body and contains such structures as the **nucleus**, **Nissl bodies**, **neurofibrils**, lysosomes, mitochondria, and Golgi apparatus. A mature neuron does not contain a mitotic apparatus. The Nissl bodies are masses of rough endoplasmic reticula and are involved in protein synthesis. The neurofibrils are hollow microtubules that are involved in nerve impulse conduction, support for the cell, and transportation of nutrients.

The perikaryon has two types of cytoplasmic extensions: dendrites and axons. The **dendrite** transmits a nerve impulse toward the perikaryon. It may have its distal end modified as a **receptor** and may be highly branched. The **axon** transmits an impulse away from the perikaryon. The axon may have side branches that are called **axon collaterals**.

The neuron may have associated with it specialized cells called **Schwann cells**. Within the peripheral nervous system, the Schwann cell is responsible for the formation of the **myelin sheath** and **neurolemma**. Within the central nervous system, the myelin sheath is formed by oligodendrocytes. The presence of a myelin sheath imparts a whitish color, hence the term white matter, insulates the neuron, and increases the speed of nerve impulse conduction. The neurolemma is necessary for the regeneration of a nerve fiber. Since the Schwann cell is an actual living cell, it has a **nucleus**. Breaks or gaps at regular intervals in the myelin sheath are called **nodes of Ranvier**.

The space or gap between two neurons is called the **synapse**. The space or gap between a neuron and a muscle fiber is called the **neuromuscular junction** (Figure 13.4).

TYPES OF NEURONS

Neurons may be classified structurally based on the number of processes extending from the perikaryon or they may be classified functionally based on the direction the nerve impulse is carried.

The three types of structural neurons are: **multipolar neurons**, **bipolar neurons**, and **unipolar neurons**. Multipolar neurons have many dendrites and one main axon. Bipolar neurons will have only one axon and only one dendrite. Unipolar neurons consist of a cell body and one process which is usually referred to as an axon, though the portion carrying impulses toward the perikaryon is sometimes called a dendrite.

The three types of functional neurons are: **sensory (afferent) neurons**, **motor (efferent) neurons**, and **connector (association) neurons**. Sensory neurons conduct an impulse toward the spinal cord or brain. Motor neurons conduct an impulse away from the spinal cord or brain to effectors (muscles and glands). Connector neurons are found only within the central nervous system and serve to connect sensory and motor neurons and one another.

Exercise 21.1

Figure 21.1 shows three different types of neurons. Using your textbook as a guide, fill in the labels on the figure from the list of words given.

Exercise 21.2

Study the model of the motor neuron. Identify the following structures on the model: axon, dendrites, mitochondria, myelin sheath, neurofibrils, neurolemma, Nissl bodies, nodes of Ranvier, nucleus of the perikaryon, nucleus of the Schwann cell, perikaryon, and Schwann cell.

HISTOLOGICAL STUDY OF NERVE TISSUE

Exercise 21.3

Examine and sketch a smear of an ox spinal cord as seen with a microscope: Identify the following: axon, dendrite, and perikaryon.

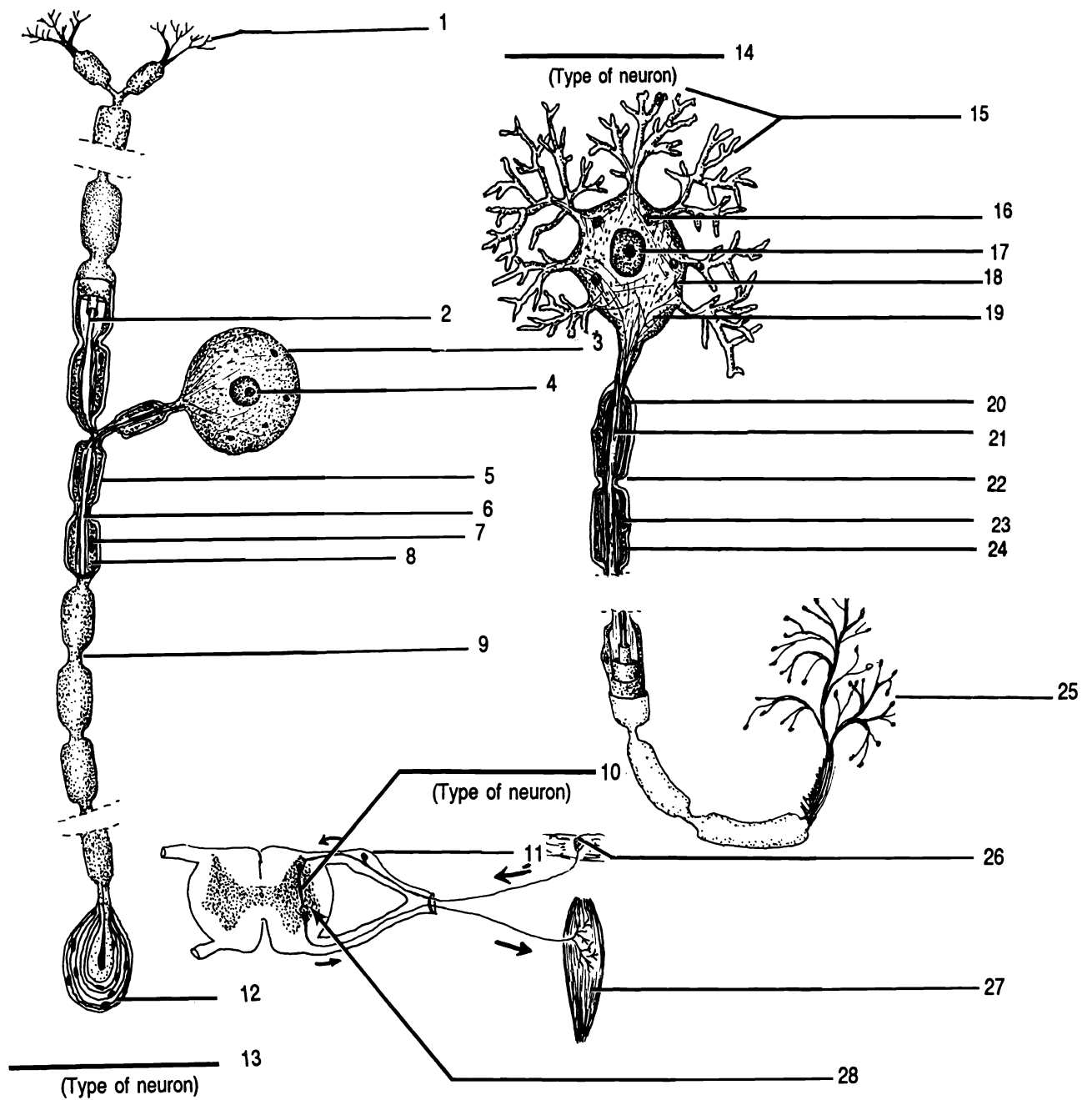
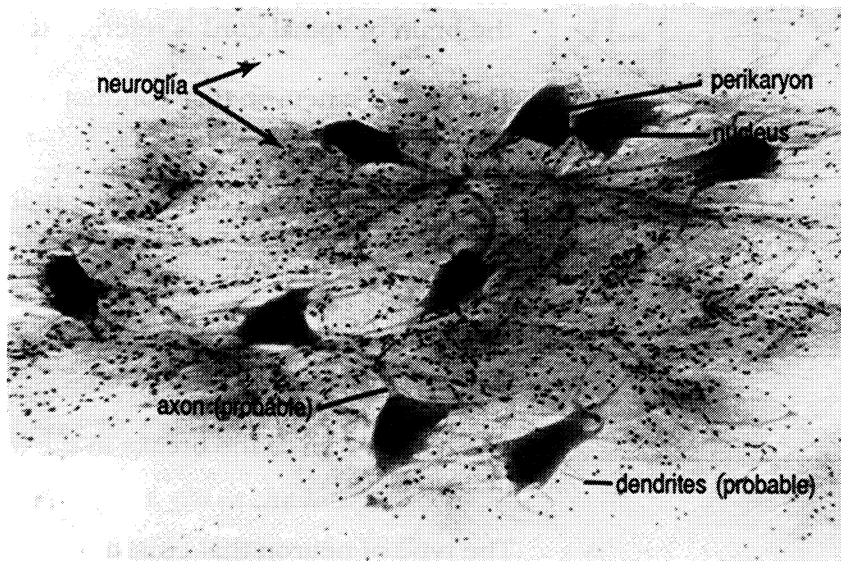


Figure 21.1 Sensory and Motor Neurons

Axon (X2) Axon terminal branch (X2) Connector neuron Dendrite (X2) Motor neuron Muscle fiber
 Myelin sheath (X2) Neurofibril Neurolemma (X2) Nissl body Node of Ranvier (X2) Nucleus of Schwann cell (X2)
 Nucleus of the perikaryon (X2) Perikaryon (X2) Receptor (X2) Sensory neuron Spinal ganglion (dorsal root ganglion)
 Synapse



Neurons

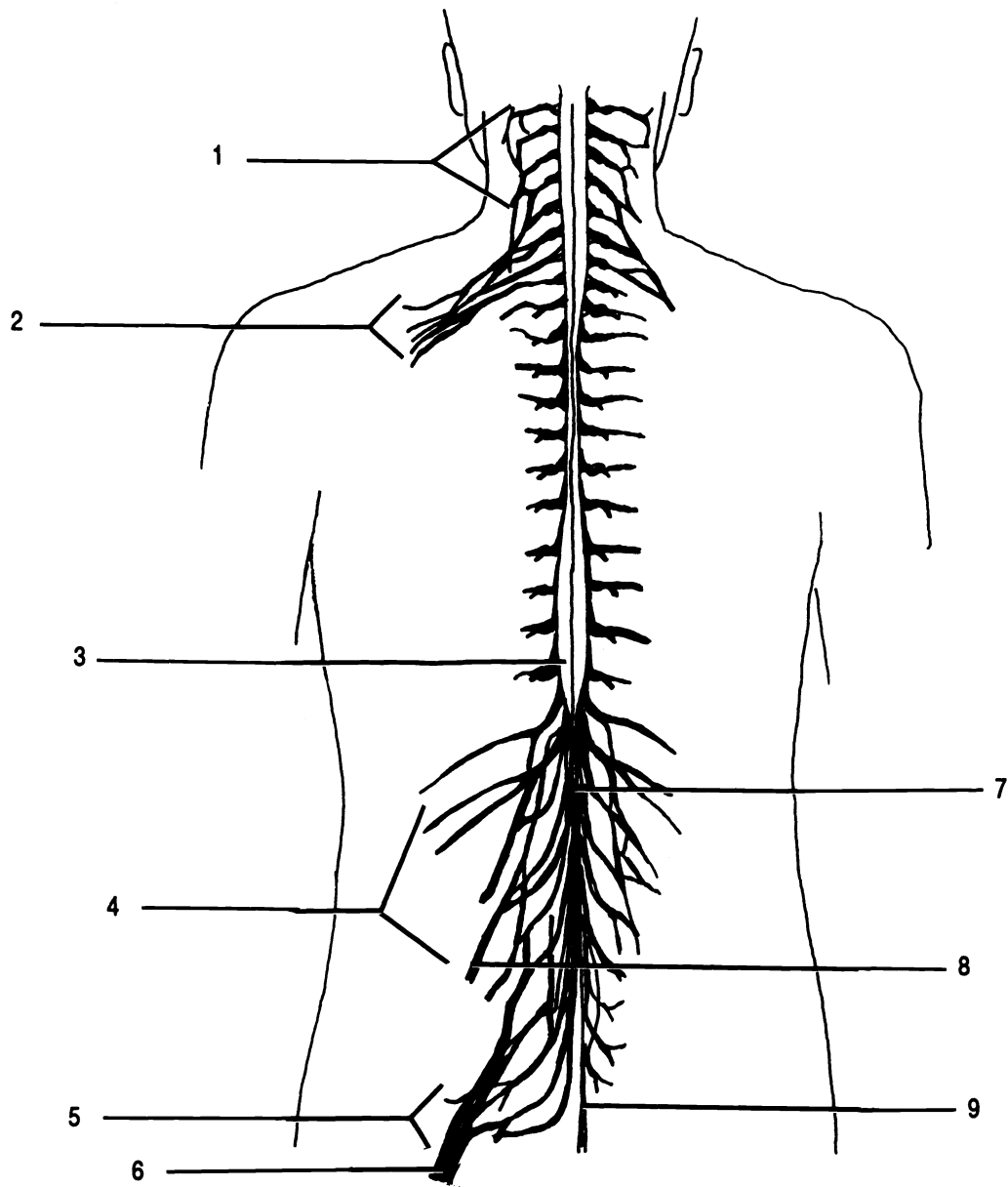


Figure 22.1 Posterior View of the Spinal Cord

Brachial plexus Cauda equina Cervical plexus Conus medullaris Femoral nerve Filum terminale Lumbar plexus
 Sacral plexus Sciatic nerve

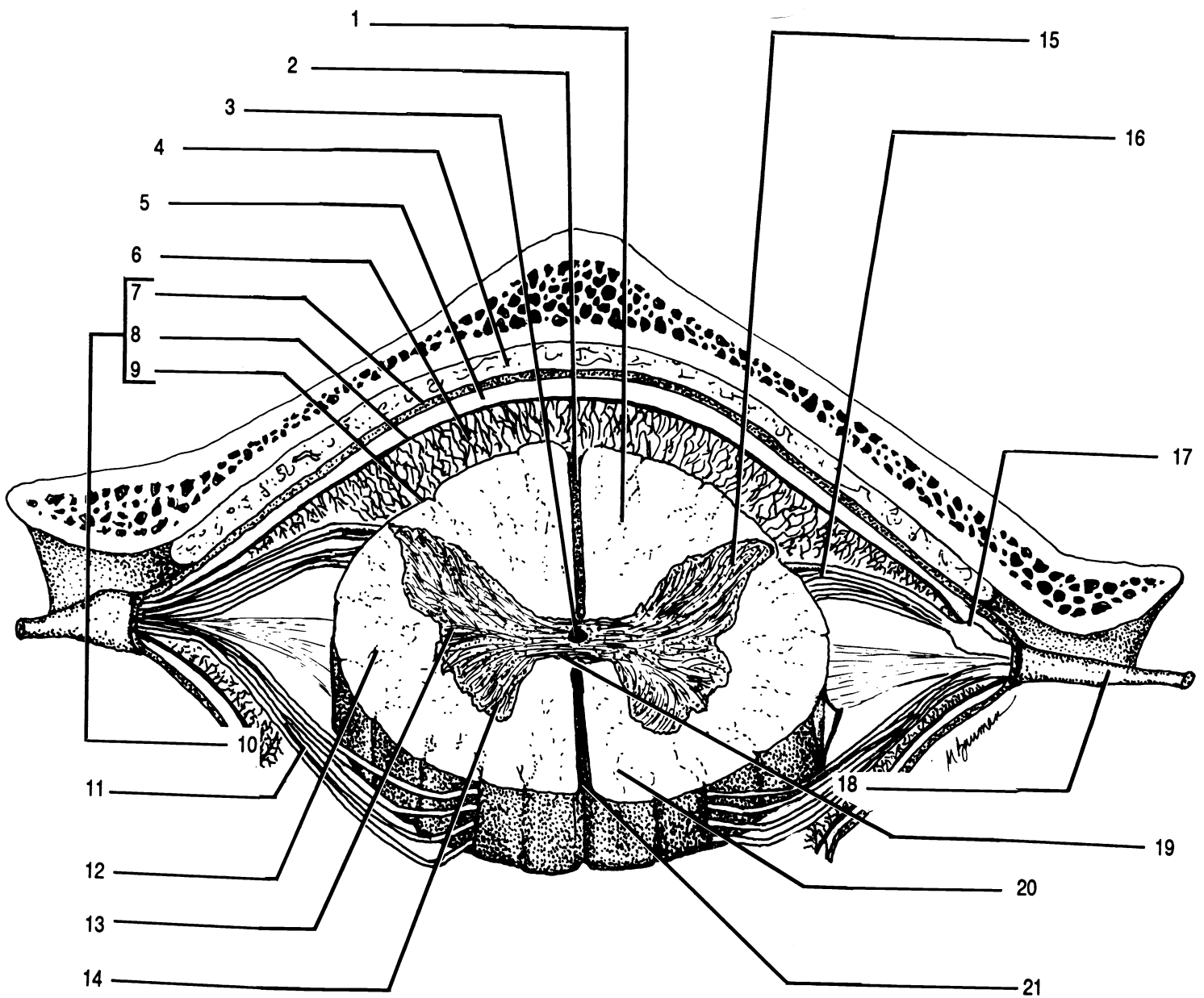


Figure 22.2 Cross Section of the Spinal Cord

Anterior column of the white matter Anterior horn of the gray matter Anterior median fissure Anterior root
 Arachnoid mater Central canal Dura mater Epidural space Gray commissure Lateral column of the white matter
 Lateral horn of the gray matter Meninges Pia mater Posterior column of the white matter Posterior horn of the gray
 matter Posterior median sulcus Posterior root Spinal ganglion (dorsal root ganglion) Spinal nerve
 Subarachnoid space Subdural space

Babinski sign. To perform this reflex test, using the metal end of the hammer, lightly stimulate the outer margin of the sole of the foot. The big toe will extend and there may or may not be fanning of the other toes. This will occur normally in children under 1 1/2 years of age. The normal response after 1 1/2 years of age is the plantar reflex (negative Babinski) which results in a curling under of the all the toes, which may be accompanied by a slight turning in and flexion of the anterior part of the foot.

Biceps Reflex. To perform this reflex test, press your thumb over your lab partner's biceps brachii tendon. Strike your thumb just proximal to your thumb nail. This reflex causes flexion of the arm.

Triceps Reflex. To perform this reflex test, have your lab partner flex his/her arm at the elbow and then hold his/her flexed arm with their opposite arm across his/her abdomen. Strike the triceps brachii tendon just above the elbow with the pointed end of the hammer. This reflex results in extension of the arm.

Exercise 22.4

Study the model of the arm. Identify the following nerves on the model: axillary nerve, median nerve, musculocutaneous nerve, radial nerve, and ulnar nerve.

Study the model of the leg. Identify the following nerves on the model: common peroneal nerve, femoral nerve, and sciatic nerve.

Study the model of the cross section of the spinal cord. Identify the following structures on the model: anterior root, anterior column of the white matter, anterior horn of the gray matter, anterior median fissure, arachnoid mater, central canal, dura mater, lateral column of the white matter, lateral horn of the gray matter, meninges, pia mater, posterior column of the white matter, posterior horn of the gray matter, posterior median sulcus, posterior root, spinal nerve, spinal ganglion (dorsal root ganglion), subarachnoid space, and subdural space.

HISTOLOGICAL STUDY OF SPINAL CORD

Exercise 22.5

Examine and sketch the cross section of the spinal cord as seen with a microscope. Use low power. Identify the following: central canal, gray commissure, gray matter, spinal ganglion, and white matter.

CHAPTER 22 REVIEW

1. _____ The covering of the brain and spinal cord that is vascularized is the (1).
2. _____ Name the three meninges.
3. _____
4. _____
5. _____ Name the two grooves that almost divide the spinal cord into two equal parts.
6. _____
7. _____ The root of the spinal cord that conducts motor information is called the (7).
8. _____ Where specifically within the vertebral column does the spinal cord cease to be a solid structure?
9. _____ From what plexus does the sciatic nerve arise?
10. _____ The reflex action that causes the leg to extend is achieved by hitting the (10).
11. _____ The thin, web like layer of the meninges is known as the (11).
12. _____ What is the name of the fluid that can be found within the subarachnoid space?
13. _____ Give the location of the cervical plexus.
14. _____ Name the nerves that originate from the brachial plexus.
15. _____
16. _____
17. _____
18. _____
19. _____ Is a negative Babinski a normal reaction for an adult?
20. _____ The enlargement on the posterior root of the spinal cord that contains sensory neuron cell bodies is known as the (20).
21. From your observation of drawings and models, which horn of the gray matter is the widest? Why is it larger than the others?

CHAPTER 23

THE BRAIN AND CRANIAL NERVES

The brain is divided into four major areas: the cerebrum, the cerebellum, the brain stem, and the diencephalon. The brain stem consists of the midbrain, pons varolii, and medulla oblongata. The midbrain is further divided into the cerebral peduncle, corpora quadrigemina, and aqueduct of Sylvius (cerebral aqueduct). The diencephalon region includes the thalamus, hypothalamus, intermediate mass, third ventricle, and fornix.

The brain is covered by the same three meninges as the spinal cord: the dura mater, arachnoid mater, and pia mater.

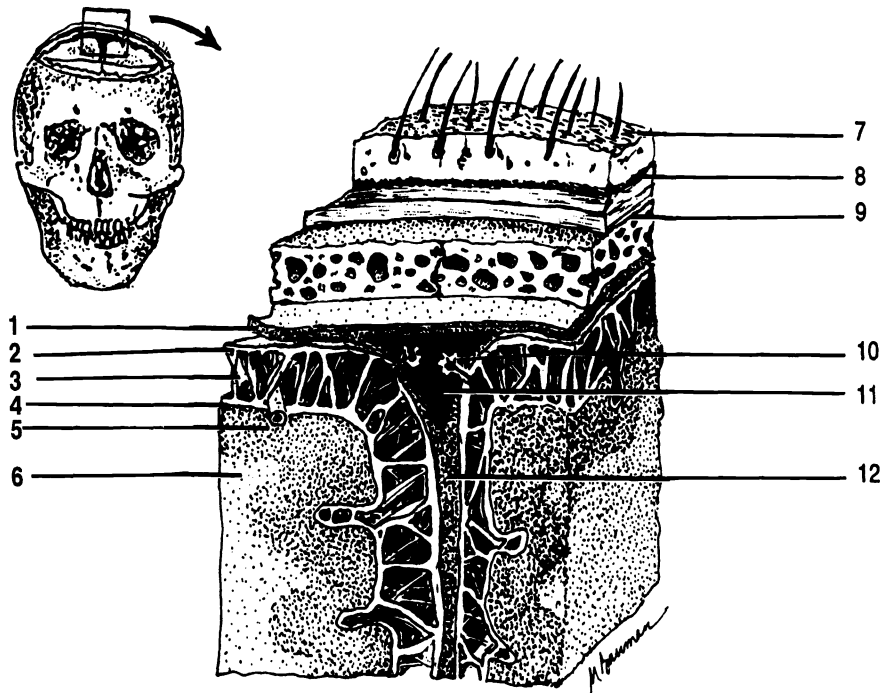


Figure 23.1 Partial Frontal Section of Brain Showing Meninges

Arachnoid granulation Arachnoid mater Bone Dura mater Falx cerebri Gray matter Periosteum Pia mater
Sagittal sinus Scalp Subarachnoid space White matter

The **cerebrum** is the largest part of the brain. The **cerebral cortex** is the outer layer of the cerebrum and is made up of gray matter. Internally the cerebrum is white matter. The cerebrum is divided into two **cerebral hemispheres** which are connected by a bridge of white matter called the **corpus callosum**. Each cerebral hemisphere has convolutions or raised folds on its surface that are referred to as **gyri** (sing. - gyrus). Separating the gyri are deep grooves called **fissures** and shallow grooves called **sulci** (sing. - sulcus). The most pronounced fissure is the **longitudinal fissure**, which almost separates the two cerebral hemispheres. Between the two cerebral hemispheres is an extension of the dura mater called the **falx cerebri**. Each cerebral hemisphere is divided into five lobes. They are the: **frontal lobe, parietal lobe, temporal lobe, occipital lobe, and insula** (island of Reil). The insula is a deep lobe and cannot be seen in an external view of the brain. It can be seen by separating the frontal lobe, parietal lobe, and temporal lobe.

The **cerebellum** is the second largest part of the brain and is inferior and posterior to the cerebrum. Externally it is gray matter and internally it is composed of white matter that is referred to as the **arbor vitae** (so named because it resembles the branches of a tree).

The **midbrain** is located inferior to the cerebrum and anterior to the cerebellum. The **cerebral peduncles** consist of a pair of cylindrical bodies that serve to connect the upper parts of the brain with lower parts of the brain and spinal cord. The **corpora quadrigemina** consists of four rounded lobes. The upper two are known as the superior colliculi and the lower two are known as the inferior colliculi. The aqueduct of Sylvius is a passageway that serves to connect the third ventricle and the fourth ventricle. The ventricles are discussed below. Located superiorly and slightly posterior to the corpora quadrigemina is the **pineal gland**.

The **pons varolii** or **pons** is located inferior to the midbrain and anterior to the cerebellum. It consists primarily of white matter. It serves to connect the spinal cord, cerebrum, and cerebellum.

The **medulla oblongata** or **medulla** is located inferior to the pons and superior to the foramen magnum. The medulla contains tracts (myelinated nerve fibers located within the central nervous system) that communicate between the spinal cord and various parts of the brain.

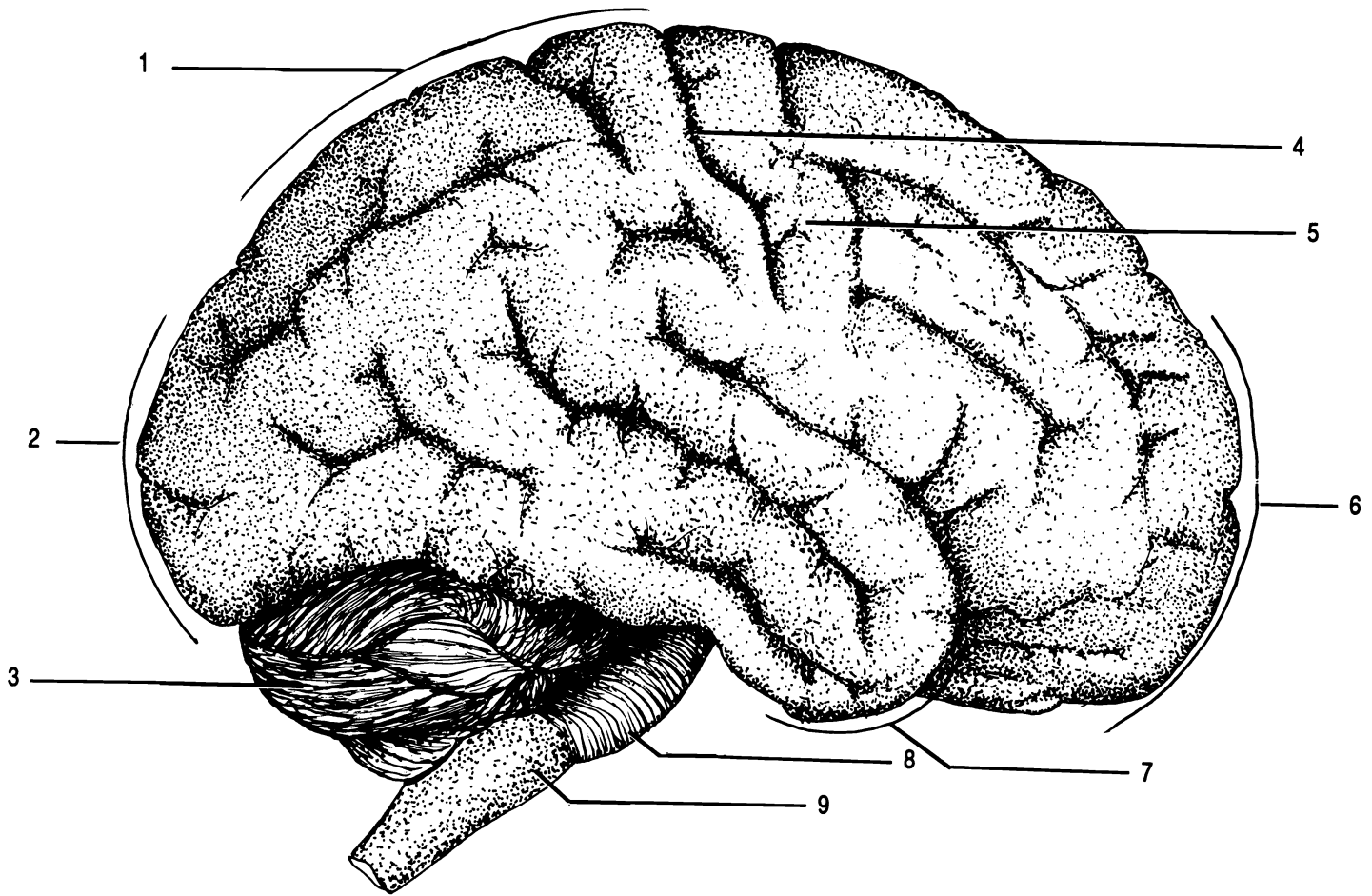


Figure 23.2 Lateral External View of the Brain

Cerebellum Frontal lobe Gyrus Medulla Occipital lobe Parietal lobe Pons Sulcus Temporal lobe

The **thalamus** consists of two oval shaped structures located superior to the midbrain. It is primarily gray matter and it forms the lateral walls of the third ventricle. The two masses are connected by a bridge of gray matter known as the **intermediate mass**. The intermediate mass passes through the third ventricle.

The **hypothalamus** is located anterior and inferior to the thalamus. The hypothalamus forms the inferior floor and part of the lateral walls of the third ventricle. Anterior to the hypothalamus is the **optic chiasma**. In the optic

chiasma, the medial halves of the optic nerves cross over and go to the opposite side of the brain. The lateral halves of the optic nerve do not cross over. The hypothalamus connects to the **pituitary gland (hypophysis)** by way of the **infundibulum**. The pituitary gland is located in the sella turcica of the sphenoid bone. Located inferior and posteriorly to the hypothalamus are the **mammillary bodies**. The two mammillary bodies are small and rounded.

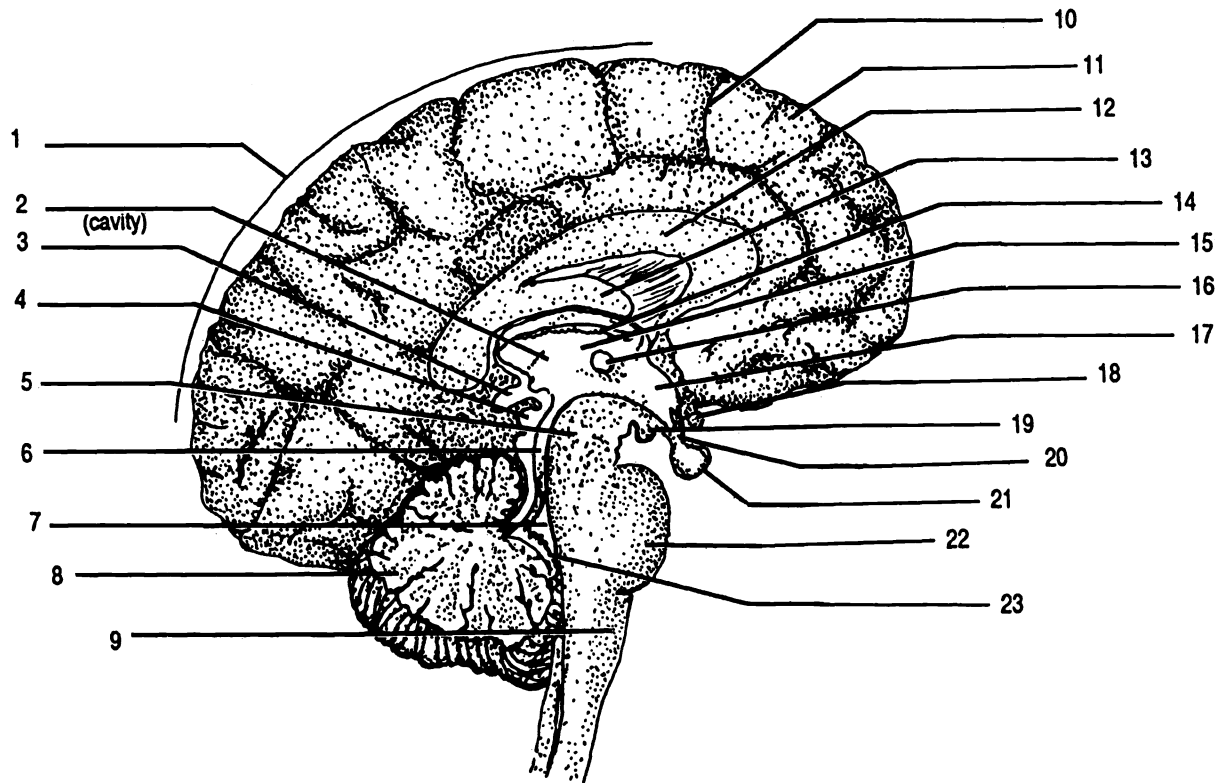


Figure 23.3 Midsagittal Section of the Brain

Aqueduct of Sylvius Cerebellum Cerebral peduncle Cerebrum Choroid plexus of the fourth ventricle
 Choroid plexus of the third ventricle Corpora quadrigemina Corpus callosum Fornix Fourth ventricle Gyrus
 Hypothalamus Infundibulum Intermediate mass Mammillary body Medulla Optic chiasma Pineal gland
 Pituitary gland Pons Sulci Thalamus Third ventricle

THE CRANIAL NERVES

There are twelve pairs of cranial nerves that originate from the brain. The cranial nerves are given a number which indicates the order in which they arise from the brain (cranial nerve I is anterior most and cranial nerve XII is posterior most). Each cranial nerve is also given a

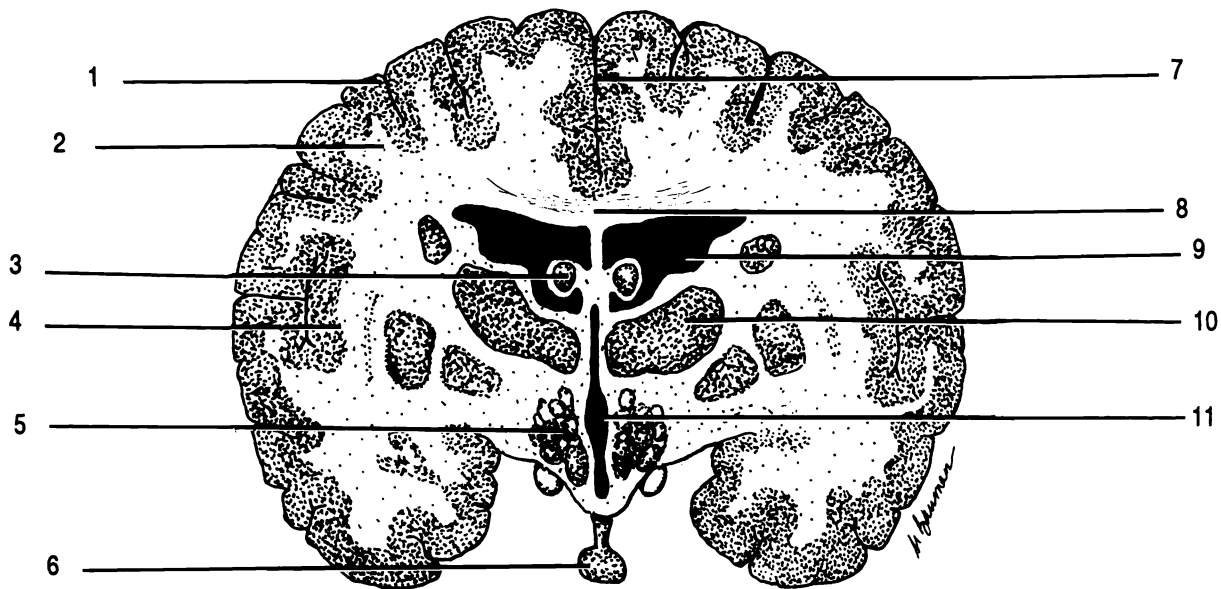


Figure 23.4 Frontal Section of the Brain

Corpus callosum Fornix Gray matter Hypothalamus Insula Lateral ventricle Longitudinal cerebral fissure
 Pituitary gland Thalamus Third ventricle White matter

name which indicates its function or distribution within the body. Ten of the twelve pairs originate from the brain stem. Cranial nerves that originate from the medulla are the: **vestibulocochlear VIII (cochlear branch)**, **glossopharyngeal IX**, **vagus X**, **spinal accessory XI**, and **hypoglossal XII**. Cranial nerves that originate from the pons are the: **trigeminal V**, **abducens VI**, **facial VII**, and **vestibulocochlear VIII (vestibular branch)**. Cranial nerves that originate from the midbrain are the: **oculomotor III** and **trochlear IV**. The remaining two cranial nerves are the: **olfactory I** (which arises in the olfactory mucosa of the nose) and the **optic II** (which arises in the retina of the eye). Olfactory nerve I has two structures which make it up; these are the **olfactory bulb** and the **olfactory tract**.

Optic nerve II passes to the optic chiasma and from here the neurons pass through the **optic tracts** on there way to the lateral geniculate nucleus in the thalamus.

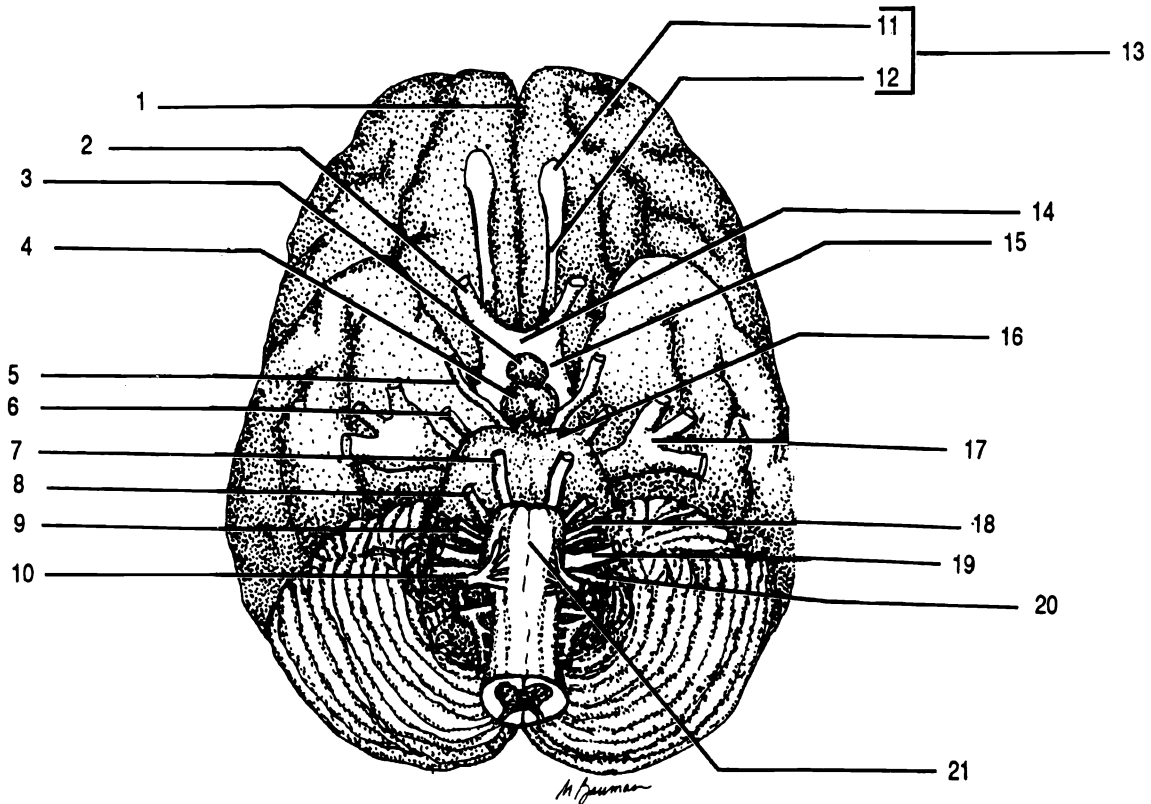


Figure 23.5 Inferior External View of the Brain

Abducens nerve VI Accessory nerve XI (spinal accessory) Facial nerve VII Glossopharyngeal nerve IX
 Hypoglossal nerve XII Longitudinal fissure Mammillary body Medulla Oculomotor nerve III Olfactory bulb
 Olfactory nerve I Olfactory tract Optic chiasma Optic nerve II Optic tract Pituitary gland Pons Trigeminal nerve V
 Trochlear nerve IV Vagus nerve X Vestibulocochlear nerve VIII

THE VENTRICLES OF THE BRAIN AND CEREBRO-SPINAL FLUID

The brain has four cavities called ventricles. The first and second ventricles are referred to as the **lateral ventricles** and are located in the cerebral hemispheres. A midline structure, the **septum pellucidum**, which is a thin membrane, separates the two lateral ventricles. The lateral ventricles communicate with the **third ventricle** by way of a small oval opening called the **foramen of Monro**. The third ventricle communicates with the fourth ventricle by way of the **aqueduct of Sylvius**. The fourth ventricle is a cavity that lies between the inferior aspects of the brain stem and the cerebellum. The fourth ventricle has three openings: a median opening, the **foramen of Magendie**, and two lateral openings, the **foramina of Luschka**. These three foramina open into the subarachnoid space.

Cerebrospinal fluid originates from a **choroid plexus** located in the roof of each ventricle. The choroid plexus is a highly vascularized network of capillaries and nonconducting nerve cells. Cerebrospinal fluid is formed by filtration and secretion from each choroid plexus. Cerebrospinal fluid formed in the lateral ventricles flows into the third ventricle by way of the foramen of Monro and joins the fluid from the third ventricle. The fluid then moves down the aqueduct of Sylvius into the fourth ventricle joining the fluid from the fourth ventricle. The fluid then circulates into the subarachnoid space. The cerebrospinal fluid flows down the posterior aspect of the spinal cord, up the anterior surface of the spinal cord, and around the anterior surface of the brain. Most of the cerebrospinal fluid is absorbed into the **sagittal sinus** (a blood vascular cavity just under the sagittal suture of the cranium) through finger like projections of the arachnoid mater called **arachnoid granulations** (arachnoid villi). Cerebrospinal fluid is normally produced at the same rate that it is absorbed into the sagittal sinus.

Exercise 23.1

Using your text as a guide, fill in the labels on Figures 23.1 - 23.6.

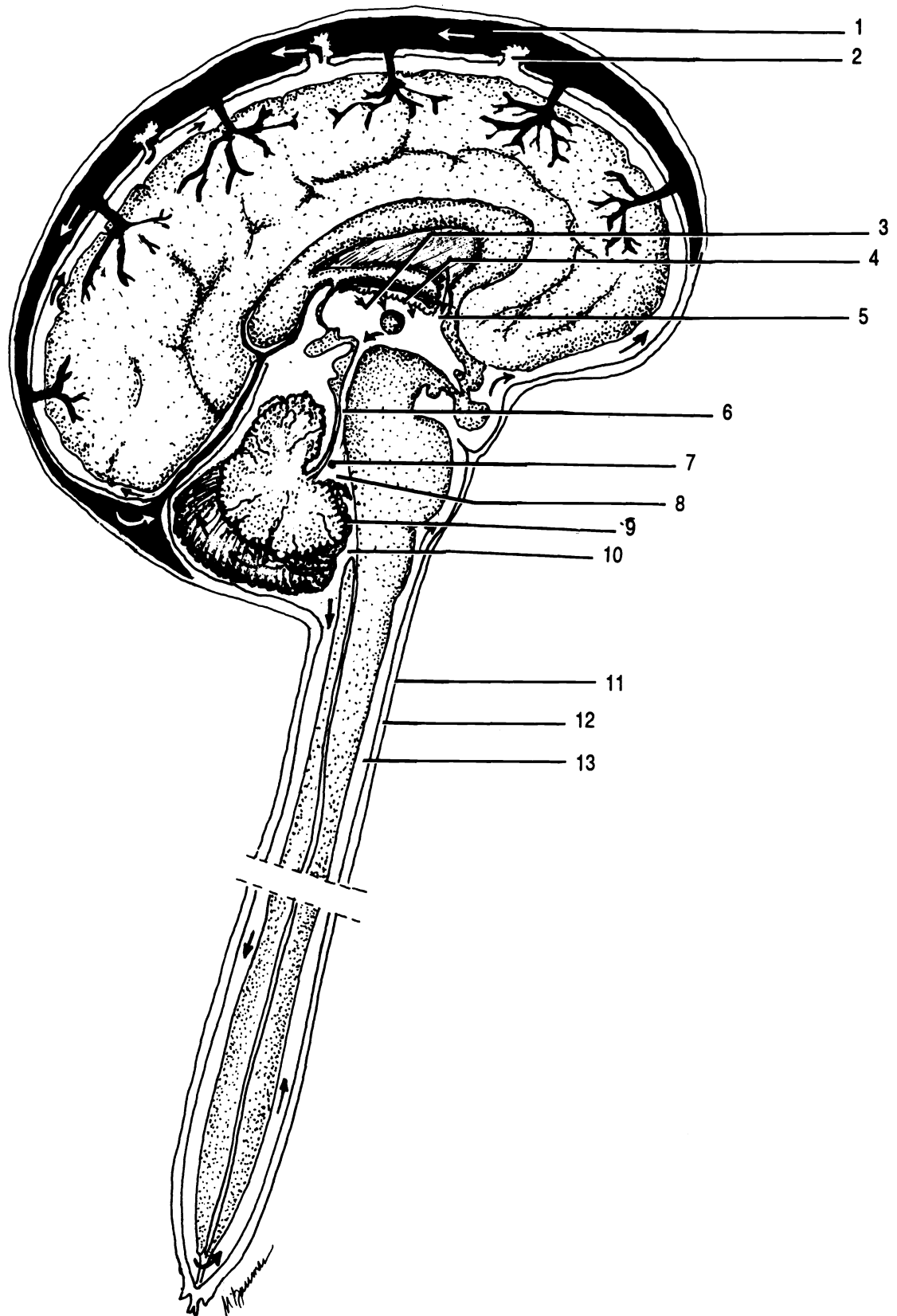


Figure 23.6 Origin and Circulation of Cerebrospinal Fluid

Aqueduct of Sylvius Arachnoid granulation Choroid plexus of the fourth ventricle Choroid plexus of the third ventricle
 Dura mater Foramen of Luschka Foramen of Magendie Foramen of Monro Fourth ventricle Sagittal sinus
 Subarachnoid space Subdural space Third ventricle

Exercise 23.2

Study the model of the sagittal section of the brain. Identify the following structures on the model: aqueduct of Sylvius, cerebellum, cerebral peduncle, cerebrum, choroid plexus of the third ventricle, corpora quadrigemina, corpus callosum, fornix, gyri, hypothalamus, intermediate mass, medulla, pineal gland, pituitary gland, pons, sulci, and thalamus.

Study the model of the whole brain. Identify the following structures on the model: aqueduct of Sylvius, cerebellum, cerebral peduncle, cerebrum, choroid plexus of the third ventricle, corpora quadrigemina, corpus callosum, fornix, gyri, hypothalamus, intermediate mass, mammillary bodies, medulla, pineal gland, pituitary gland, pons, sulci, and thalamus.

Study the wall chart of the sagittal section of the brain. Identify the following structures on the wall chart: aqueduct of Sylvius, cerebellum, cerebral peduncle, cerebrum, choroid plexus of the fourth ventricle, choroid plexus of the third ventricle, corpora quadrigemina, corpus callosum, fourth ventricle, gyri, hypothalamus, infundibulum, intermediate mass, mammillary bodies, medulla, optic chiasma, pineal gland, pituitary gland, pons, sub-arachnoid space, sulci, thalamus, and third ventricle.

Exercise 23.3

Study a halved sheep brain. Identify the following structures of the sheep brain: aqueduct of Sylvius, cerebellum, cerebral peduncle, cerebrum, corpora quadrigemina, corpus callosum, fornix, fourth ventricle, hypothalamus, infundibulum, intermediate mass, mammillary body, medulla, olfactory bulb, optic chiasma, pineal gland, pituitary gland, pons, spinal cord, and thalamus.

Study a whole sheep brain. Find the following structures on the whole sheep brain: cerebellum, cerebrum, infundibulum, longitudinal fissure, mammillary body, medulla, midbrain, olfactory tract, olfactory bulb, optic chiasma, optic tract, optic nerve II, pituitary gland, pons, and spinal cord.

CHAPTER 23 REVIEW

1. _____ The bridge of white matter that connects the two cerebral hemispheres is called the (1).
2. _____ The convolutions of the cerebrum are referred to as (2).
3. _____ Name the cranial nerves that originate from the medulla of the brain. Give name and number.
4. _____
5. _____
6. _____
7. _____
8. _____ Name the four major areas of the brain.
9. _____
10. _____
11. _____
12. _____ Cerebrospinal fluid is reabsorbed back into circulation through finger like projections called (12).
13. _____ Within the (13), the medial halves of the optic nerves cross over and go to opposite sides of the brain.
14. _____ The extension of the dura mater between the two cerebral hemispheres is known as the (14).
15. _____ The lateral walls of the third ventricle are formed by what two parts of the brain?
16. _____
17. _____ The structure found within each ventricle that will serve as the site of origin of cerebrospinal fluid is called the (17).

18. _____ Name the five lobes of the brain.

19. _____

20. _____

21. _____

22. _____

23. _____ The lateral openings in the fourth ventricle that connect to the subarachnoid space are known as the (23).

24. _____ The fissure that almost completely separates the two cerebral hemispheres is called the (24).

THE EYE AND VISUAL TESTS

THE NASOLACRIMAL APPARATUS

The orbit of the eye is formed by the following bones: maxillae, lacrimals, ethmoid, zygomatics, sphenoid, and frontal. The eye itself fits into the recess formed by these bones (the orbit). Protecting the anterior aspects of the eye are the **eyelids (or palpebrae)**. Covering the posterior surface of the eyelids and covering the anterior portion of the sclera is a thin membrane called the **conjunctiva**. It is continuous with the epithelium of the cornea. Located in the superior, anterolateral aspect of the orbit of each eye is a **lacrimal gland**. The lacrimal gland is divided into two parts: the **superior lacrimal gland** and the **inferior lacrimal gland**. Leading from these glands are six to twelve lacrimal ducts that empty tears (lacrimal fluid) onto the surface of the conjunctiva. The tears bathe the surface of the eye and then pass medially into two openings called **lacrimal punctae**. These two openings lead into the **superior lacrimal duct** (located in the upper eyelid) and the **inferior lacrimal duct** (located in the lower eyelid). These two ducts open into a large cavity called the **lacrimal sac**. The lacrimal sac empties into the **nasolacrimal duct**. This duct opens into the nasal cavity. The moisture from the tears then serves to humidify the air we breath. Located between the lacrimal punctae is a mound of tissue that contains sebaceous and sweat glands called the **caruncle**. The caruncle secretes a whitish material that collects in the corner of each eye. In the medial corner of the eye is a small fold called the **plica semilunaris**. It is believed by some to be a homologue (similarity in structure and origin of two parts in different species of animals) of the nictitating membrane, which is a third eyelid present in lower vertebrate animals.

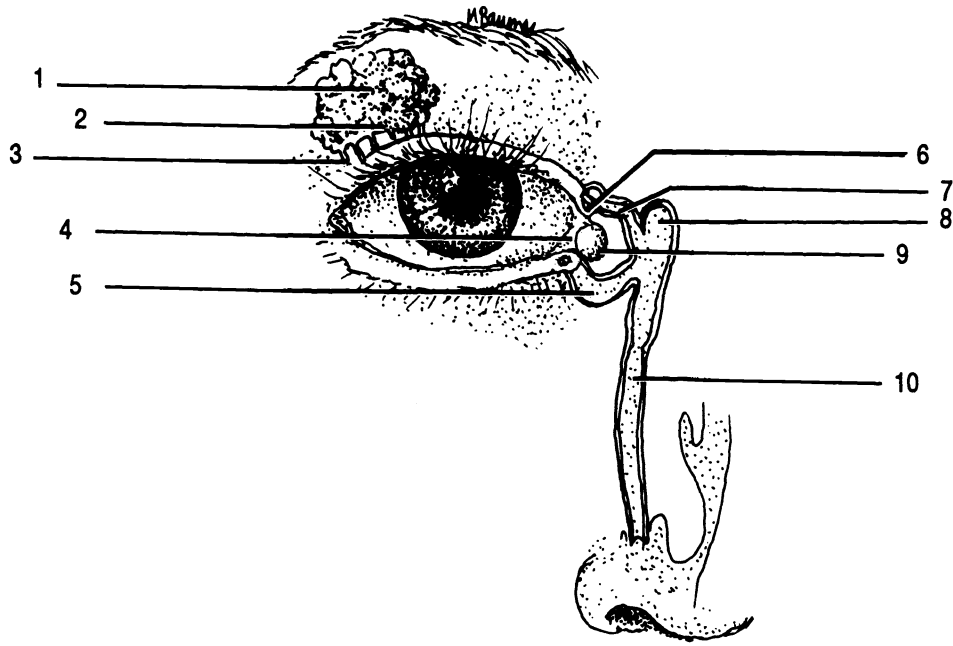
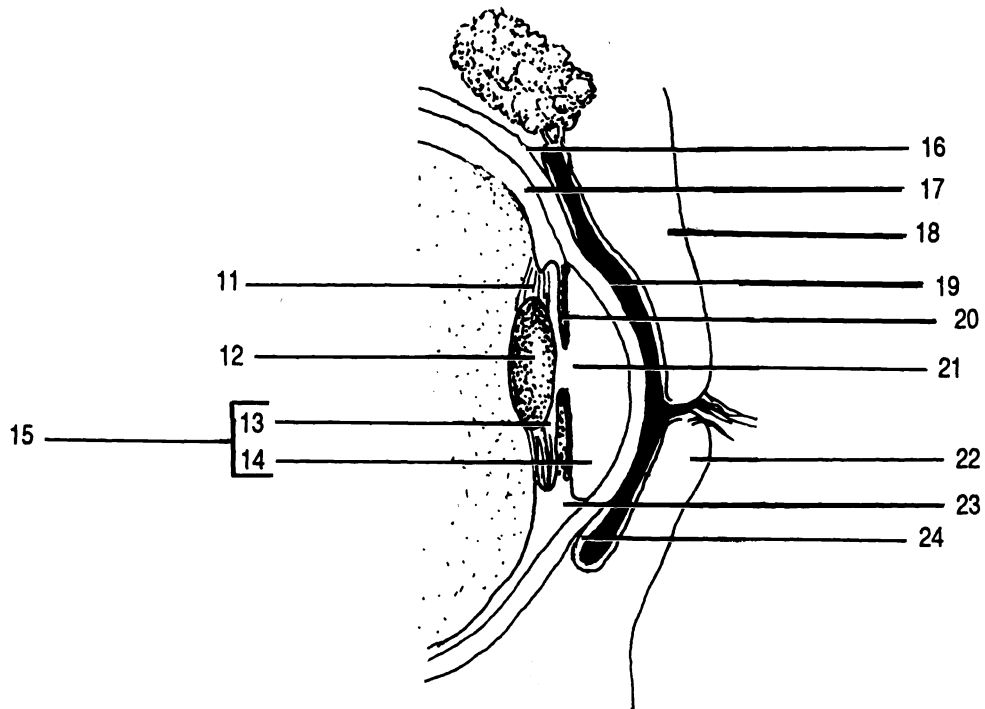


Figure 24.1 Nasolacrimal Apparatus

Anterior cavity Anterior chamber Caruncle Choroid Ciliary body Conjunctiva Cornea Eyelids (Palpebrae) (X2)
 Inferior lacrimal duct Inferior lacrimal gland Iris Lacrimal duct Lacrimal punctum Lacrimal sac Lens Nasolacrimal
 duct Plica semilunaris Posterior chamber Pupil Sclera Superior lacrimal duct Superior lacrimal gland
 Suspensory ligament



INTERNAL ANATOMY OF THE EYE

A transverse section through the middle of the eyeball shows three layers. The outermost layer is the **sclera**. It is white in color and consist of dense fibrous connective tissue. The sclera covers the entire aspect of the eye except the anterior pigmented portion of the eye, the **iris**. Covering the iris is a transparent, nonvascular fibrous coat called the **cornea**.

The middle layer of the eye is the **choroid**. The choroid is pigmented and contains numerous blood vessels. Anteriorly, the choroid consists of the **ciliary body** and **iris**. The ciliary body contains smooth muscle called the ciliary muscle which is necessary for changing the shape of the **lens** of the eye. The iris is a pigmented structure. The more pigment the iris contains, the darker its color. The black hole in the middle of the iris is the **pupil**. It is through the pupil that light rays enter the eye. Connecting the lens of the eye to the ciliary body is the **suspensory ligament**.

The innermost layer of the eyeball is the **retina**. The retina is made up of neurons such as rods and cones. The axons of some other neurons converge and exit through the posterior aspect of the eye. The point of convergence is called the **optic disc** or blind spot. There are no photoreceptors in the optic disc and hence light striking on this spot cannot be perceived. The axons from the retina pierce the choroid and sclera and are known as the **optic nerve (II)**.

In the exact center of the retina is a depression called the **macula lutea**. The center of the macula lutea is called the **fovea centralis** which has the highest concentration of cones within the eye. There are no rods located within the macula lutea.

The interior of the eyeball is divided into two cavities by the lens. The cavity in front of the lens is called the **anterior cavity**. It is divided into two chambers. The **anterior chamber** is in front of the iris and the **posterior chamber** is behind the iris. The anterior cavity contains a watery fluid called the **aqueous humor**. Aqueous humor is constantly being produced by the choroid plexuses of the ciliary body, passes into the posterior chamber, and then into the anterior chamber. The aqueous humor is then reabsorbed into small spaces called **trabeculae**. From the trabeculae, the aqueous

humor is drained into a venous sinus called the **canal of Schlemm**. The canal of Schlemm is located at the junction of the sclera and cornea and completely encircles the eye at this point.

The cavity behind the lens of the eye is called the **posterior cavity**. It contains a jellylike substance called the **vitreous body**. The vitreous body helps the eyeball to maintain its shape and helps to hold the retina in place. Once the eyeball has completed its development, no additional vitreous body is produced.

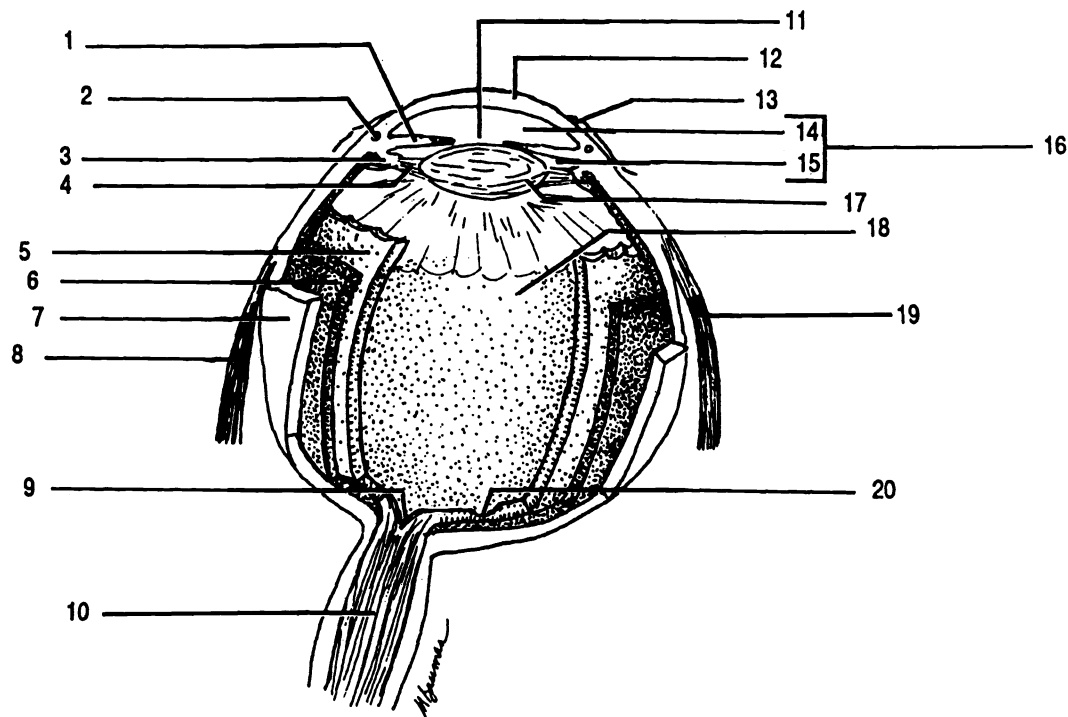


Figure 24.2 Internal Anatomy of the Eyeball

Anterior cavity Anterior chamber Canal of Schlemm Choroid Ciliary body Conjunctiva Cornea Iris
 Lateral rectus Lens Macula lutea Medial rectus Optic disc (Blind spot) Optic nerve II Posterior cavity
 Posterior chamber Pupil Retina Sclera Suspensory ligament

EXTRINSIC EYE MUSCLES

The upper eyelid is more movable than the lower eyelid. The upper eyelid is elevated by the **superior levator palpebrae** muscle.

On the superior aspect of the orbit of the eye is the **superior rectus** muscle. On the inferior aspect of the orbit of the eye is the **inferior rectus** muscle. These two muscles move the eye straight up and down.

On the lateral aspect of the orbit of the eye is the **lateral rectus** muscle. On the medial aspect of the orbit of the eye is the **medial rectus** muscle. These two muscles move the eye from side to side.

Between the medial rectus muscle and the superior rectus muscle is the **superior oblique** muscle. This muscle passes through a cartilaginous loop, the **trochlea**, to attach to the eyeball. Antagonist to the superior oblique muscle is the **inferior oblique** muscle. These two muscles cause the eye to move at angles.

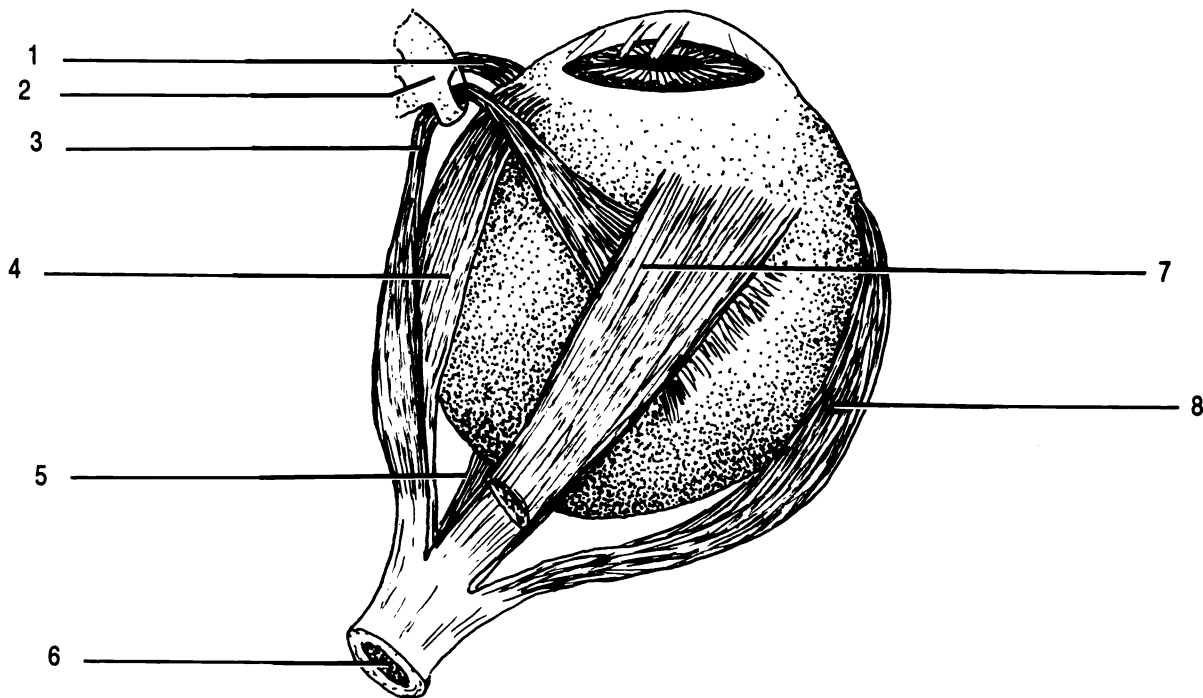


Figure 24.3 Extrinsic Eye Muscles, Superior View

Inferior oblique Inferior rectus Lateral rectus Medial rectus Optic nerve II Superior oblique
Superior rectus Trochlea

OPHTHALMOSCOPE

Exercise 24.1

An ophthalmoscope is used to view the fundus or interior of the eye.

To turn on the ophthalmoscope, depress the red button and turn the black ring. Do not use an intense light when looking into your lab partner's eye. Set the diopter window to read "0." Your lab partner will need to look straight ahead without blinking. Hold the ophthalmoscope next to your eye so that you can see through the viewing aperture. While looking through the viewing aperture, move from the lateral side of your lab partner's eye toward the medial aspect so that you are "cheek to cheek." This will minimize the photopupil reflex and direct your attention towards the optic disk. The optic disk has blood vessels radiating from it. By moving toward the middle of the eye, you may be able to locate the macula lutea.

VISUAL TESTS

Exercise 24.2

Perform the following visual tests with a partner.

The Blind Spot. At the point where the optic nerve exits from the eye, there are no rods or cones; hence, light that strikes this area of the retina is not perceived. Figure 24.4 can be used to detect the presence of this blind spot.

To test the right eye, leave the left eye open but cover it with your hand. Place figure 24.4 so that the plus sign is directly in front of your eye and about a foot and a half away. Slowly move the figure toward your eye until the dot disappears. The image of the dot is now at the optic disk, the blind spot.

To test the left eye, leave the right eye open but cover it with your hand. Place figure 24.4 so that the dot is directly in front of your eye and about a foot and a half away. Slowly move the figure toward your eye until the plus sign disappears.



Figure 24.4 Blind Spot Test Chart

Scheiner's Experiment. Use the small black box with a silver circle of foil pasted in the middle. Close one eye and place the black box next to your face so that you are looking through the two small holes in the middle of the foil. While looking through the two holes, hold at an arm's length a straight pin. Focus on the pin and notice that a single image is seen. Slowly move the pin toward your eye. At some point it will become a double image. The distance from your eye to the pin when it is a double image is called the near point. The near point is the closest distance at which you can see an object in sharp focus. Have your lab partner measure this distance.

Visual Acuity. Stand twenty feet from a Snellen eye chart, cover one eye and read the letters on the chart from top to bottom until you are unable to read any of the letters. Have your partner check you. Cover the other eye and repeat the process. With both eyes open read the letters on the chart from top to bottom until you are unable to read any of the letters.

If you can read correctly all the letters on line 8, you have 20/20 vision. This indicates that you have no abnormalities in the shape of your eye or the refractive qualities of the lens and that your eye can bring an image to sharp focus. If on the other hand, you can only read line 1 at twenty feet, you have 20/200 vision. A person with 20/20 vision could read this line at two hundred feet.

Test for Astigmatism. This test checks for irregularities in the curvature of the cornea or the lens of the eye. Use the

astigmatism test chart that has been placed on the lab wall. *Focus on the center of the chart. Observe the lines radiating from the center of the chart and note if they are all of the same intensity and darkness of color. If they all appear to be equal in intensity, astigmatism does not exist in your eyes.*

Test for Color Blindness Color blindness is a sex linked recessive disorder that affects about 8% of the male population and less than 1% of the female population. The most common type is red-green color blindness. *Use Ishihara's Color Plates and the Pseudoisochromatic Color Plates to determine if you have color blindness. In the front of each book is a chart that gives the plate number and what a person with normal vision sees and what a person with red-green color blindness would see.*

Photopupil Reflex *Using the ophthalmoscope or another source of light, shine a bright light into your lab partner's eye briefly and then remove the light source. With intense light, the pupil size should become smaller.*

Accommodation Reflex *Have your lab partner focus on his/her lab guide and then have him/her look across the room. Observe his/her pupil size. When he/she focuses on his/her lab guide, the pupil size should decrease. When he/she focuses across the room, his/her pupil size should increase.*

Exercise 24.3

Using your text as a guide, fill in the labels on Figures 24.1 - 24.3.

Exercise 24.4

Study the model of the eyeball. Identify the following structures on the model: choroid, ciliary body, cornea, inferior rectus muscle, inferior oblique muscle, iris, lateral rectus muscle, lens, macula lutea/fovea centralis, medial rectus muscle, optic nerve II, optic disc, optic chiasma, ora serrata, pupil, retina, sclera, superior oblique muscle, superior rectus muscle, and trochlea.

Exercise 24.5

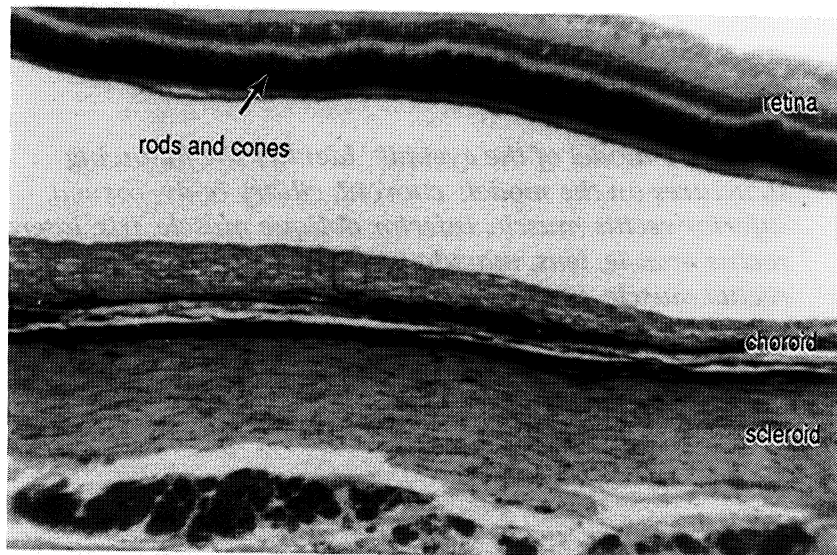
Study the wall chart of the eye. Identify the following structures on the wall chart: anterior cavity, anterior chamber, arachnoid mater, choroid, ciliary body, conjunctiva, cornea, dura mater, iris, lateral rectus muscle, lens, macula lutea/fovea centralis, medial rectus muscle, optic nerve II, optic disc, pia mater, posterior cavity, posterior chamber, pupil, retina, sclera, subarachnoid space, and suspensory ligament.

Exercise 24.6

Dissect a sheep eye. Most of the extrinsic eye muscle may be cut away. Be careful not to cut the optic nerve (II). Make an incision about half way between the cornea and the point where the optic nerve exits from the eye. The sclera is very tough and since pressure is applied when cutting through with a scalpel, it may squirt! After the initial incision is made, scissors may be used to finish cutting the eyeball into two parts. The choroid contains an iridescent reflective layer called the tapetum lucidum. It enhances an animal's ability to see at night and gives the animal's eyes a glow when light is reflected back. Identify the following structures: choroid, ciliary body, cornea, iris, lens, optic disc, optic nerve II, pupil, retina, and sclera.

Exercise 24.7

Examine a microscope slide of a cross section of an eye on low power. Identify the following structures: retina, choroid, and sclera.



CHAPTER 24 REVIEW

1. _____ The middle layer of the eye is referred to as the (1).
2. _____ The structure that holds the lens to the ciliary body is called the (2).
3. _____ The name given to the two holes that open into the superior lacrimal duct and the inferior lacrimal duct is (3).
4. _____ The thin membrane that lines the posterior surface of the eyelids and covers the anterior surface of the eyeball is known as the (4).
5. _____ Name the two muscles of the eyeball that move the eye from side to side.
6. _____
7. _____ Name the muscle of the eye that elevates the upper eye lid.
8. _____ The posterior chamber of the eye contains a jellylike fluid called (8).
9. _____ The portion of the retina that does not contain any rods or cones is known as the (9).
10. _____ The Snellen eye chart is used to check (10).
11. _____ The small depression within the macula lutea that has the greatest concentration of cones is called the (11).
12. _____ The white layer of the eye that contains dense fibrous connective tissue is the (12).
13. _____ The venous structure of the eye that drains aqueous humor is known as the (13).
14. _____ The instrument that may be used to view the fundus of the eye is called a(n) (14).
15. _____ The glands that produce the tears of the eye are the (15).
16. _____ The clear, transparent structure of the eye that is an extension of the sclera is the (16).
17. _____ The layer of the eye that contains nervous tissue is the (17).
18. _____ Changes in the pupil size due to viewing a near object and then viewing an object far away is know as the (18).

19. _____

The dark hole in the middle of the iris of the eye is called the (19).

20. _____

Name the six bones that form the orbit of the eye.

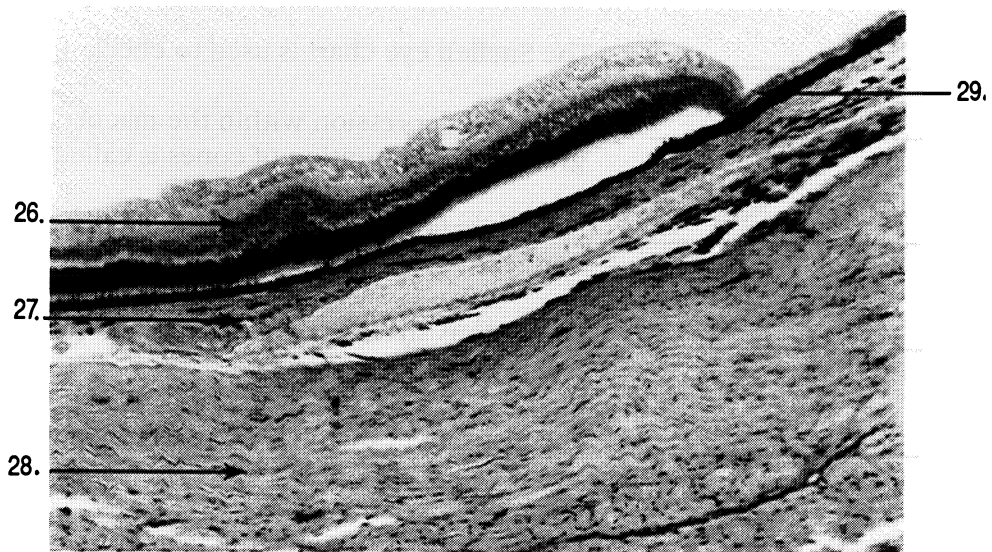
21. _____

22. _____

23. _____

24. _____

25. _____



CHAPTER 25

THE EAR

Exercise 25.1

As you read and using your textbook as a guide, label Figure 25.1.

The ear is divided into three parts: the external ear, the middle ear, and the inner ear.

The **external ear** consists of two parts: the auricle (or pinna) and the external auditory canal. The **auricle (or pinna)** is a triangular shaped appendage consisting of skin and elastic cartilage attached to the lateral aspect of the head. The **external auditory canal** is a tube about 2.5 centimeters long that extends from the auricle to the **tympanic membrane (eardrum)**.

The tympanic membrane serves to separate the external ear from the middle ear. The **middle ear** contains three tiny bones. The tympanic membrane is attached to the **malleus** (a hammer shaped bone), which is connected to the **incus** (an anvil shaped bone), which is connected to the **stapes** (a stirrup shaped bone). Beneath the stapes is the **oval window**. Covering the oval window is a thin membrane which serves to separate the perilymph of the inner ear from the middle ear. The **perilymph** is fluid that serves to conduct sound vibrations within the inner ear. The middle ear connects to the nasopharynx by way of the **eustachian tube**. One function of the eustachian tube is to equalize the pressure on the two sides of the tympanic membrane.

The **inner ear** consists of two parts: the bony labyrinth and the membranous labyrinth. The **bony labyrinth** is so named because it is within the temporal bone of the skull. The **membranous labyrinth** is so named because it is made up of membranous tissues; it fits within the bony labyrinth. Within the membranous labyrinth is a fluid called **endolymph**. The perilymph is located between the membranous labyrinth and the bony

labyrinth. Both of these fluids are involved in sound vibration transmission and the maintenance of equilibrium.

The bony labyrinth is made up of three parts: the vestibule, the cochlea, and the semicircular canals. The **vestibule** is an enlarged bulb shaped structure that has the stapes attached to it. The **cochlea** is shaped like a snail's shell and is attached to the vestibule. There are three **semicircular canals** which connect to the vestibule. The semicircular canals lie at right angles to one another. The **superior semicircular canal** is oriented vertically and projects upward. The **posterior semicircular canal** is oriented vertically and projects toward the back of the head. The **lateral semicircular canal** is oriented horizontally and projects toward the lateral aspect of the head. Each semicircular canal has an enlargement called an **ampulla**. An ampulla connects the semicircular canal to the vestibule and contains an equilibrium sensory structure called the **crista ampullaris**, which functions in dynamic equilibrium (equilibrium during movement).

There are two nerve branches that attach to the bony labyrinth. The **vestibular branch of the vestibulocochlear nerve VIII** has sensory branches leading away from the ampulla and vestibule. The **cochlear branch of the vestibulocochlear nerve VIII** has sensory branches leading away from the cochlea.

The cochlea is divided into three chambers. The uppermost is called the **scala vestibuli**. The scala vestibuli is continuous with the vestibule and contains perilymph. The middle chamber is called the **cochlear duct** and it contains endolymph. The lower chamber is called the **scala tympani**. It, like the scala vestibuli, contains perilymph. At the stapedial end of the scala tympani is a round, membrane-covered opening called the **round window**.

The scala vestibuli is separated from the cochlear duct by a thin membrane called the **vestibular membrane**. The cochlear duct is separated from the scala tympani by the **basilar membrane**. Resting on the basilar membrane is the **organ of Corti**. The organ of Corti is the organ of hearing since it contains receptor cells. These receptor cells are called **hair cells**. The axons of these sensory hair cells form the **cochlear nerve fibers**. Covering the organ of Corti is a gelatinous like structure called the **tectorial membrane**.

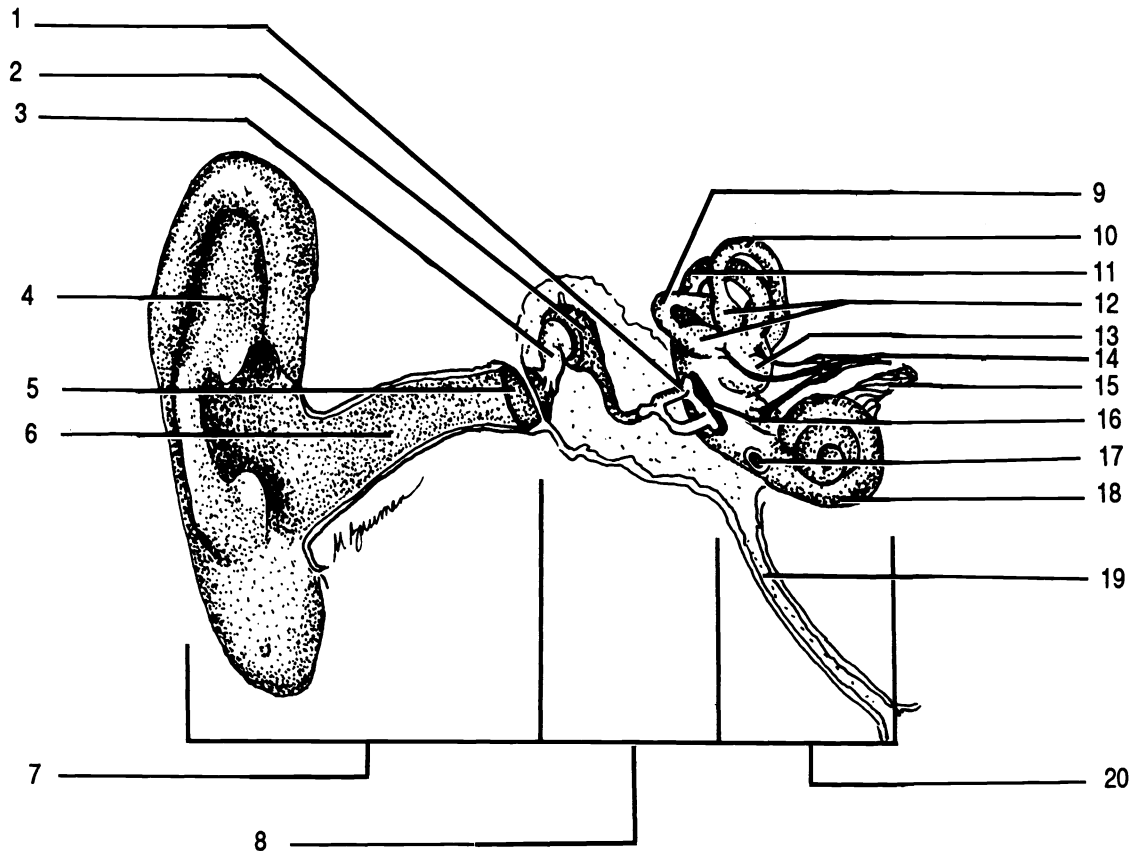


Figure 25.1 Anatomy of the Ear

Ampullae of semicircular canals Auricle (Pinna) Cochlea Cochlear branch of vestibulocochlear nerve VIII
 Eustachian tube External auditory canal External ear Incus Inner ear Lateral semicircular canal Malleus
 Middle ear Oval window Posterior semicircular canal Round window Stapes Superior semicircular canal
 Tympanic membrane Vestibular branch of vestibulocochlear nerve VIII Vestibule

NYSTAGMUS

Nystagmus may be defined as involuntary eye movements characterized by slow and quick phases in opposite directions. The eye movements following rotation of the head are known as nystagmus. They show how complex, yet orderly, some of our reflex processes are. If the head is rotated slowly to the left, the eyes move slowly to the right. As soon as the eyes have moved as far to the right as possible, they then move quickly to the left.

Nystagmus may be demonstrated by the use of a swivel type chair. This demonstration will require the assistance of at least four persons in addition to the subject. The subject will be seated in the swivel chair and the four assistants will position themselves equally around the chair to insure the safety of the subject.

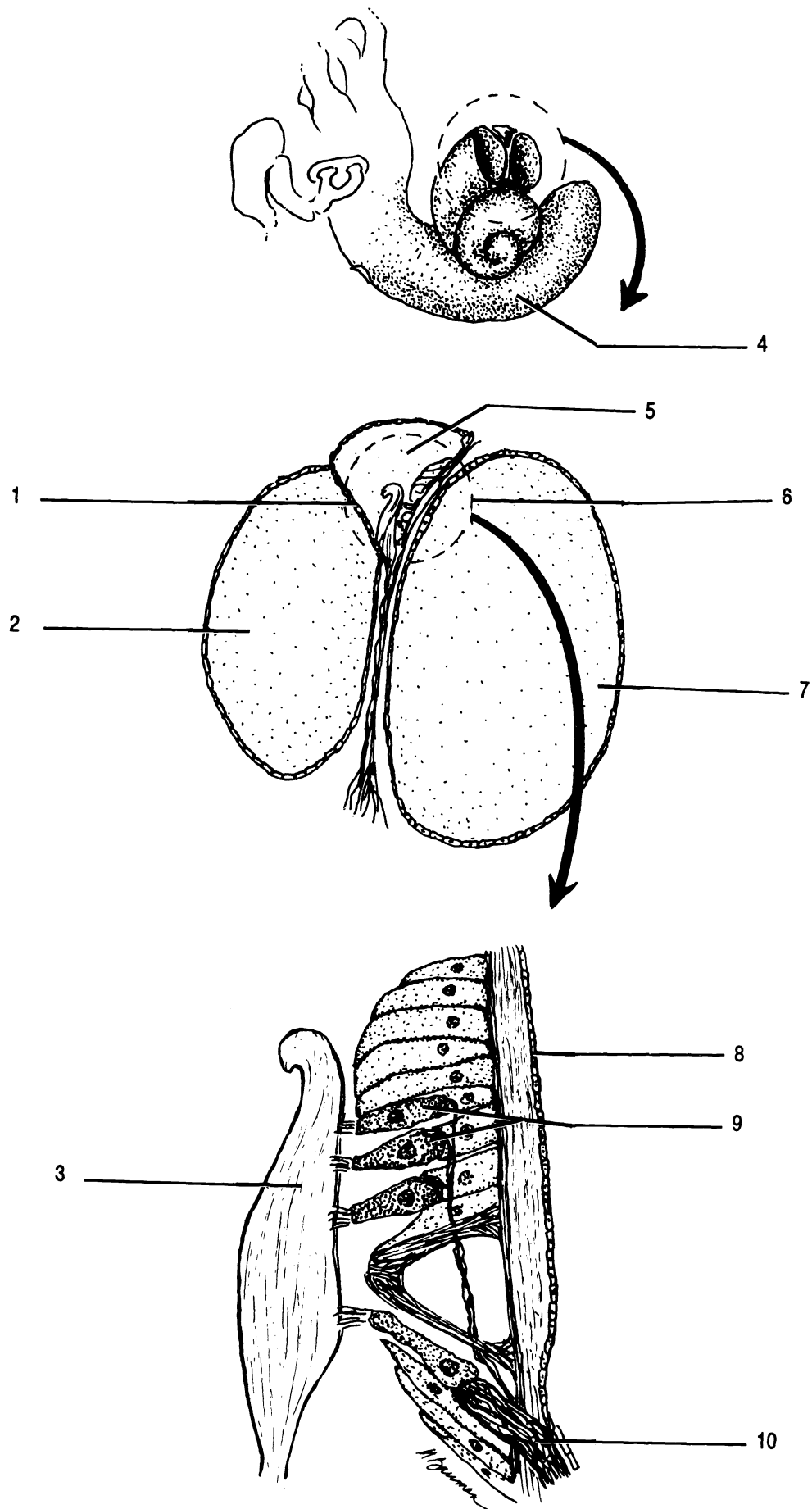


Figure 25.2 Cross Section of the Cochlea

Basilar membrane Cochlea Cochlear duct Cochlear nerve fibers Hair cells Organ of Corti Scala tympani
 Scala vestibuli Tectorial membrane Vestibular membrane

Exercise 25.2.

Have the subject sit in the swivel chair with their legs crossed, feet in the chair, and gripping the arms of the chair.

The four assistants should hold the chair in place using their feet.

One of the assistants should slowly rotate the subject clockwise. All should observe the subject's eye movement as the subject stares straight ahead during the spinning. Make one revolution about every three seconds for ten seconds.

Give the subject time to recover from the spinning before allowing him/her to get out of the chair.

Repeat the above demonstration with another subject; however, rotate him/her in a counterclockwise direction. Observe his/her eye movements.

Repeat the above demonstration with still yet another subject; however, have the subject close his/her eyes during rotation and then have them open his/her eyes upon stopping.

Exercise 25.3

Study the wall chart of the ear. Identify the following structures on the wall chart: ampulla of the lateral semicircular canal, ampulla of the posterior semicircular canal, ampulla of the superior semicircular canal, auricle, cochlea, cochlear branch of the vestibulocochlear nerve VIII, external auditory canal, eustachian tube, facial nerve VII, incus, lateral semicircular canal, malleus, oval window, posterior semicircular canal, round window, stapes, superior semicircular canal, tympanic membrane, vestibule, and vestibular branch of the vestibulocochlear nerve VIII.

Exercise 25.4

Examine a microscope slide of a cross section of the cochlea on low power. Identify the following structures: basilar membrane, cochlear duct, hair cells, scala tympani, scala vestibuli, tectorial membrane, and vestibular membrane.

Examine a microscope slide of a section through the crista ampullaris on low power. Identify the crista ampullaris.

Exercise 25.5

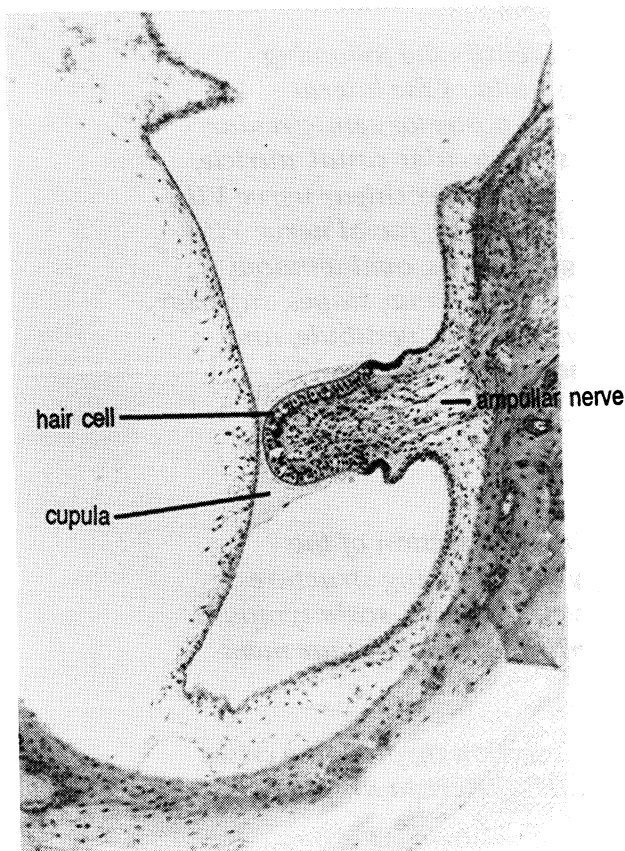
Study the model of the ear. Identify the following structures on the model: auricle (or pinna), cochlea, eustachian tube, external auditory canal, incus, lateral semicircular canal, malleus, oval window, posterior semicircular canal, round window, stapes, superior semicircular canal, tympanic membrane, vestibule, and vestibulocochlear nerve VIII.

Exercise 25.6

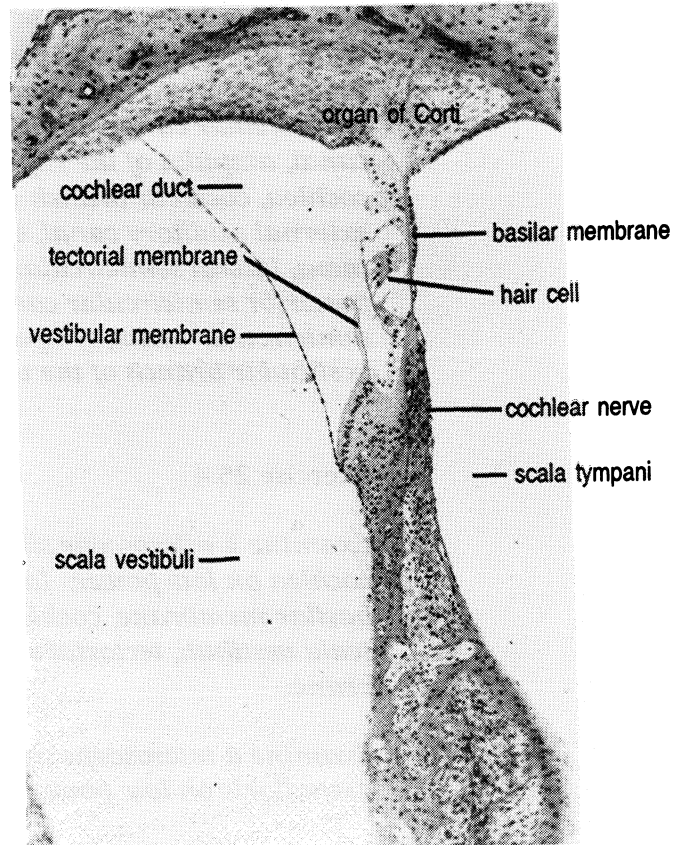
An otoscope is used to view the external auditory canal and tympanic membrane of the ear.

Take an alcohol cotton ball and wipe the ear piece of the otoscope. To turn on the otoscope, depress the red button and turn the black ring. Gently pull outward and upward on the auricle (pinna) of the ear. Carefully place the otoscope into the external auditory canal. Examine the external auditory canal and observe the tympanic membrane which will cover the end of the external auditory canal.

After you have finished examining your lab partner's external auditory canal, wipe the ear piece of the otoscope with an alcohol cotton ball.



Crista ampullaris



Cochlea

CHAPTER 25 REVIEW

1. _____ The tube like passageway that leads from the outside to the tympanic membrane is called the (1).
2. _____ The fluid that is located between the membranous labyrinth and the bony labyrinth is known as (2).
3. _____ The branch of the vestibulocochlear nerve VIII that carries sensory information away from the ampulla of each semicircular canal and the vestibule is known as the (3).
4. _____ Name the three bones of the middle ear.
5. _____
6. _____
7. _____ The tube that serves to connect the middle ear to the pharynx and which equalizes pressure on the two sides of the tympanic membrane is known as the (7).
8. _____ The triangular shaped appendage on the lateral side of the head that contains elastic cartilage is called the (8).
9. _____ The coiled snail like structure of the inner ear is known as the (9).
10. _____ The specific semicircular canal that projects toward the back of the head is called the (10) semicircular canal.
11. _____ The upper chamber of the cochlea that contains perilymph is called the (11).
12. _____ The sensory receptors that sit on top of the basilar membrane are known as (12).
13. _____ Name the three parts of the bony labyrinth.
14. _____
15. _____
16. _____ The small round opening at the stapedial end of the scala tympani is referred to as the (16).

HEMATOLOGY

Hematology is the study of blood. We will be using various tests to study the white blood cells, red blood cells, and aspects of the blood plasma.

TOTAL WHITE BLOOD CELL COUNT

The total white blood cell count provides the number of leukocytes per cubic millimeter of blood. A range of **4,000 to 11,000 per cubic millimeter (mm³)** of blood is considered to be normal.

Exercise 26.1

Materials: (Figure 26.1)
Cotton ball soaked in alcohol
Dry cotton ball
Sterile disposable lancet
Unopette for white blood cell counts
Hemocytometer and cover glass
Mechanical hand counter
Microscope

1. The Unopette for white blood cell counts consists of three parts: reservoir, pipette, and shield. The shield is used to introduce a hole into the reservoir. Puncture the reservoir with the shield before proceeding any further. The reservoir contains acetic acid which will destroy the red blood cells, leaving only white blood cells. The pipette, which has the number "25" etched in blue, is used to draw blood from the finger.

2. Scrub a finger with alcohol. Stick the finger with a sterile lancet. Immediately after using the lancet, place it in the bio-hazard container. Do not try to recap the lancet. Any disposable object contaminated with blood should be placed into the bio-hazard container.

3. Place the pipette into the blood at an angle slightly above horizontal. Capillary action will draw the blood

into the pipette. The blood will only fill the pipette the correct amount. Do not be concerned about over-filling the pipette.

4. Immediately upon filling the pipette, place a finger over the wide end of the pipette, with your other hand squeeze the reservoir slightly, seat the pipette into the reservoir, remove your finger from the pipette, then let go of the reservoir. A slight vacuum is created in the reservoir and the blood will be sucked into the reservoir. Squeeze the reservoir several times to mix any blood in the reservoir with the acetic acid. The blood and acetic acid must stand for at least ten minutes or longer before it is ready to use. It can stand longer.

5. Charge the hemacytometer. To charge the hemacytometer, place the cover glass on the raised surfaces of the hemacytometer. Remove the pipette from the reservoir and insert the other end of the pipette into the reservoir. Squeeze out several drops of the mixture into a dry cotton ball. Place a small drop of the mixture on the polished counting surface of the hemacytometer next to the edge of the cover glass. Capillary action will suck the mixture under the cover glass. The chamber is properly filled when the polished counting surface is evenly filled with none of the mixture running into the moat around the counting surface.

6. Place the hemacytometer under the low power objective and locate the grid lines. Figure 26.1 shows the grid line arrangement of the hemacytometer. Note on the drawing the areas that have the large "W" marked on them. These four corner areas have each been subdivided into sixteen smaller grids. Count the white blood cells in each of the four large grids. On low power, the large grid area will almost fill the entire field of view. Using the mechanical hand counter, systematically count the sixteen smaller grids. To avoid over counting, count those cells that touch the grid lines on the left and top boundaries. Do not count those cells that touch the grid lines on the right and bottom boundaries.

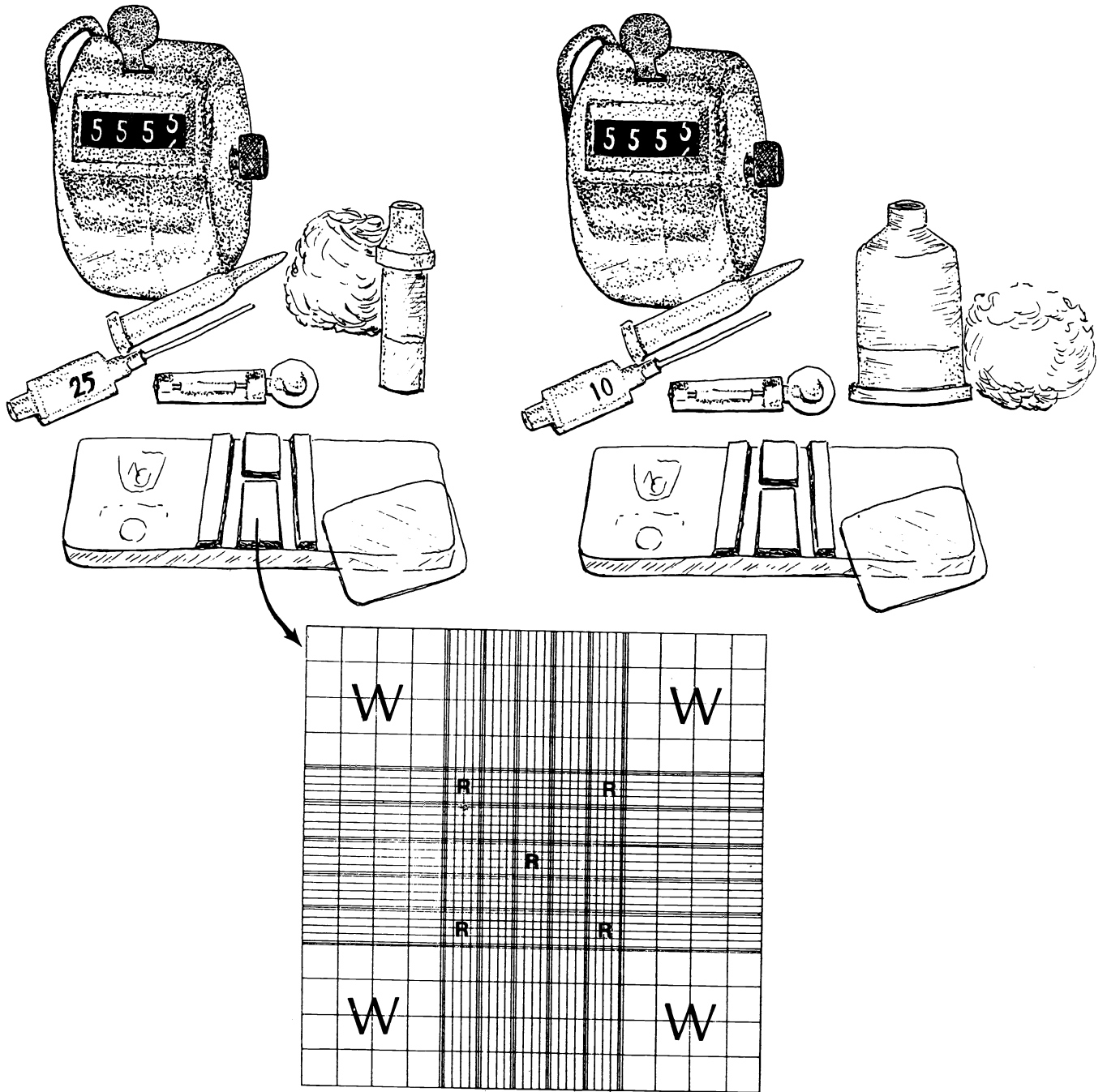
7. To determine the number of white blood cells per cubic millimeter of blood, add the number of cells counted in the four large grid area and multiply the total by 50.

8. Once you have finished your count, place your Unopette for white blood counts into the bio-hazard container.

9. Record your total white blood cell count below.

Figure 26.1 Materials for WBC Count

Materials for RBC Count



TOTAL RED BLOOD CELL COUNT

The total red blood cell count is the number of erythrocytes per cubic millimeter of blood. **A range of 4.2 million to 6.0 million per cubic millimeter of blood is considered to be normal for a male. A range of 3.8 million to 5.4 million per cubic millimeter of blood is considered to be normal for a female.**

Exercise 26.2

Materials: (Figure 26.1)

Cotton ball soaked in alcohol

Dry cotton ball

Sterile disposable lancet

Unopette for red blood cell counts

Hemocytometer and cover glass

Mechanical hand counter

Microscope

- 1. Obtain a Unopette for red blood cell counts. It consists of three parts: reservoir, pipette, and shield. The shield is used to introduce a hole into the reservoir. Puncture the reservoir with the shield before proceeding any further. The reservoir, which has red writing on the bottom and is larger than the reservoir for white blood cell counts, contains a saline solution which will dilute the red blood cells. The pipette, which has the number "10" etched in pink, is used to draw blood from the finger.*
- 2. Scrub a finger with alcohol. Stick the finger with a sterile lancet. Immediately after using the lancet, place it in the bio-hazard container. Do not recap the lancet. Any disposable object contaminated with blood should be placed into the bio-hazard container.*
- 3. Place the pipette into the blood at an angle slightly above horizontal. Capillary action will draw the blood into the pipette. The blood will only go so far into the pipette so it will not overflow.*
- 4. Immediately upon filling the pipette, place a finger over the wide end of the pipette, with your other hand squeeze the reservoir slightly, seat the pipette into the reservoir, remove your finger from the pipette, then let go of the reservoir. A slight vacuum is created in the reservoir and the blood will be sucked into the reservoir. Squeeze the reservoir several times to mix the blood with the saline*

solution. The blood and saline mixture may be used immediately, or it may stand before use.

5. Charge the hemacytometer. To charge the hemacytometer, place the cover glass on the raised surfaces of the hemacytometer. Remove the pipette from the reservoir and insert the other end of the pipette into the reservoir. Squeeze out several drops of the mixture into a dry cotton ball. Place a small drop of the mixture on the polished counting surface of the hemacytometer next to the edge of the cover glass. Capillary action will suck the mixture under the cover glass. The chamber is properly filled when the polished counting surface is evenly filled with none of the mixture running into the moat around the counting surface.

6. Place the hemacytometer under the low power objective and locate the grid lines. Figure 26.1 shows the grid line arrangement of the hemacytometer. Note on the drawing the five areas that have the "R" marked on them. These five areas have each been subdivided into sixteen smaller grids. Switch to high power and count the red blood cells in each of the five grids. On high power, each grid area will almost fill the field. With a mechanical hand counter, count the cells in each set of sixteen smaller grids. To avoid over counting, count those cells that touch the grid lines on the left and top boundaries. Do not count those cells that touch the grid lines on the right and bottom boundaries.

7. To determine the number of red blood cells per cubic millimeter of blood, add the number of cells counted in the five grid areas and then add four zeros to the end of the number, i.e., multiply by 10,000.

8. Once you have finished your count, place your Unopette for red blood count into the bio-hazard container.

9. Record your total red blood cell count below.

BLOOD TYPING

Antigens located on the surface of red blood cells determine the type of blood you have. We will be looking for the presence of A, B, Rh, M, and N antigens. For example, if you have A antigens on your red blood

cells, you have type A blood. If you have B antigens on your red blood cells, you have type B blood. If you have both of these antigens, you have type AB blood. If you have neither of these antigens present, you have type O blood.

In the U.S. white population, 45% have type O blood, 41% have type A blood, 10% have type B blood, and 4% have type AB blood. In the U.S. black population, 47% have type O blood, 28% have type A blood, 20% have type B blood, and 5% have type AB blood.

In the U.S. white population, 85% have Rh positive blood and 15% have Rh negative blood. In the U.S. black population, 88% have Rh positive blood and 12% have Rh negative blood.

Twenty percent of the population has the M antigen. Thirty percent of the population has the N antigen. Fifty percent of the population has both the M and N antigens.

Exercise 26.3

Materials:

3 clean microscope slides
Cotton ball soaked in alcohol
Dry cotton balls
Sterile disposable lancet
5 toothpicks
Typing sera - Anti-A, Anti-B, Anti-Rh, Anti-M, Anti-N
Wax pencil
Slide warming box

ABO TYPING

1. On one end of a clean microscope slide place a drop of anti-A serum and mark the corner of the slide with an "A." On the other end of the slide place a drop of anti-B serum and mark the corner of the slide with a "B."

2. Scrub a finger with alcohol. Stick the finger with a sterile lancet. Immediately after using the lancet, place it in the bio-hazard container. Any disposable object contaminated with blood should be placed into the bio-hazard container.

3. Touch your finger, that has a large drop of blood on the end of it, to the drop of anti-A serum. Wipe your finger with the alcohol ball and dry with a cotton ball. Stir the anti-A and blood mixture with a toothpick.

4. Touch your finger, that has a large drop of blood on the end of it, to the drop of anti-B serum. Wipe your finger with the alcohol ball and dry with a cotton ball. Stir the anti-B and blood mixture with a toothpick.

5. Place the microscope slide on the slide warming box. Rock the box gently and observe the slide for clumping. If the blood clumps in the anti-A serum, you have type A blood. If the blood clumps in the anti-B serum, you have type B blood. If both clump, you have type AB blood. If neither clump, you have type O blood.

6. Place your microscope slide into the bio-hazard container.

Rh TYPING

1. Take a second clean microscope slide and place a drop of anti-Rh serum on the slide.

2. Touch your finger, that has a large drop of blood on the end of it, to the drop of anti-Rh serum. Wipe your finger with the alcohol ball and dry with a cotton ball. Stir the anti-Rh and blood mixture with a clean toothpick.

3. Place the microscope slide on the slide warming box. Rock the box gently and observe the slide for clumping. If the blood clumps in the anti-Rh serum within two minutes, you have Rh positive blood.

4. Place your microscope slide into the bio-hazard container.

MN TYPING

1. Take a third clean microscope slide and place a drop of anti-M serum on one end of the slide and mark the corner of the slide with a "M." On the other end of the slide place a drop of anti-N serum and mark the corner of the slide with a "N."

2. Touch your finger, that has a large drop of blood on the end of it, to the drop of anti-M serum. Wipe your finger

with the alcohol ball and dry with a cotton ball. Stir the anti-M and blood mixture with a toothpick.

3. Touch your finger, that has a large drop of blood on the end of it, to the drop of anti-N serum. Wipe your finger with the alcohol ball and dry with a cotton ball. Stir the anti-N and blood mixture with a toothpick.

4. Place the microscope slide on the slide warming box. Rock the box gently and observe the slide for clumping. If the blood clumps in the anti-M serum, you have M antigens on your red blood cells. If the blood clumps in the anti-N serum, you have N antigens on your red blood cells. If both clump, you have both M and N antigens on your red blood cells.

5. Place your microscope slide into the bio-hazard container.

Record the type of antigens that you have on your red blood cells below.

HEMOGLOBIN DETERMINATION

Each red blood cell contains millions of molecules of hemoglobin. Hemoglobin is necessary for the transport of oxygen to the cells of the various tissues of the body. Inadequate hemoglobin or insufficient numbers of red blood cells results in a condition known as anemia.

The hemoglobin content of the blood is expressed in grams per 100 milliliters (ml) of blood. **The range of values for a female is 12 to 16 grams per 100 milliliters of blood. The range of values for a male is 13 to 17 grams per 100 milliliters of blood.**

Exercise 26.4

Materials:

Cotton ball soaked in alcohol
Dry cotton ball
Sterile disposable lancet
Hemoglobinometer
Hemolysis applicator

- 1. The blood chamber of the hemoglobinometer consists of a metal clip, a flat glass cover plate, and an H-shaped glass moat. The blood is to be placed on the raised center portion of the H-shaped moat. There is a second raised center portion on the opposite side.*
- 2. Place moat plate and cover plate into the metal clip so that the H-shaped moat is on the bottom. Push the flat glass cover plate all the way into the metal clip. The H-shaped moat should be inserted only half way into the metal clip.*
- 3. Scrub a finger with alcohol. Stick the finger with a sterile lancet. Immediately after using the lancet, place it in the bio-hazard container. Any disposable object contaminated with blood should be placed into the bio-hazard container.*
- 3. Touch your finger, that has a large drop of blood on the end of it, to the raised center portion of the H-shaped moat.*
- 4. Hemolyze (break down) the blood on the raised center portion of the H-shaped moat by gently rolling the pointed end of the hemolysis applicator in the blood for 45 seconds. Care should be used not to "slop" any of the blood into the moat. At the end of 45 seconds, the blood should no longer be cloudy, but should be transparent in appearance.*
- 5. Push the bottom slide containing the H-shaped moat into the metal clip. At this time, blood will remain on the raised center portion of the H-shaped moat and excess blood will flow into the moat. Using a quick motion, wipe the edges of the two pieces of glass to remove any blood on the outside of them.*
- 6. Place the blood chamber into the side of the hemoglobinometer.*
- 7. Hold the hemoglobinometer in your left hand so that your left thumb is free to push the light switch button on the bottom of the hemoglobinometer.*
- 8. Place the eyepiece of the hemoglobinometer to your eye and push the light switch button with your left thumb. Using your right hand, move the slide button on the side of the hemoglobinometer back and forth until the two*

halves of the split green field are of the same intensity (Note: intensity, not color).

9. Observe the side of the hemoglobinometer and note where the index mark of the slide button indicates the grams of hemoglobin per 100 milliliters of blood. Record your results below.

10. Remove the chamber from the hemoglobinometer and thoroughly wash it with soap and water. Dry the chamber and return it to its case.

HEMATOCRIT

The hematocrit is a measurement of the percentage of packed red blood cells in the blood. Like the hemoglobin determination, the hematocrit may also be used to determine if an individual is anemic.

The normal range of values for a female is 36% to 46%. The normal range of values for a male is 38% to 50%. If the hematocrit of an individual is 45%, this indicates that 45% of his whole blood is red cells and 55% is plasma.

Exercise 26.5

Materials:

Cotton ball soaked in alcohol
Sterile disposable lancet
Heparinized (anti-coagulant) capillary tube
White plastic sealant
Hematocrit centrifuge
Hematocrit capillary tube reader

1. Scrub a finger with alcohol. Stick the finger with a sterile lancet. Immediately after using the lancet, place it in the bio-hazard container. Any disposable object contaminated with blood should be placed into the bio-hazard container.

2. The heparinized capillary tube has a black ring approximately 1/2" from one end of the tube. The end of the heparinized capillary tube farthest away from the black line should be placed into a drop of blood on the end of your finger. Place the heparinized capillary tube into the

blood at an angle slightly above horizontal. Capillary action will pull the blood into the heparinized capillary tube. Fill the tube to the black line.

3. Remove the plastic covering from the sealant, seal the end of the heparinized tube that was placed into the blood by pushing it into the white plastic sealant.

4. Place the heparinized capillary tube into the hematocrit centrifuge with the sealed end of the heparinized capillary tube against the rubber-cushioned end of the centrifuge slot.

5. Your instructor will operate the hematocrit centrifuge.

6. After the hematocrit centrifuge has spun for approximately four minutes, your instructor will demonstrate the technique necessary to read the heparinized capillary tube using the hematocrit capillary tube reader.

7. Place your heparinized capillary tube into the bio-hazard container.

8. Record your hematocrit reading below.

COAGULATION TIME

The process of blood clotting is called **coagulation**. Coagulation time is the length of time that it takes for blood to clot once it is drawn into a tube. **Coagulation time is usually between 2 and 6 minutes.**

Exercise 26.6

Materials:

Cotton ball soaked in alcohol
Sterile disposable lancet
Non-heparinized capillary tube
Three cornered file

1. Scrub a finger with alcohol. Stick the finger with a sterile lancet. Immediately after using the lancet, place it in the bio-hazard container. Any disposable object contaminated with blood should be placed into the bio-hazard container.

2. *The non-heparinized capillary tube has a blue ring approximately 1/8" from one end of the tube. The end of the non-heparinized capillary tube closest to the blue line should be placed into a drop of blood on the end of your finger. Record the time to the second. Place the non-heparinized capillary tube into the blood at an angle slightly above horizontal. If blood fails to fill the tube, lower the end away from the finger so that gravity will assist the capillary action. Fill the tube to the very end.*

3. *Exactly two minutes after blood first entered the non-heparinized capillary tube, use the three cornered file to make a small scratch (score) on the tube approximately 1/2" from the end of the tube farthest away from the blue line. At the two and one half minute mark, point the score mark away from you and apply gentle even pressure on either side of the score mark. Pressure may be applied by holding the non-heparinized tube with a thumb and index finger on either side of the score mark. Look for a thread of clotted blood between the two broken ends of the tube.*

4. *If no thread of clotted blood appears, immediately make another score mark on the non-heparinized capillary tube approximately 1/2" from the end of the tube farthest away from the blue line. At the three minute mark, apply gentle even pressure on either side of the score mark. Look for a thread of clotted blood between the two broken ends of the tube.*

5. *Continue this procedure at thirty second intervals until a thread of clotted blood appears between the two broken ends of the tube.*

6. *Place all sections of your non-heparinized capillary tube into the bio-hazard container.*

7. *Record your coagulation time below.*

White Blood Cell Identification

There are five major types of white blood cells: neutrophils, eosinophils, basophils, lymphocytes, and monocytes. **Neutrophils** have a nucleus with three to five lobes and fine pale light blue cytoplasmic granules (when properly stained). They make up 45% to 75% of the total white blood

cell count. **Eosinophils** have a two lobed nucleus and red cytoplasmic granules. They make up 0% to 5% of the total white blood cell count. **Basophils** have an irregularly shaped nucleus and dark purple cytoplasmic granules that usually obscure the nucleus. They make up less than 2% of the total white blood cell count. **Lymphocytes** have a nucleus that is almost completely round with a thin layer of cytoplasm surrounding it. They make up 20% to 45% of the total white blood cell count. **Monocytes** have a kidney shaped nucleus. They make up 2% to 8% of the total white blood cell count.

Exercise 26.7

Use your textbook to identify the blood cells shown in Figure 26.2.

Examine prepared microscope slides of blood that have been stained with Wright's stain. Identify and sketch the five major types of white blood cells.




Figure 26.2 Blood Cell Types

Basophil Eosinophil Erythrocytes Lymphocyte Monocyte Neutrophil Thrombocytes

CHAPTER 27
THE HEART

HEART ANATOMY

Location of the Heart

The heart is situated in the anterior, inferior **mediastinum**. The mediastinum is a cavity located between the right and left pleural cavities. The **apex** or pointed end of the heart is directed toward the left hip and lies on the diaphragm. The apex is located between the fifth and sixth rib and lies about 7 to 9 centimeters to the left of the midline. The **base** or broad end of the heart is directed toward the right shoulder and lies just below the second rib.

Blood Flow Through the Heart

Deoxygenated blood is returned to the heart from the arms and head by a large vein called the **superior vena cava**. Deoxygenated blood is returned to the heart from the legs and trunk by a large vein called the **inferior vena cava**. The blood empties into a chamber called the **right atrium**. Upon contraction of the right atrium, blood flows over a valve called the **tricuspid valve**. This valve consists of three cusps or flaps. Attached to the inferior aspect of the tricuspid valve are fine tendon-like cords called **chordae tendineae**. The chordae tendineae attach to **papillary muscles** located in the **right ventricle**. The papillary muscles are made up of cardiac muscle fibers.

Upon contraction of the right ventricle, blood flows over a valve called the **pulmonary semilunar valve**. This valve is made up of three half-moon-shaped cusps. After passing through the pulmonary semilunar valve, the blood enters the **pulmonary trunk**. The pulmonary trunk divides into the **right pulmonary artery** and the **left pulmonary artery**. These two arteries take blood to the lungs to be oxygenated.

After oxygenation, the blood is returned to the heart by four veins called **pulmonary veins** that empty into the **left atrium**. Two of these veins enter each side of the left atrium. Upon contraction of the left atrium, blood flows over a valve called the **mitral valve**. This valve consists of two cusps or flaps. Attached to the inferior aspect of the mitral valve are **chordae tendineae** attached to **papillary muscles**.

Upon contraction of the **left ventricle**, blood flows over a valve called the **aortic semilunar valve**. This valve is made up of three half-moon-shaped cusps. After passing over the aortic semilunar valve, the blood enters the **aorta**. The aorta is the largest artery in the body and is responsible for blood distribution to the various body structures. The portion of the aorta just past the aortic semilunar valve is called the **ascending aorta**. It curves to the left forming the **aortic arch**. The aortic arch then descends and is called the **descending aorta**.

Originating from the aortic arch are three arteries. These three arteries distribute blood to the arms and the head. The one closest to the right side of the heart is called the **innominate artery**. The middle one is called the **left common carotid artery**. The one closest to the left side of the heart is called the **left subclavian artery**.

Connecting the aortic arch and the pulmonary trunk is a ligament called the **ligamentum arteriosum**. The ligamentum arteriosum is the remains of a fetal structure called the ductus arteriosus (see chapter 29).

Coronary Circulation

Coronary circulation is responsible for the distribution of oxygenated blood to the myocardium (cardiac muscle). Originating from the aorta just past the aortic semilunar valve are the **openings to the coronary arteries**. One of these openings leads to the **right coronary artery**. The right coronary artery has two main branches: the **posterior interventricular artery**, which supplies the posterior walls of the two ventricles of the heart, and the **marginal artery**, which supplies the right lateral aspect of the heart. The second of the coronary arteries is the **left coronary artery**. The left coronary artery has two main branches: the **left anterior descending artery**, which supplies the anterior walls of the two ventricles of the heart, and the **circumflex artery**, which supplies the left lateral aspect of the heart.

After the blood has passed through the myocardium, the deoxygenated blood is collected by a large vein, the **coronary sinus**. The coronary sinus empties into the right atrium. There are two primary veins that empty into the coronary sinus: the **great cardiac vein**, which drains the anterior aspect of the heart, and the **middle cardiac vein**, which drains the posterior aspect of the heart.

The Coverings and Wall of the Heart

There are three layers constituting the wall and coverings of the heart, the pericardium, the myocardium and the endocardium. The majority of the anterior surface and approximately half of the posterior surface of the heart is covered by the **pericardium**. The pericardium is a double walled serous membrane. The outer wall is called the **parietal pericardium**. The inner layer is called the **epicardium** or **visceral pericardium**. Between the epicardium and parietal pericardium is a small space called the **pericardial cavity**. The pericardial cavity contains a serous fluid that is secreted by the epicardium. The epicardium also serves as the outermost wall of the heart.

The middle and thickest layer of the heart is the **myocardium** or cardiac muscle. The myocardium of the left ventricular wall is thicker than the myocardium of the right ventricular wall. The myocardium between the two ventricles is called the **interventricular septum**.

The innermost layer is called the **endocardium**. The endocardium is a serous membrane that is continuous with the endothelium of the arteries and veins. The endocardium also covers the valves of the heart.

Blood Pressure

With each contraction of the ventricles, blood is forced into the arteries of the body. The force with which the blood is pushing against the artery walls when the ventricles are contracting is known as the **systolic pressure**. The systolic pressure averages 120 millimeters of mercury (mm Hg). The pressure that results in the arteries when the ventricles are relaxed is known as the **diastolic pressure**. The diastolic pressure indicates

the lowest, constant pressure or strain on the vessel wall. The diastolic pressure averages 80 mm Hg.

Exercise 27.1

Stethoscope Method of Blood Pressure Determination

Materials:

Stethoscope

Sphygmomanometer

- 1. Wrap the sphygmomanometer cuff around your lab partner's upper arm, which should be resting on the lab table.*
 - 2. Make sure the metering valve on the bulb of the sphygmomanometer is closed.*
 - 3. Pump up the sphygmomanometer cuff. While watching the sphygmomanometer gauge, inflate the cuff to about 180 mm Hg.*
 - 4. Place the bell of the stethoscope just below the sphygmomanometer and midway between the epicondyles of the humerus. At this point, you will be listening to sounds in the brachial artery.*
 - 5. Slowly release the air from the sphygmomanometer cuff by loosening the valve on the bulb.*
 - 6. While watching the sphygmomanometer gauge, listen for the sound of blood as it passes through the brachial artery. When you hear this sound, note the location of the needle on the gauge. This is the systolic pressure.*
 - 7. Continue observing the sphygmomanometer gauge while listening to the sounds through the stethoscope. When you are no longer able to detect a sound, note the location of the needle on the gauge. This is the diastolic pressure.*
 - 8. Lab partners should change positions and repeat the above procedure.*
 - 9. Record your systolic pressure below.*
-

10. Record your diastolic pressure below.

Exercise 27.2

Figure 27.1 shows a view of the internal anatomy of the heart. Using your textbook as a guide, fill in the labels on the figure.

Figure 27.2 shows an anterior and a posterior view of the heart. Using your textbook as a guide, fill in the labels on the figure.

Exercise 27.3

Study the model of the heart. Identify the following structures on the model: aorta, aortic semilunar valve, apex, base, chordae tendineae, circumflex artery, coronary sinus, inferior vena cava, innominate artery, interventricular septum, left anterior descending artery, left atrium, left common carotid artery, left coronary artery, left pulmonary artery, left subclavian artery, left ventricle, mitral valve, myocardium, opening to the coronary sinus, papillary muscle, pulmonary semilunar valve, pulmonary trunk, right atrium, right coronary artery, right pulmonary artery, right ventricle, superior vena cava, and tricuspid valve.

Exercise 27.4

Identify the following structures on the sheep heart: aortic semilunar valve, apex, base, chordae tendineae, interventricular septum, left atrium, left ventricle, mitral valve, myocardium, papillary muscle, pulmonary semilunar valve, right atrium, right ventricle, and tricuspid valve.

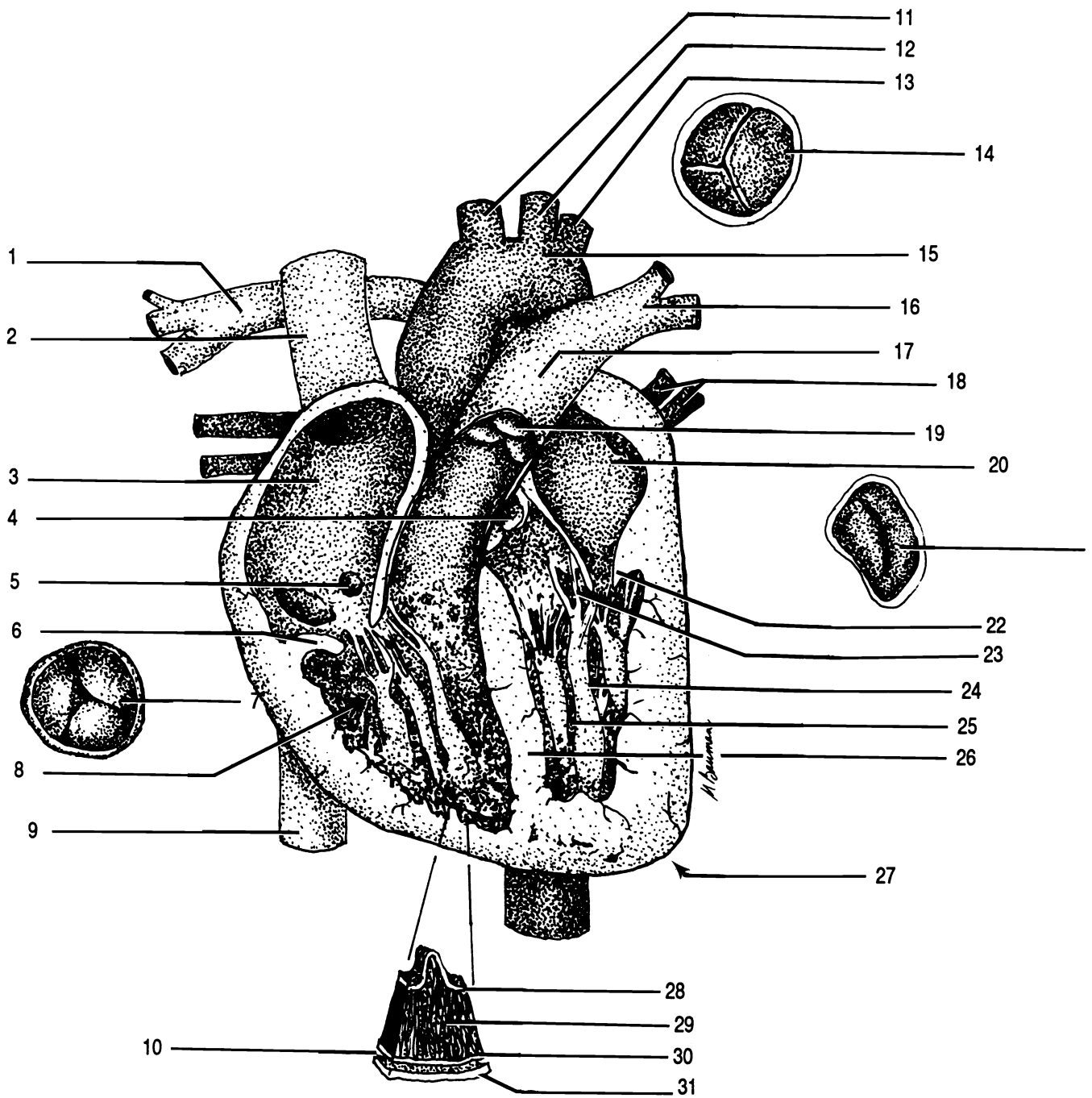
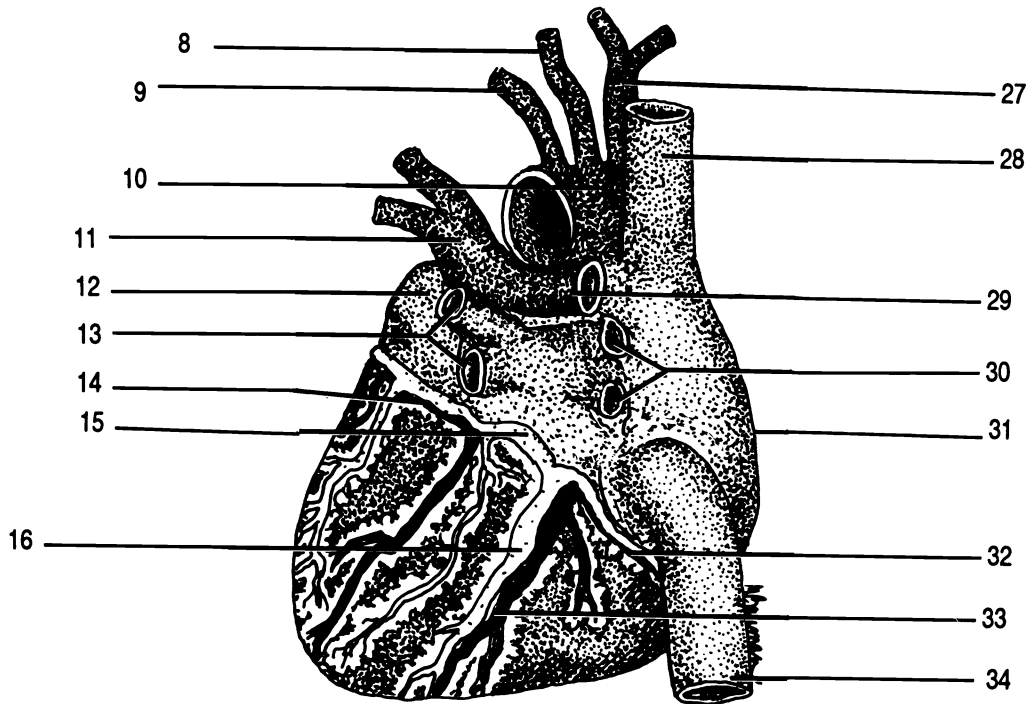
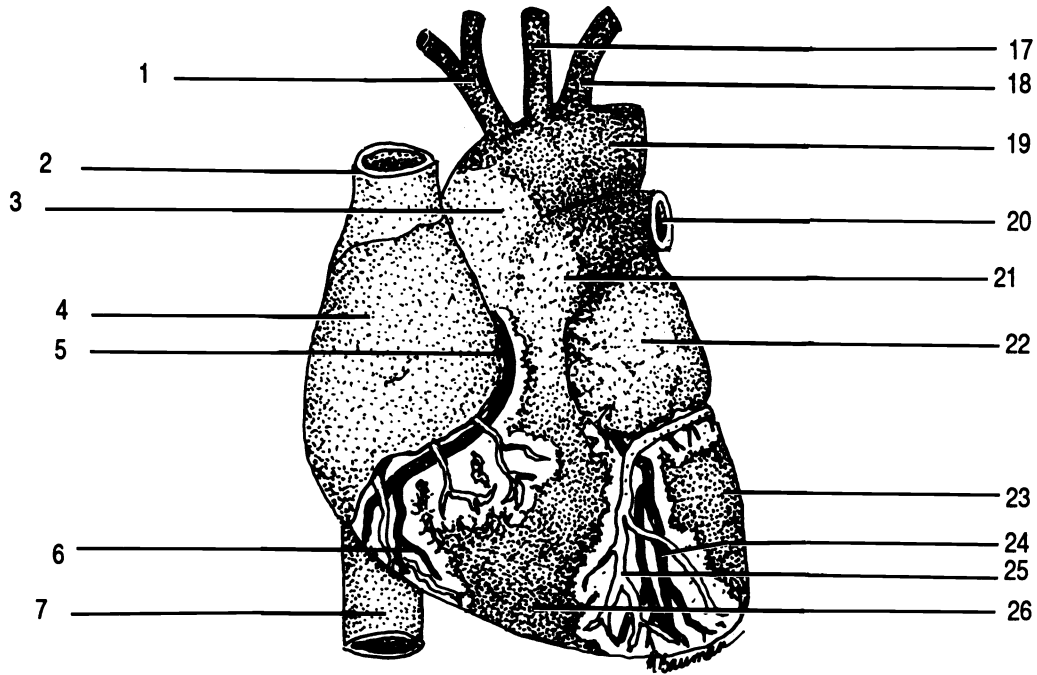


Figure 27.1 Internal Anatomy of the Heart

Aorta Aortic semilunar valve Apex Chordae tendineae Endocardium Epicardium (Visceral pericardium)
 Inferior vena cava Innominate artery Interventricular septum Left atrium Left common carotid artery
 Left pulmonary artery Left subclavian artery Left ventricle Mitral valve (X2) Myocardium Opening to coronary sinus
 Papillary muscle Parietal pericardium Pericardial cavity Pulmonary semilunar valve Pulmonary trunk
 Pulmonary veins Right atrium Right pulmonary artery Right ventricle Semilunar valve Superior vena cava
 Tricuspid valve (X2)

Figure 27.2 External Anatomy of the Heart

ANTERIOR VIEW: Aortic arch Ascending aorta Great cardiac vein Inferior vena cava Innominate artery
 Left anterior descending artery Left atrium Left common carotid artery Left pulmonary artery Left subclavian artery
 Left ventricle Marginal artery Pulmonary trunk Right atrium Right coronary artery Right ventricle
 Superior vena cava



POSTERIOR VIEW: Aortic arch Circumflex artery Coronary sinus Inferior vena cava Innominate artery Left atrium
 Left common carotid artery Left pulmonary artery Left pulmonary veins Left subclavian artery Middle cardiac vein
 Posterior interventricular artery Right atrium Right coronary artery Right pulmonary artery Right pulmonary veins
 Superior vena cava

CHAPTER 27 REVIEW

1. _____ Name the three arteries that originate from the aortic arch.
2. _____
3. _____
4. _____ After blood has passed over the mitral valve, the blood will enter the (4) (chamber).
5. _____ Name the two layers that make up the covering of the heart.
6. _____
7. _____ What structure of the heart is located between the fifth and six ribs and 7 to 9 centimeters left of the midline?
8. _____ The scientific name for cardiac muscle is (8).
9. _____ What is the name of the partition that separates the two ventricles?
10. _____ Name the two main branches of the left coronary artery.
11. _____
12. _____ Name the two large veins that return blood to the heart after the blood has circulated to the various body structures.
13. _____
14. _____ Name the two valves of the heart that have chordae tendineae and papillary muscle associated with them.
15. _____
16. _____ Give the scientific location of the heart.
17. _____ Name the three layers that make up the wall of the heart.
18. _____
19. _____

20. _____ Name the four chambers of the heart.
21. _____
22. _____
23. _____
24. _____ The constant pressure or strain that an artery must withstand is known as the (24) pressure.
25. _____ When using the arm to take a blood pressure, what artery is used?

ARTERIES AND VEINS

Arteries

Arteries are blood vessels that take blood away from the heart.

The largest artery, the **aorta** arises from the left ventricle of the heart. The first portion is known as the **ascending aorta** since it travels upward. The ascending aorta curves to the left. This curved portion is known as the **aortic arch**. The aortic arch curves downward to form the **descending aorta**.

Arising from the aortic arch are three arteries: the **innominate artery**, the **left common carotid artery**, and the **left subclavian artery**. The one closest to the right side of the heart is the **innominate artery**. The middle one is the **left common carotid artery**. The left common carotid artery supplies the left side of the head. The artery closest to the left side of the heart is called the **left subclavian artery**.

The innominate artery branches to form the **right subclavian artery** and the **right common carotid artery**. The **right subclavian artery** passes behind the right clavicle. In the axilla (armpit), it becomes the **axillary artery**. The axillary artery in turn becomes the **brachial artery** in the upper arm. At the level of the elbow, the brachial artery branches to form the **radial artery** and the **ulnar artery** which follow the radial bone and ulnar bone respectively. The **right common carotid artery** supplies the right side of the head.

The left subclavian artery passes behind the left clavicle. In the axilla, it becomes the **axillary artery**. The axillary artery in turn becomes the **brachial artery** in the upper arm. At the level of the elbow, the brachial artery branches to form the **radial artery** and the **ulnar artery** which follow the radial bone and ulnar bone respectively.

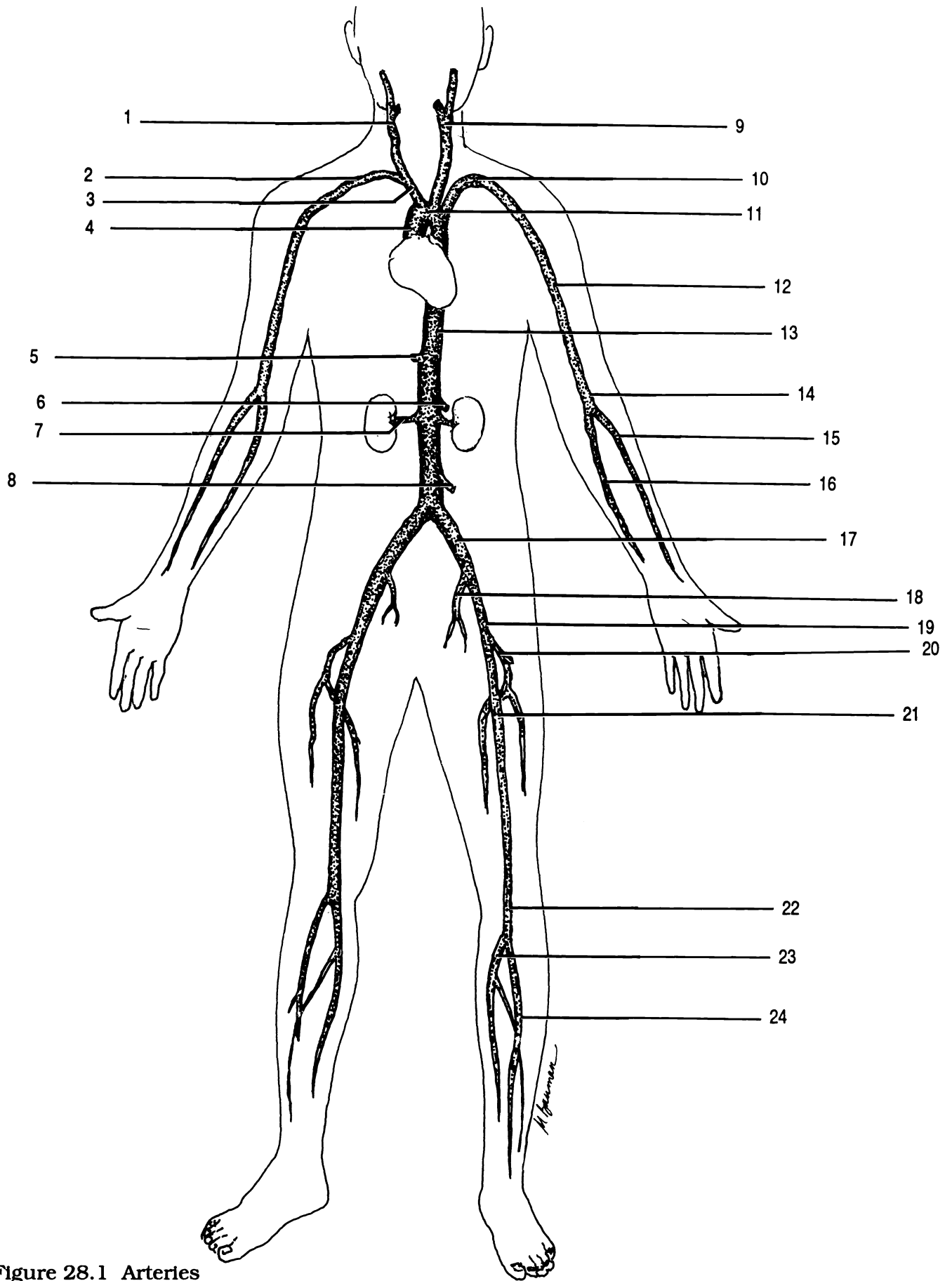


Figure 28.1 Arteries

Anterior tibial artery Aortic arch Ascending aorta Axillary artery Brachial artery Celiac artery Common iliac artery
 Deep femoral artery Descending aorta External iliac artery Femoral artery Inferior mesenteric artery
 Innominate artery Internal iliac artery Left common carotid artery Left subclavian artery Popliteal artery
 Posterior tibial artery Radial artery Renal artery Right common carotid artery Right subclavian artery
 Superior mesenteric artery Ulnar artery

The descending aorta passes through the thoracic cavity and is sometimes called the **thoracic aorta**. After passing through the diaphragm, it is called the **abdominal aorta**. The first branch off the abdominal aorta is a single artery called the **celiac artery**. The celiac artery has branches that supply the stomach, liver, and spleen. The second branch off the abdominal aorta just below the celiac artery is a single artery called the **superior mesenteric artery**. The superior mesenteric artery primarily supplies the small intestine. Inferior to the superior mesenteric artery are the paired **renal arteries** which supply the kidneys. Inferior to the renal arteries is a single artery called the **inferior mesenteric artery** which supplies the large intestine.

In the lumbar region, the abdominal aorta divides to form the **right and left common iliac arteries**. Each common iliac artery divides to form a smaller branch known as the **internal iliac artery** and a larger branch known as the **external iliac artery**. The external iliac artery continues down the leg and divides to form the **femoral artery** which supplies the thigh. At the origin of the femoral artery, the **deep femoral artery** branches off and goes medially. The femoral artery continues down the medial and posterior side of the thigh to the back of the knee where it becomes the **popliteal artery**. Just below the knee the popliteal artery divides to form the **anterior tibial artery** and the **posterior tibial artery**.

Veins

Veins are blood vessels that take blood to the heart.

The **superior vena cava** returns blood to the heart from the arms and head. The **inferior vena cava** returns blood to the heart from the legs and trunk.

In each side of the neck, three veins come together. Medially located in the neck is the large **internal jugular vein**. Laterally located in the neck is the smaller **external jugular vein**. These two veins join with the **subclavian vein** to form the **innominate vein**. The two innominate veins come together to form the superior vena cava.

Each subclavian vein is formed by the union of two veins: the cephalic vein and the axillary vein. The **cephalic vein** is located laterally in the upper arm.

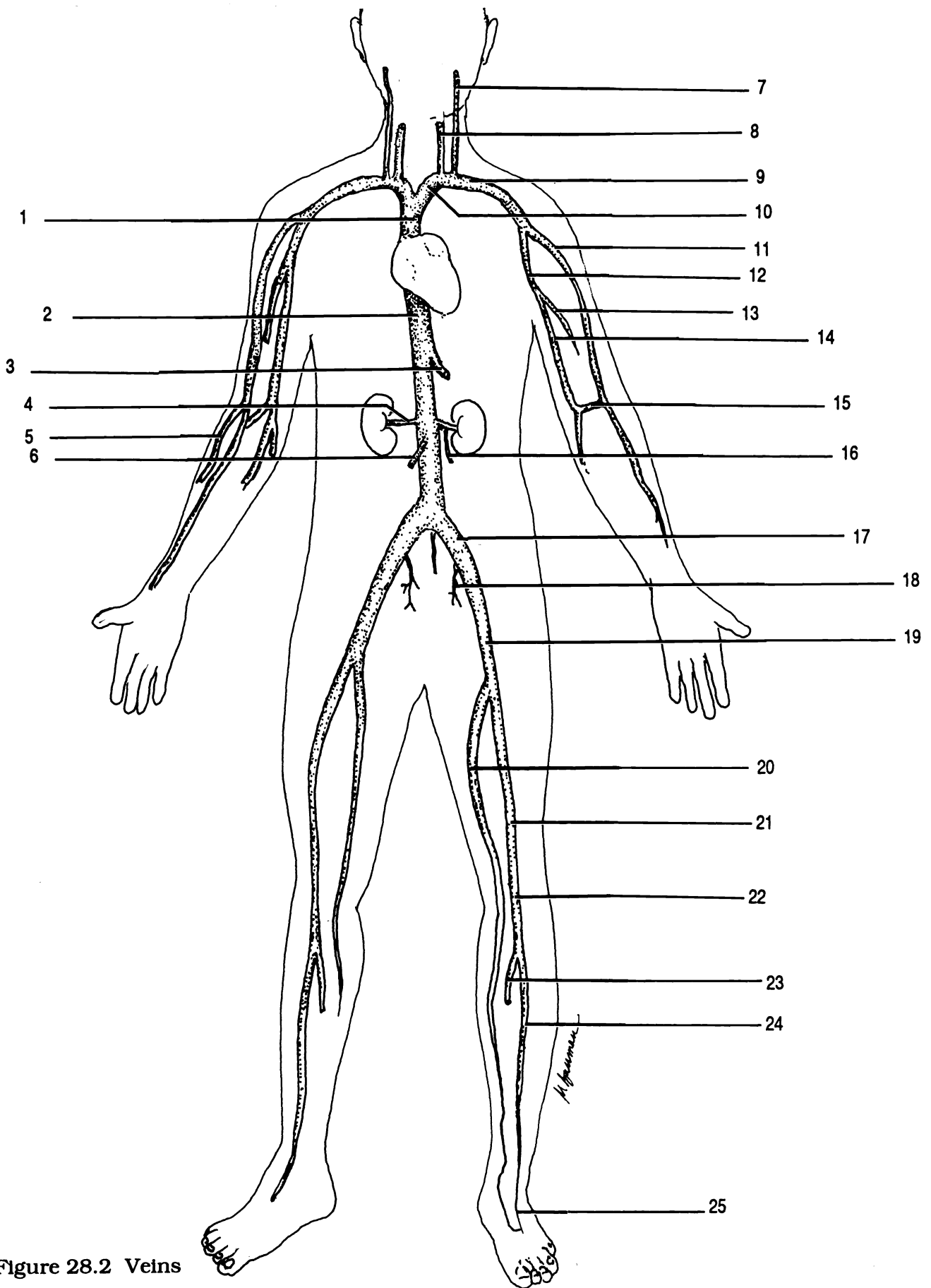


Figure 28.2 Veins

Accessory cephalic vein Anterior tibial vein Axillary vein Basilic vein Brachial vein Cephalic vein
 Common iliac vein Dorsal venous arch External iliac vein External jugular vein Femoral vein Great saphenous vein
 Hepatic vein Inferior vena cava Innominate vein Internal iliac vein Internal jugular vein
 Left spermatic or ovarian vein Median cubital vein Popliteal vein Posterior tibial vein Renal vein
 Right spermatic or ovarian vein Subclavian vein Superior vena cava

The **axillary vein** is located in the axilla of the arm. The axillary vein is formed by the union of the **basilic vein**, which lies on the medial side of the arm, and by the **brachial vein**, which lies along the posterior surface of the arm. Between the basilic vein and cephalic vein, in the elbow area, is the **median cubital vein**. Emptying into the cephalic vein in the elbow area is the **accessory cephalic vein**, which lies on the lateral aspect of the forearm.

The inferior vena cava is formed primarily by the union of the two **common iliac veins** in the lower lumbar/sacral area. Two veins form the common iliac vein: a smaller internal iliac vein and a larger external iliac vein. The **internal iliac vein** basically corresponds to the internal iliac artery. The **external iliac vein** receives blood from the lower leg. Emptying into the external iliac vein are two veins: the great saphenous vein and the femoral vein. The **great saphenous vein**, which is the longest vein in the body, begins at the medial end of the **dorsal venous arch** of the foot and travels up the medial aspect of the leg. The **femoral vein** runs up the posterior aspect of the thigh. The femoral vein is an upward continuation of the **popliteal vein**, which is located behind the knee. The popliteal vein receives blood from the **anterior tibial vein** and the **posterior tibial vein**.

In the abdomen, the inferior vena cava receives blood from the **hepatic veins**, which drain blood from the liver. The **renal veins** are inferior to the hepatic veins and drain the kidneys. The left renal vein also receives blood from the **left spermatic or ovarian vein**. The **right spermatic or ovarian vein** empties directly into the inferior vena cava. The spermatic or ovarian veins carry blood away from the testes and ovaries, in males and females respectively.

Hepatic Portal Circulation

Hepatic portal circulation consists of veins that drain blood from the intestines, stomach, spleen, pancreas, and gallbladder and empty into the **hepatic portal vein** which directs blood to the liver. The hepatic portal vein is formed by the union of the **superior mesenteric vein** and the **splenic vein**. The superior mesenteric vein drains the small intestine and portions of the large intestine and stomach. The splenic vein drains the spleen and also receives blood from the stomach (by way of the gastric, pyloric, and gastroepiploic veins), pancreas (by way of the pancreatic veins), and portions of the colon (by way of the inferior mesenteric vein). The blood, after traveling through the liver, enters the hepatic veins which empty into the inferior vena cava.

Exercise 28.1

Figure 28.1 show the arteries of the human. Using your textbook as a guide, fill in the labels on the figure.

Figure 28.2 show the veins of the human. Using your textbook as a guide, fill in the labels on the figure.

Exercise 28.2

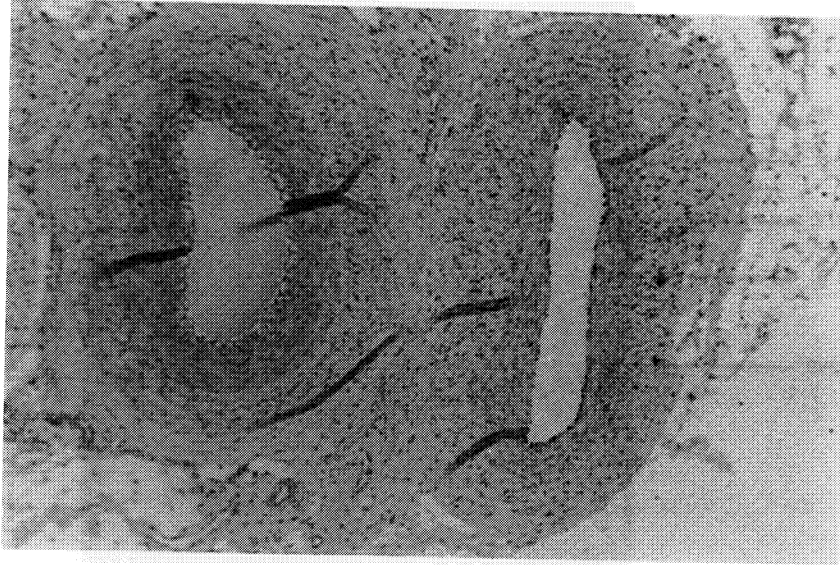
As directed by your instructor, study the arteries and veins on a preserved cat. The locations given above for the human also apply to the cat with two exceptions. The first exception is that the aortic arch has only two arteries: the left subclavian artery and the innominate artery. The innominate artery branches to form the left and right common carotid arteries and the right subclavian artery. The second exception is that the cat does not have a common iliac artery. The internal and external iliac arteries branch off the abdominal aorta.

Identify the following arteries on the cat: abdominal aorta, adrenolumbar artery, aortic arch, ascending aorta, axillary artery, brachial artery, celiac artery, deep femoral artery, descending aorta, external iliac artery, femoral artery, iliolumbar artery, inferior mesenteric artery, innominate artery, internal iliac artery, left common carotid artery, left subclavian artery, pulmonary artery, renal artery, right subclavian artery, right common carotid artery, spermatic or ovarian artery, superior mesenteric artery, and thoracic aorta.

Identify the following veins on the cat: adrenolumbar vein, axillary vein, azygos vein, brachial vein, common iliac vein, deep femoral vein, external iliac vein, external jugular vein, femoral vein, gastrosplenic vein, hepatic portal vein, iliolumbar vein, inferior vena cava, inferior mesenteric vein, innominate vein, internal iliac vein, internal jugular vein, renal vein, spermatic or ovarian vein, subclavian vein, superior vena cava, superior mesenteric vein, and transverse jugular vein.

Exercise 28.3

Examine a prepared microscope slide of a cross section of an artery and vein. Be able to identify an artery and a vein.



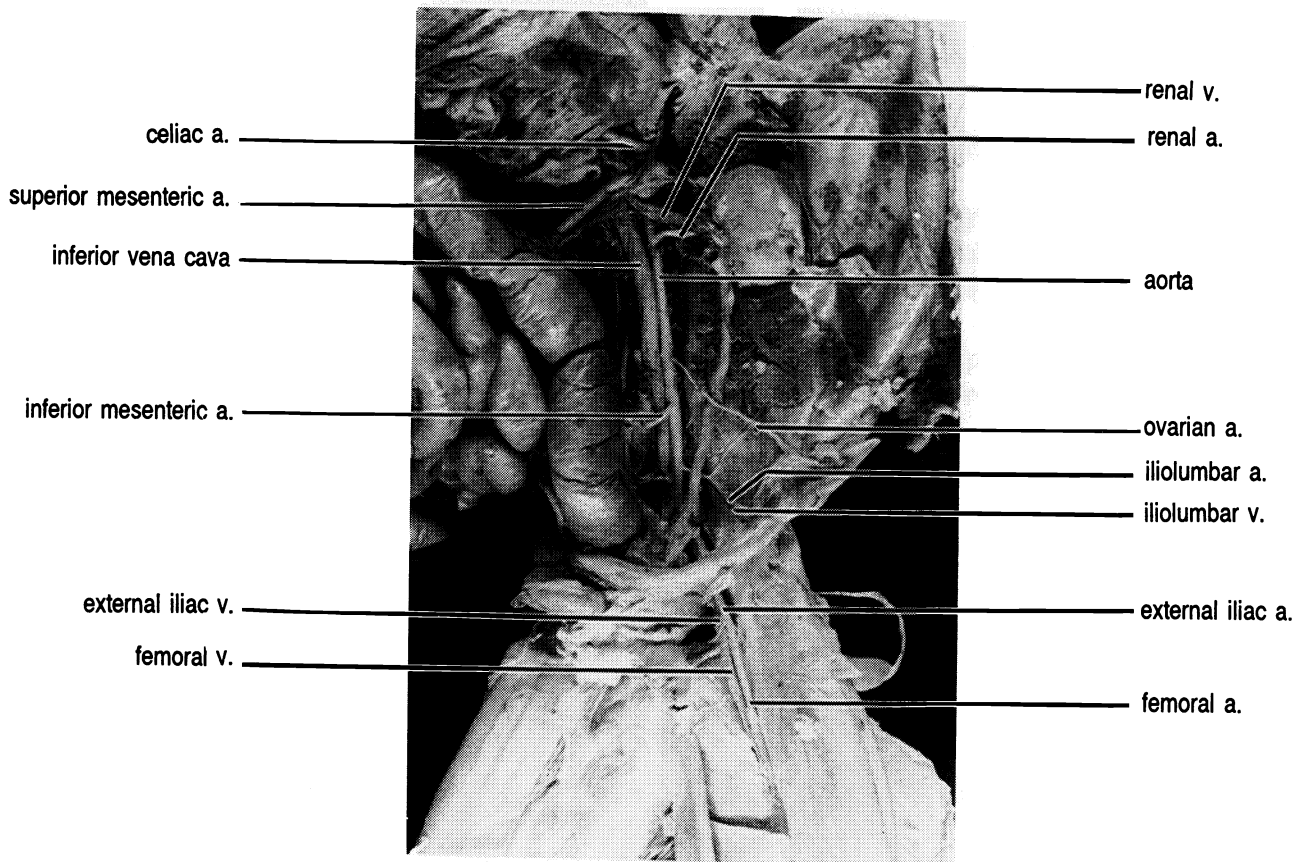
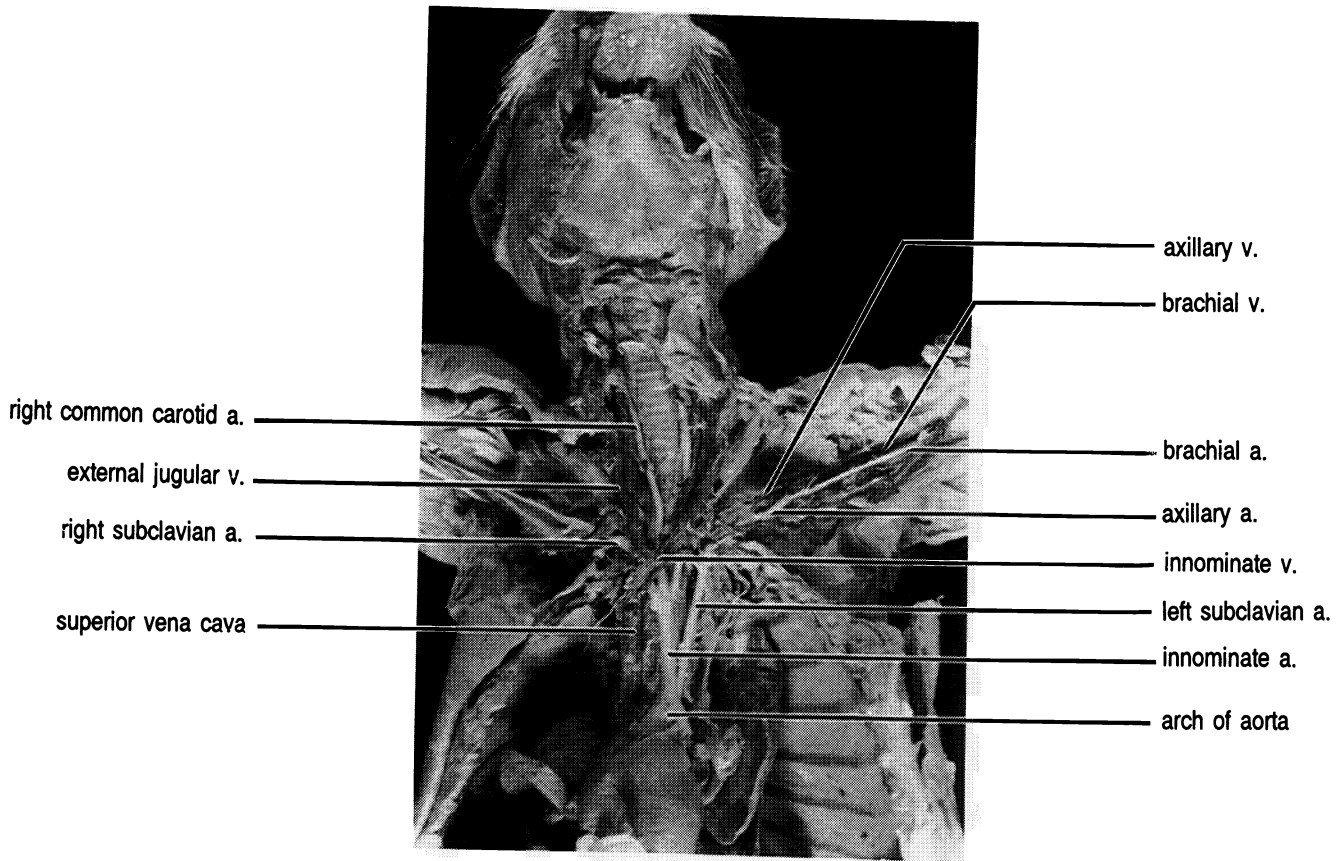
Artery

Vein

Exercise 28.4

*Identify the following vessels on the model of the arm:
axillary artery, brachial artery, median artery, radial
artery, ulnar artery.*

*Identify the following vessels on the model of the leg:
anterior tibial artery, deep femoral artery, external iliac
artery, external iliac vein, femoral artery, femoral vein,
internal iliac artery, popliteal artery, and posterior tibial
artery.*



CHAPTER 28 REVIEW

1. _____ Name the three arteries that originate from the aortic arch.
2. _____
3. _____
4. _____ A vessel that takes blood away from the heart is known as a(n) (4).
5. _____ Name the two veins that come together to form the subclavian vein.
6. _____
7. _____ The subclavian artery branches in the axilla to form the (7) artery.
8. _____ Name the three veins that come together to form the innominate vein.
9. _____
10. _____
11. _____ Name the three unpaired arteries that originate from the abdominal aorta.
12. _____
13. _____
14. _____ Name the vein that is located in the elbow area which connects the basilic vein and cephalic vein.
15. _____ The longest vein in the body is the (15) vein.

FETAL CIRCULATION

Before birth your circulatory system was somewhat different than it is now. The major cause was that before birth your lungs did not contain air and so were not functional.

Instead of acquiring oxygen from the lungs the fetus gets its oxygen and nutrition, and eliminates wastes through the **umbilical cord** which is connected to the **placenta**. The placenta is a specialized structure produced by the embryo which grows into the walls of the uterus during embryonic development. The blood vessels of the placenta are in close association with the blood vessels of the uterus, but there is no mixing of blood cells or large molecules. Small molecules such as oxygen, carbon dioxide, and urea freely diffuse across the placenta-uterine junction. Figure 29.1 shows the circulatory system of the unborn child.

Exercise 29.1

Correctly label the anatomical structures in Figure 29.1.

Blood flows from the placenta through the **umbilical vein** carrying oxygen and nutrients from the mother to the fetus. The umbilical cord enters the fetus at the **umbilicus**. At the liver the umbilical vein becomes the **ductus venosus** which empties into the inferior vena cava. A branch of the umbilical vein joins the hepatic-portal vein to supply the liver, but since the liver is not processing food from the intestines the flow of blood to the liver is not as great as after birth.

Only during the time in the uterus does the right atrium receive oxygenated blood. Since the lungs are non-functional, there is little reason for blood to be pumped to the right ventricle and from there to the lungs. Therefore, a hole, the **foramen ovale**, is present between the right atrium and the left atrium. Oxygenated blood

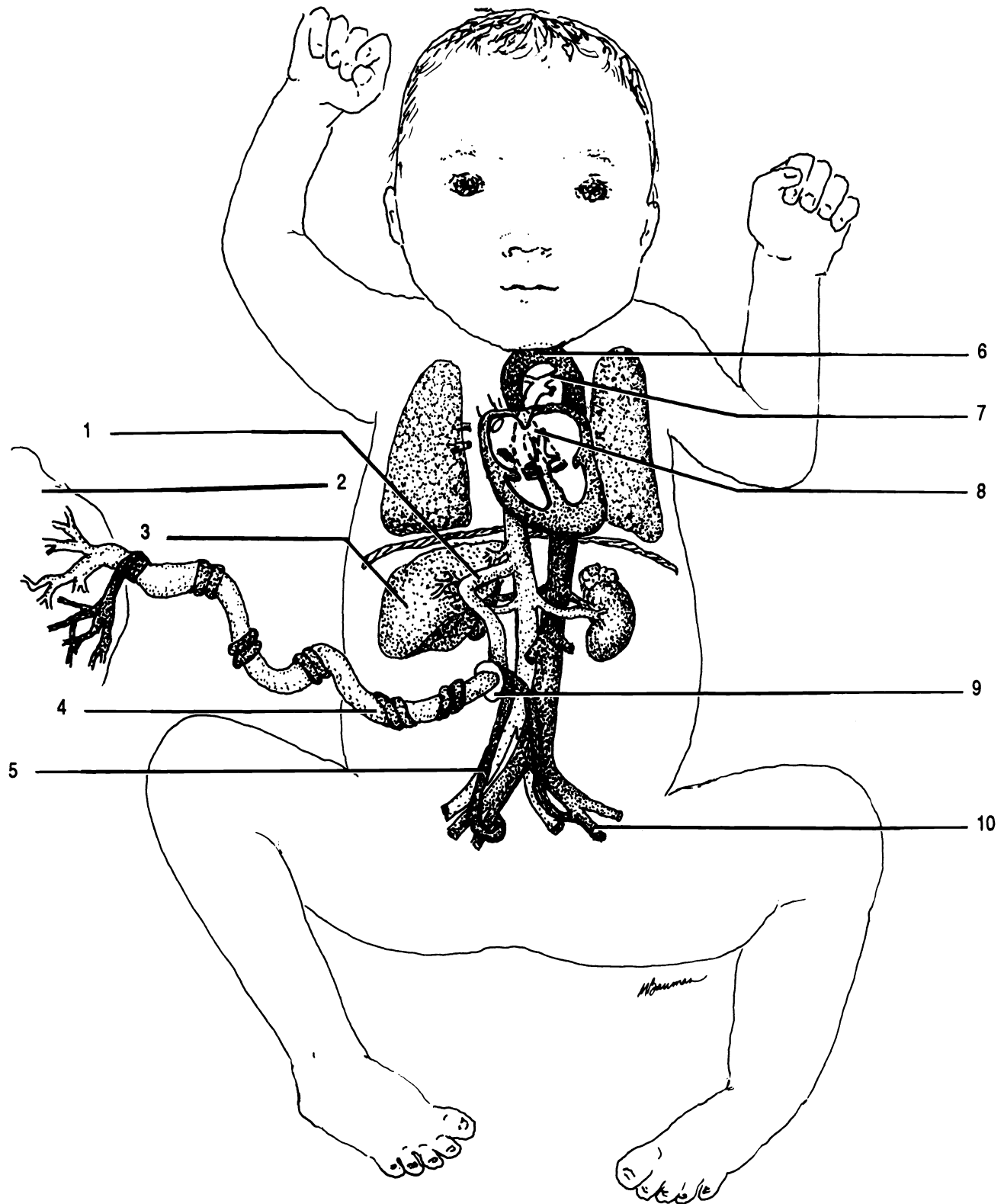


Figure 29.1 Fetal Circulation

Aorta Ductus arteriosus Ductus venosus Foramen ovale Internal iliac artery Liver Placenta Umbilical artery
 Umbilical vein Umbilicus

can then be pumped to the left ventricle and from there to the body through the aorta.

Some blood does travel into the right ventricle and is then pumped out the pulmonary trunk toward the lungs. Most of the blood in the pulmonary trunk is shunted through another special vessel, the **ductus arteriosus**, from the pulmonary artery into the aorta. Thus, only a very small amount of blood travels into the lungs.

Blood flows out of the aorta into the arteries to all parts of the body. The **umbilical arteries** are branches of the internal iliac arteries which carry blood from the fetus to the placenta for the elimination of waste and reoxygenation. The umbilical arteries are twisted around the umbilical vein.

At birth the umbilical arteries, umbilical vein, ductus venosus, and the ductus arteriosus vasoconstrict, atrophy, and become ligaments. For example, the umbilical vein becomes the round ligament of the liver (see chapter 20) and the ductus arteriosus becomes the ligamentum arteriosum (see chapter 27). Shortly after birth the foramen ovale closes to become the **fossa ovalis**, a depression in the interatrial septum.

CHAPTER 29 REVIEW

1. _____ What structure allows blood to flow between atria in the fetus?
2. _____ The ductus arteriosus becomes the (2).
3. _____ What color would you expect the blood in the superior part of the inferior vena cava of the fetus to be?
4. _____ How many umbilical veins are there?
5. _____ Where do the umbilical arteries begin?
6. _____ What special structure shunts blood from the pulmonary artery to the aorta?
7. _____ What physiological event prevents the new born baby from losing blood through the cut umbilical cord?
8. _____ The umbilical cord enters the body through the (8).
9. _____ Who makes the placenta?
10. _____ Which blood vessel becomes the round ligament?

THE LYMPHATIC SYSTEM

The lymphatic system is a system of drainage vessels which return fluid (lymph) from between the cells to the heart. The lymphatic system also slowly delivers fatty substances absorbed by the intestine into the blood. This allows the blood to accommodate lipids which might block the flow of blood if they were taken directly into the blood from the digestive system. Another main function of the lymphatic system is in the immune response fighting microorganisms.

The smallest vessels of the lymphatic system are closed on one end. These microscopic vessels are the **lymphatic capillaries**. The lymph capillaries unite to form **lymphatic vessels** which are shown in Figure 30.1. The lymphatic vessels contain many valves to assure that the lymph in them flows in one direction. Lymphatic vessels flow into **lymph nodes** located primarily in the lumbar region, axillae, neck, and in the serosa of the abdomen. The tonsils are a ring of lymph nodes located in the pharynx. Vessels flowing into a node are termed **afferent lymphatic vessels**. An **efferent lymphatic vessel** exits a lymph node from a depression called a **hilus**.

Within the **medulla**, or central part of the node, the lymph slowly flows through a maze-like arrangement of passageways. The outer layer of the lymph node is the **cortex**. The cortex contains many **germinal centers** where new lymphocytes are produced. The entire lymph node is enclosed in a fibrous **capsule**.

Lymphatic vessels from the left side of the thorax and head, left arm, and everything below the diaphragm on both sides of the body empty into the largest lymphatic vessel, the **thoracic duct**. The thoracic duct empties into the left subclavian vein. Lymphatic vessels from the right arm, the right sides of the thorax, head and neck empty into the **right lymphatic duct**. The right lymphatic duct empties into the right subclavian vein.

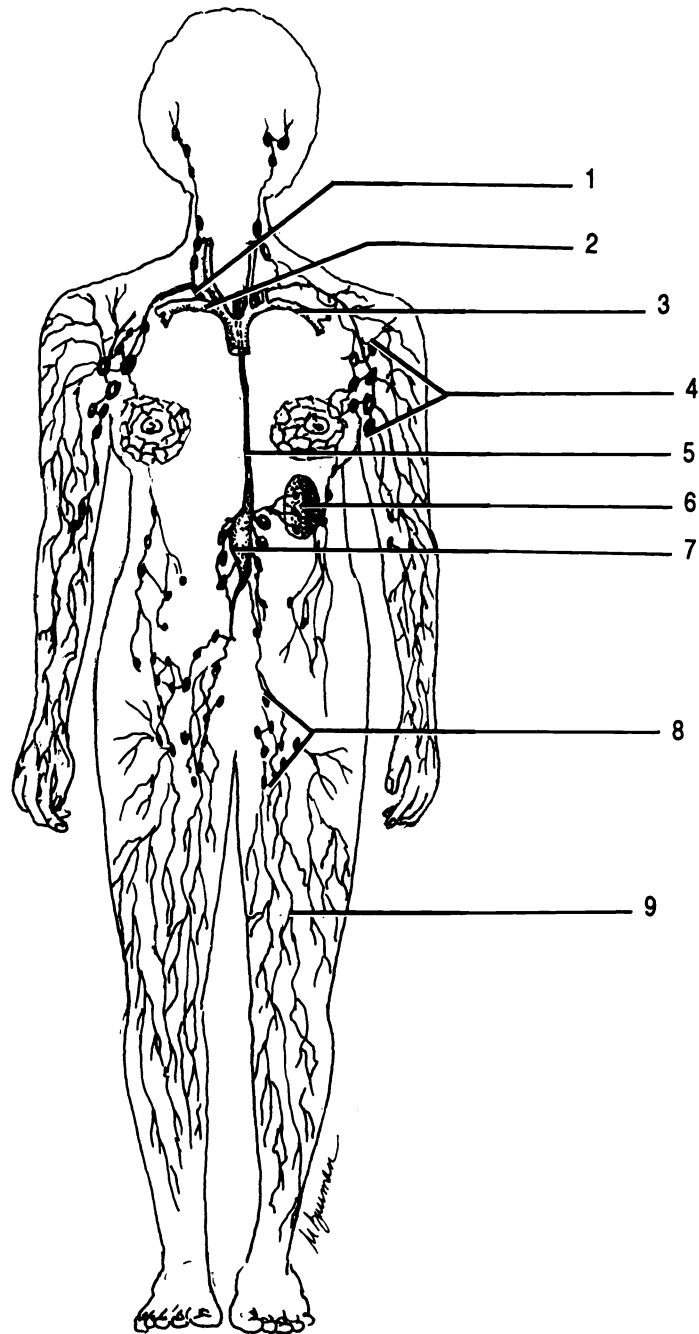


Figure 30.1 Lymphatic System

Axillary lymph nodes Cisterna chyli Inguinal lymph nodes Left subclavian vein Lymphatic vessels
 Right lymphatic duct Right subclavian vein Spleen Thoracic duct

The inferior end of the thoracic duct is enlarged into the **cisterna chyli** (*cistern* = L. reservoir). **Chyle** is lymph containing a large amount of lipid absorbed in the **lacteals**. Lacteals are the lymphatic vessels of the intestinal villi (see chapter 20).

The largest mass of lymphatic tissue in the body is the **spleen**. The spleen has no afferent lymphatic vessels. It serves to remove dead red blood cells, produce B lymphocytes, and stores and releases blood.

Exercise 30.1

Correctly label the structures of the lymphatic system as shown in Figures 30.1 and 30.2.

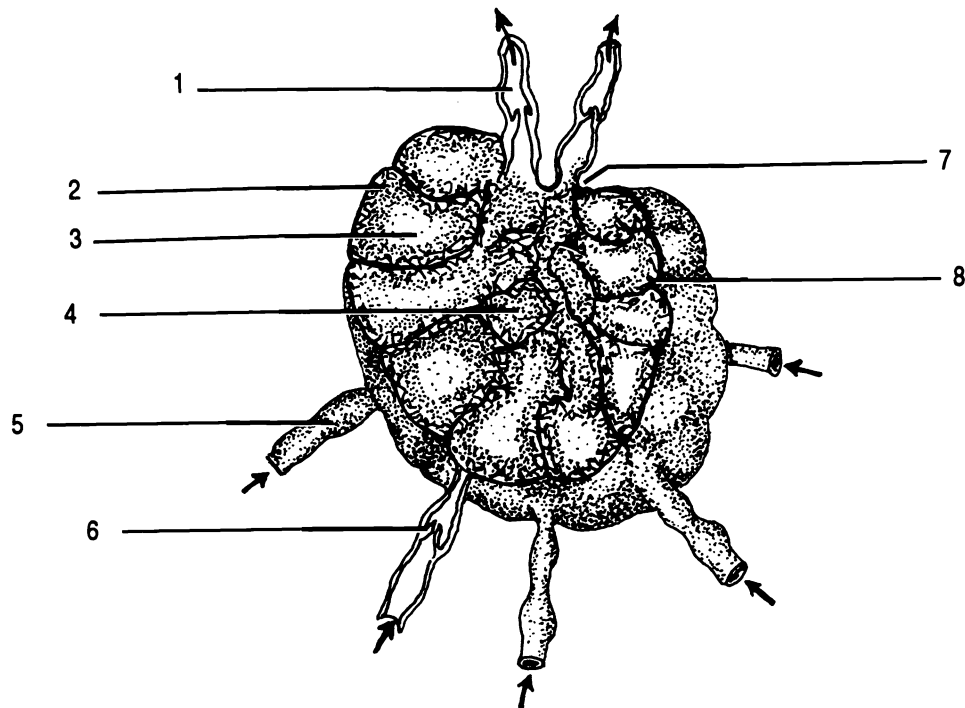


Figure 30.2 Lymph Node

Afferent lymphatic vessel Capsule Cortex Efferent lymphatic vessel Germinal center Hilus Medulla Valve

CHAPTER 30 REVIEW

1. _____ Afferent vessels carry lymph (to/from) lymph nodes.
2. _____ The largest lymphatic vessel is the (2).
3. _____ True/False. The lymphatic system is symmetrical. That is, it is the same on each side of the body.
4. _____ Give three functions of the lymphatic system.
5. _____
6. _____
7. _____ Germinal centers produce new (7).
8. _____ What prevents lymph from flowing back down the thoracic duct?
9. _____ What is the lymphatic vessel inside a villus?
10. _____ How is a lymphatic capillary different from a circulatory capillary (other than the substance within them)?
11. _____ The depression through which an efferent vessel exits the lymph node is a (11).
12. _____ The greatest mass of lymphatic tissue is the (12).
13. _____ Most lymph nodes are located in the (13, 14, 15) and (16) regions.
14. _____
15. _____
16. _____
17. _____ The inner, maze-like portion of a lymph node is the (17).
18. _____ That portion of the lymphatic system which stores chyle is the (18).

CHAPTER 31
RESPIRATORY
ORGANS

The organs of the respiratory system include the nasal cavity, pharynx, larynx, trachea, bronchi, bronchioles, and lungs.

Exercise 31.1

Label Figure 31.1 and 31.2 as you read.

Air enters the respiratory system through the nostrils or **nares**. The nasal cavity is divided into three areas by bony plates called **conchae**. The inferior conchae are separate bones, the middle and superior conchae are ridges of the ethmoid bone.

The nasal cavity opens posteriorly into that portion of the pharynx known as the **nasopharynx**. It is here that the eustachian tube from the ear has its termination. The nasopharynx leads to the **oropharynx** and the **laryngopharynx**. The latter opens into the larynx.

The **larynx** (Figure 31.2) is also known as the voice box. It consists of three single and three paired pieces of cartilage. The **thyroid cartilage** is the largest and most anterior cartilage. It is usually larger in males than in females and in the vernacular is known as the Adam's apple.

The **epiglottis** is a leaf-shaped piece of cartilage located behind the thyroid cartilage. The "stem" of the epiglottis is attached to the thyroid cartilage, but the "blade" portion is free to move. During swallowing, the blade-like portion folds down over the **glottis**, which consists of the vocal folds and the space between them. In this way food and liquids are kept out of the trachea.

The last of the single cartilages is the **cricoid cartilage**. The cricoid cartilage is located inferior to the thyroid

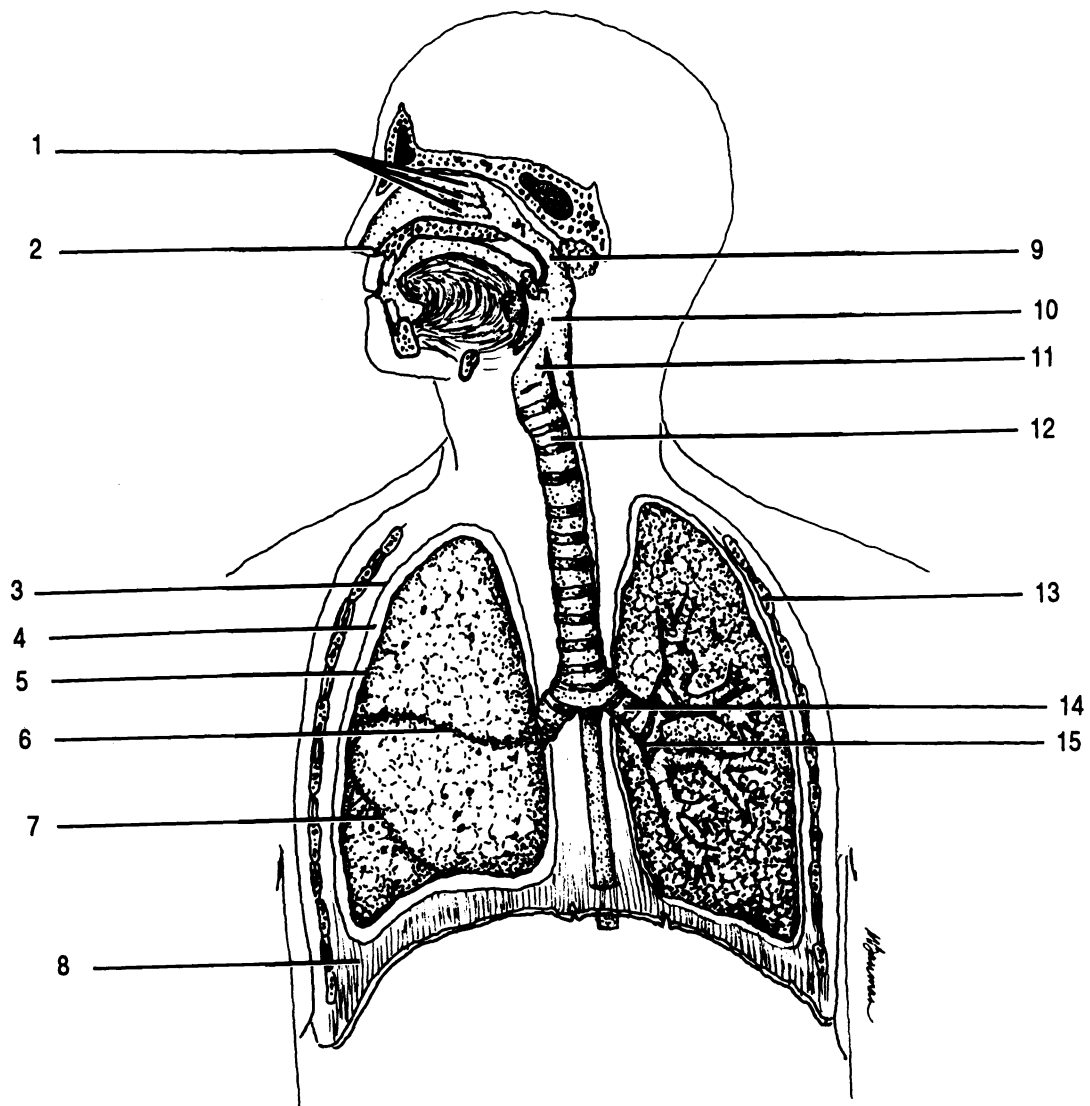


Figure 31.1 Respiratory System

Conchae Diaphragm Horizontal fissure Larynx Naris Nasopharynx Oblique fissure Oropharynx
 Parietal pleura Pleural cavity Primary bronchus Rib Secondary bronchus Trachea Visceral pleura

cartilage. It is attached to the first segment of the trachea.

The paired cartilages of the larynx are much smaller than the single cartilages. The **arytenoid cartilages** are located superior to the posterior portion of the cricoid cartilage. The arytenoid cartilages are attached to the vocal folds and pharyngeal muscles. Action of the muscles controls the tension in the vocal folds and thereby the pitch of sounds produced by vibration of the folds.

On top of each arytenoid cartilage is a horn-shaped **corniculate cartilage**. The paired **cuneiform cartilages** are anterior to the corniculate cartilages. These four cartilages are not of great concern to our study of the respiratory system.

The larynx opens into the **trachea**, anterior to the esophagus. The trachea is composed of a series of incomplete cartilaginous rings. The rings are "C"-shaped and are open in the rear. The esophagus expands into the open part of the ring during swallowing. The last ring of the trachea has an internal projection of cartilage called the **carina** which is particularly sensitive and plays an important role in the cough reflex.

Inferiorly the trachea divides into two **primary bronchi** (**sing. - bronchus**). The right primary bronchus is shorter and straighter than the left. Each primary bronchus divides into one secondary bronchus for each lobe of the lungs. The secondary bronchi divide into ever smaller branches connected to the microscopic air sacs where the exchange of gases takes place.

The **lungs** are separated from each other by the organs of the mediastinum (Figure 1.6). Each lung is surrounded by a serous membrane, the **pleura**, which is folded to give the appearance of having two distinct layers (see Figure 1.8). The layer closest to a lung is termed the **visceral pleura**. The outer layer is the **parietal pleura**. There is a potential space between the layers termed the **pleural cavity**. The larger, right lung has three lobes, while the smaller, left lung only has two lobes. The lobes of the right lung are divided by **oblique** and **horizontal fissures**. The horizontal fissure is superior to the angled oblique fissure. The left lung has only an oblique fissure.

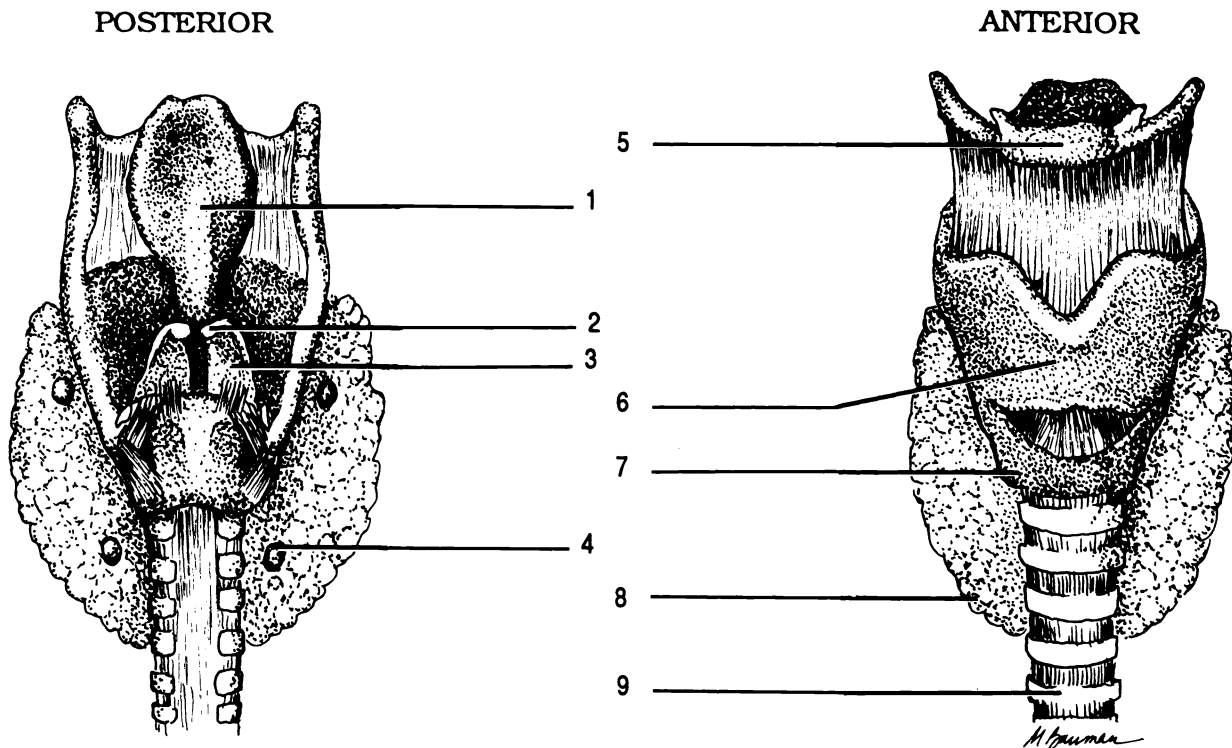


Figure 31.2 Larynx

Arytenoid cartilage Corniculate cartilage Cricoid cartilage Epiglottis Hyoid Parathyroid gland Thyroid cartilage
 Thyroid gland Trachea

Each lobe is composed of small functional units called **lobules**. Inside each lobule are numerous air sacs termed **alveoli** (*sing. - alveolus*). The walls of the alveoli are only one squamous cell thick. Gases can freely exchange between the alveoli and the blood vessels beneath.

The primary muscle of breathing is the **diaphragm** which is assisted by the action of the external and internal intercostals (Figure 16.1) and other muscles.

Exercise 31.2

Examine the models of the respiratory system. Identify:

Thorax: Bronchioles, cricoid cartilage, diaphragm, epiglottis, esophagus, heart, hyoid bone, larynx, lungs, thyroid cartilage, thyroid gland, and trachea.

Larynx: arytenoid cartilages, corniculate cartilage, cricoid cartilage, epiglottis, hyoid bone, glottis, thyroid cartilage, trachea, and vocal folds.

Midsagittal section of head: cricoid cartilage, epiglottis, esophagus, hard palate, inferior nasal concha, laryngopharynx, larynx, medial nasal concha, nares, nasopharynx, oral cavity proper, oropharynx, soft palate, superior nasal concha, thyroid cartilage, tongue, uvula, and vocal folds.

Exercise 31.3

Examine the larynx of the cat. Identify the cricoid cartilage, thyroid cartilage, and thyroid gland.

Cut into the larynx to see the epiglottis and glottis.

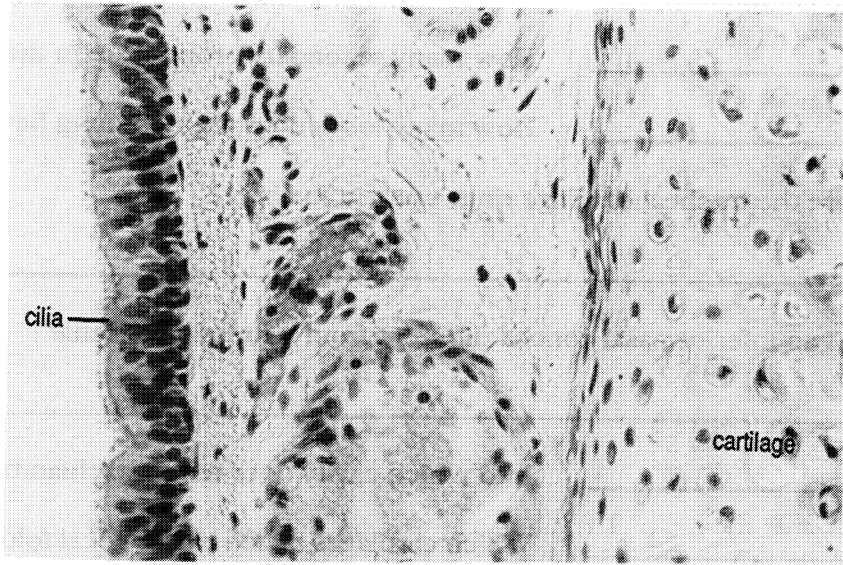
Trace the trachea down into the lungs. Note that there are different number of lobes in the cat lungs than in the human.

Cut across the trachea to examine the shape of the cartilaginous rings.

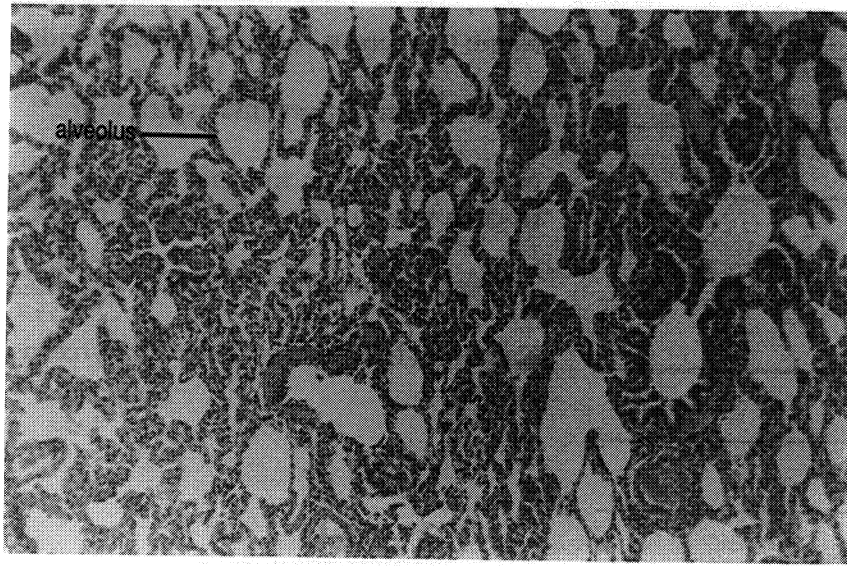
Exercise 31.4

Examine a microscopic slide of a lung. Note the alveoli and their thin walls. Identify the visceral pleural membrane.

Examine a prepared slide of the trachea. Notice the epithelial lining of the airway and the hyaline cartilage in the ring.



Trachea



Lung

CHAPTER 31 REVIEW

1. _____ How many secondary bronchi are in the right lung?
2. _____ How many secondary bronchi are in the left lung?
3. _____ How many lobes does the right lung have?
4. Why are the tracheal cartilage rings open in the back?

5. How is an inferior nasal concha different from a superior concha?

6. _____ Into which cavity does the Eustachian tube open?
7. _____ Which cartilages attach to the vocal folds?
8. _____ What is the primary muscle for breathing?
9. _____ Name the serous membrane surrounding a lung.
10. _____ What structure prevents aspiration?
11. _____ Name the inferior, internal ridge of cartilage in the trachea which acts in the cough reflex.
12. _____ The functional unit of a lung is the (12).
13. _____ Name the three parts of the pharynx in alphabetical order.
14. _____
15. _____

SPIROMETRY

The measurement of lung capacity is known as **spirometry**. Figure 32.1 shows a **Propper spirometer** used to make such measurement. There are a number of terms used in describing various volumes of air during breathing:

Tidal volume - the normal amount of air that moves in and out of the lungs during a normal breath. Average = 500 ml

Expiratory reserve volume - the amount of air which can be expelled beyond the tidal volume (i.e. beyond normal expiration). Average = 1,200 ml

Inspiratory reserve volume - the amount of air that can be drawn into the lungs *after* a normal inhalation. Average = 3,100 ml

Vital capacity - the sum of the tidal, expiratory reserve, and inspiratory volumes. This is the total functional capacity of the lungs. Average = 4,800 ml

Residual volume - the amount of air which cannot be expelled from a living lung. Average = 1,200 ml

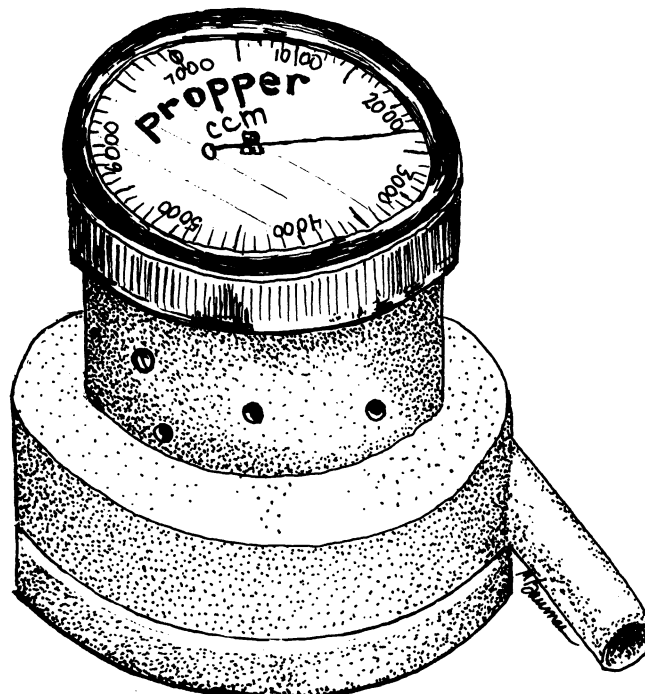


Figure 32.1 Propper Spirometer

Exercise 32.1

Measure your tidal volume, expiratory reserve volume, and vital capacity using a Propper spirometer.

1. Swab the stem of the spirometer with alcohol and place a mouthpiece over the stem.

2. Rotate the dial of the spirometer to zero.

When you exhale through the spirometer, the dial will remain at the position it attains. Exhale slowly and steadily. Hold the spirometer with the dial up.

3. After three normal breaths, exhale three normal breaths into the spirometer. Inhale through your nose. The dial of the spirometer will automatically add the volumes of the three breaths.

4. Divide the spirometer reading by three and record the result as your tidal volume.

5. Set the spirometer to zero.

6. Without the spirometer, make three normal inhalations and exhalations. Then, without a fourth inhalation, exhale all you can through the spirometer.

7. Record this volume as your expiratory reserve volume.

8. Set the spirometer to zero once again.

9. Without the spirometer, take three deep breaths and exhale completely. Take a fourth deep breath and exhale completely, slowly, and steadily through the spirometer.

10. Record this volume as your vital capacity.

Since the Propper spirometer works only during expiration, you cannot measure the inspiratory reserve volume directly. However, you can calculate the inspiratory reserve volume by subtracting the tidal and expiratory reserve volumes from the vital capacity.

11. Calculate and record your inspiratory reserve volume.

12. Discard the mouthpiece. Wipe the stem with alcohol.

13. If you are the last person to use the spirometer during a period, open the spirometer and wipe the interior with alcohol.

	Average	Your Capacities
Tidal Volume	500 ml	_____
Expiratory reserve volume	1,200 ml	_____
Vital capacity	4,800 ml	_____
Inspiratory reserve volume ($IRV = VC - ERV - TV$)	3,100 ml	_____

CHAPTER 32 REVIEW

1. _____ What is normal tidal volume?
2. _____ True/false. The vital capacity is the volume of air contained in the lungs at death.
3. _____ True/false. The residual volume is the volume of air which is expelled during forced expiration.
4. _____ The measurement of lung capacities is (4).
5. _____ True/false. The Propper spirometer is effective for directly measuring normal exhalations.

THE URINARY SYSTEM

The urinary system functions to cleanse the blood of wastes and to insure a proper balance of electrolytes and water in the blood plasma.

The primary organs of the urinary system are the two **kidneys**. They are bean-shaped and located retroperitoneally, i.e., behind the peritoneum (see chapter 20). Each kidney receives blood through a **renal artery**. Blood leaves the kidney through the **renal vein**. The blood vessels enter and leave the kidney through a depression termed the **hilus**.

The outer fibrous covering of the kidney is the **capsule**. Deep to the capsule is the **cortex**. Deeper yet is the **medulla**. The medulla is divided into cone-shaped **renal pyramids** which are separated by extensions of the cortex called **renal columns**.

Each renal pyramid terminates in a **renal papilla** which projects into a cavity called a **calyx** (pl. - **calyces**). The calyces are cavities which take the urine from the papillae and empty it into the large, funnel-like **renal pelvis**.

The functional unit of the kidney is the **nephron**. Nephrons are located primarily in the cortex, though portions of the nephrons can extend into the medulla. It is estimated that there are approximately one million nephrons per kidney! Each nephron is composed of four major parts, the renal corpuscle, two convoluted tubules, and Henle's loop.

The **renal corpuscle** is a spherical structure composed of an inner ball of blood capillaries, the **glomerulus**, and an outer, double-walled, cap-like structure, **Bowman's capsule**. The arteriole entering a glomerulus is an **afferent arteriole**, while an **efferent arteriole** carries blood from a glomerulus.

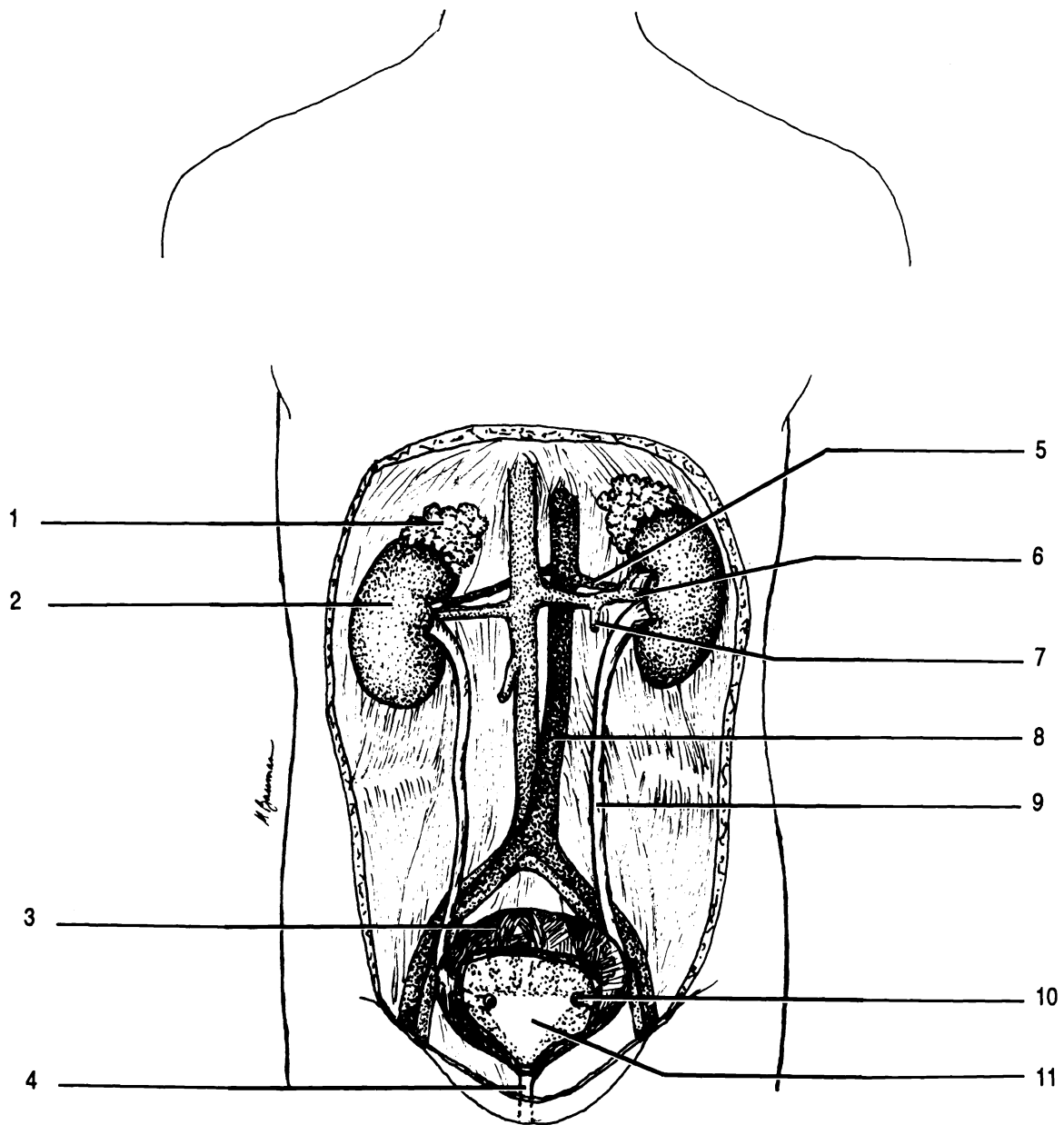


Figure 33.1 Urinary System

Adrenal gland Descending aorta Left spermatic vein Opening of ureter Renal artery Renal vein Right kidney
 Trigone Ureter Urethra Urinary bladder

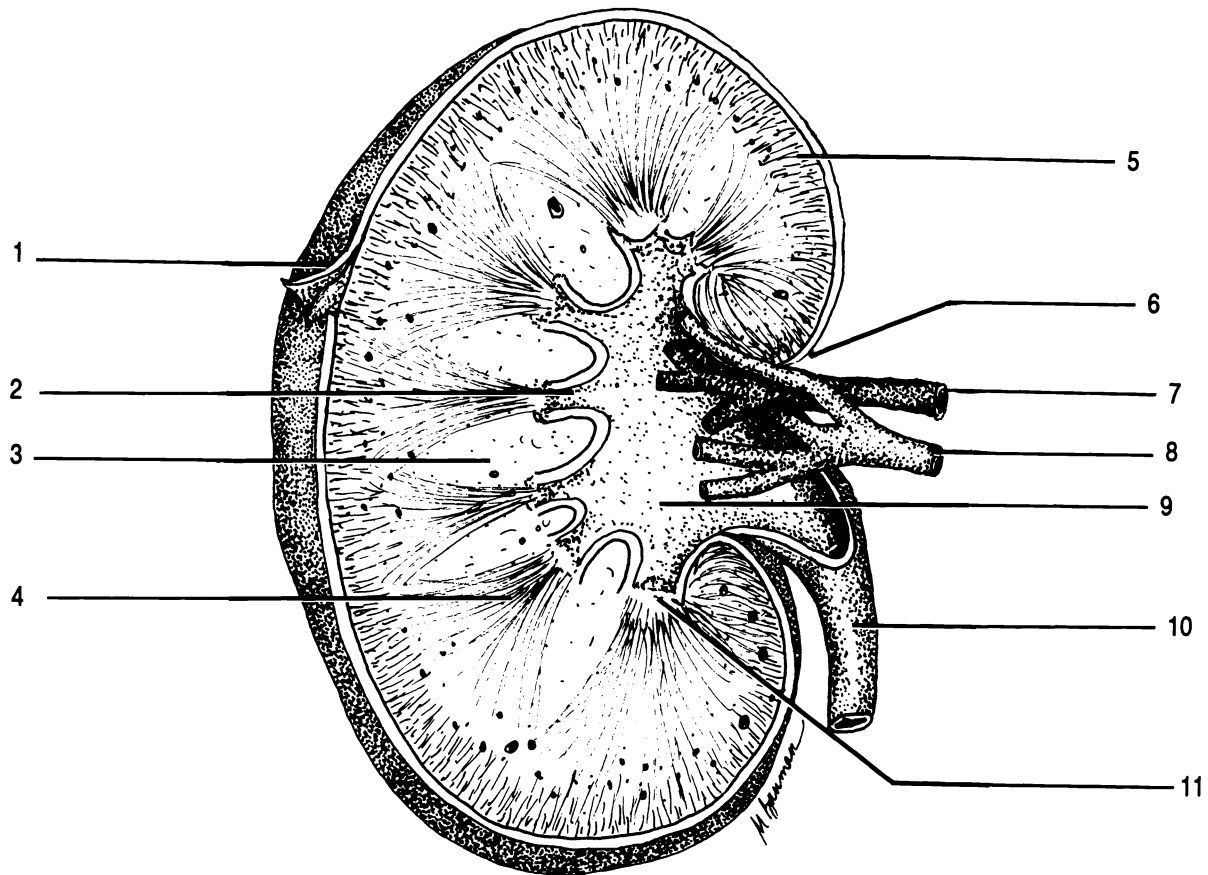


Figure 33.2 Kidney

Calyx Capsule Column Cortex Hilus Papilla Pelvis Pyramid Renal artery Renal vein Ureter

Fluid collected in Bowman's capsule passes sequentially through the **proximal convoluted tubule**, the **descending limb of Henle's loop**, the **ascending limb of Henle's loop**, and into the **distal convoluted tubule**. The convoluted tubules and loop of Henle are surrounded by many peritubular capillaries. The distal convoluted tubule curls back to touch the afferent arteriole. Specialized cells of the tubule and of the arteriole at the point of contact make up the **juxtaglomerular apparatus**.

Urine leaving the nephron empties into a **collecting tubule**. Several nephrons may empty into one collecting tubule.

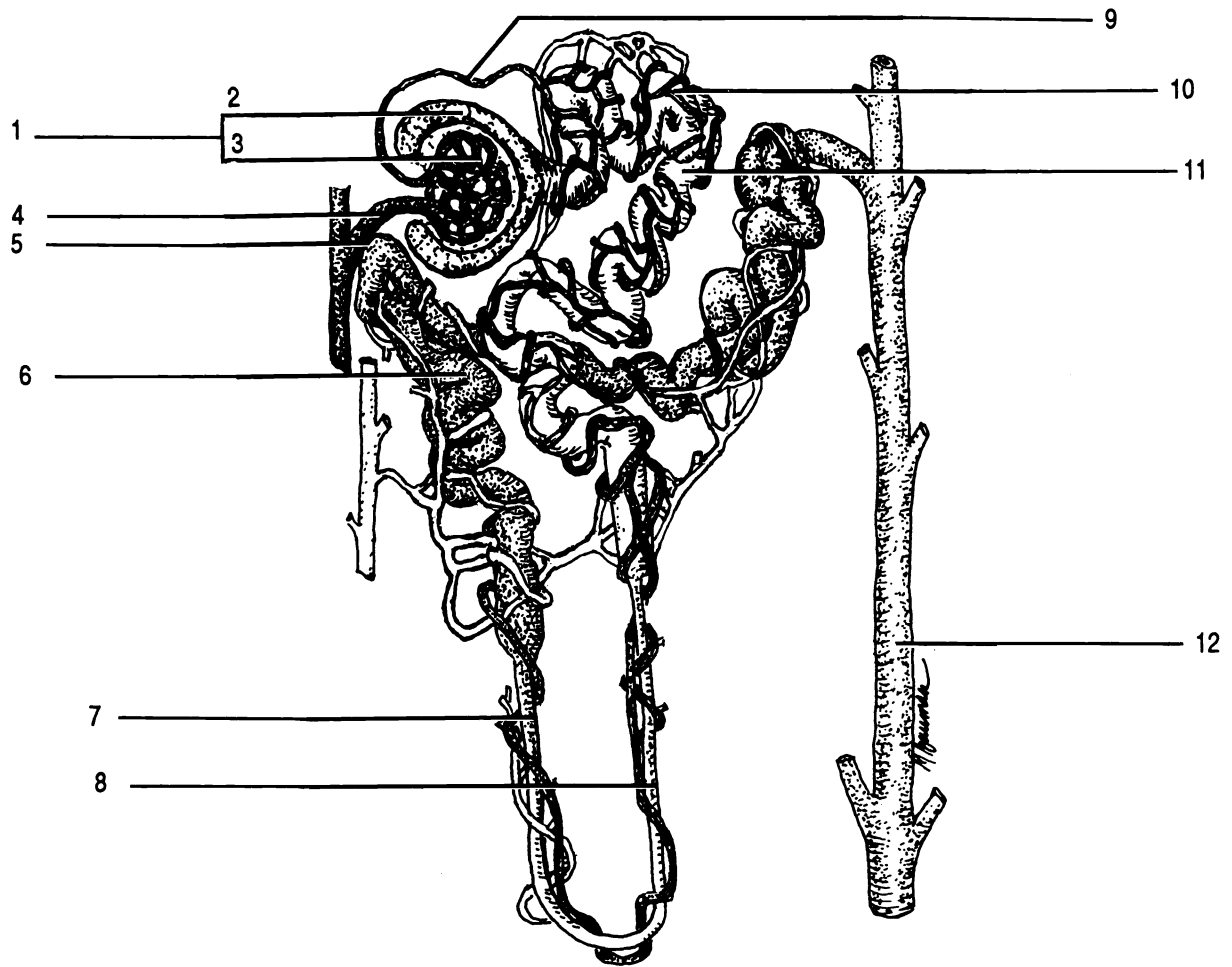


Figure 33.3 Nephron

Afferent arteriole Ascending limb of loop of Henle Bowman's capsule Collecting tubule
 Descending limb of loop of Henle Distal convoluted tubule Efferent arteriole Glomerulus Juxtaglomerular apparatus
 Peritubular capillaries Proximal convoluted tubule Renal corpuscle

Urine flows down the collecting ducts in the renal pyramids to the papillae, calyces, and into the renal pelvis. The renal pelvis drains into the **ureter** which exits at the hilus. The ureters, one from each kidney, empty into the **urinary bladder**. The urinary bladder empties through the single **urethra**. Control of urine flow from the bladder is provided by two sphincter muscles at the superior end of the urethra.

The extendable and elastic wall of the bladder is made of four layers. The internal layer is the mucosa, composed of transitional epithelium (see chapter 5) which is able to stretch. Rugae (folds) are also typically present in the relaxed urinary bladder. Deep to the mucosa are the submucosa, muscularis, and the peritoneum. The peritoneum is found only in the superior part of the urinary bladder.

The triangular area formed by the openings of the ureters and urethra in the bladder is the **trigone**. This area is usually smoother because the mucosa is firmly bound to the muscularis at this point.

Exercise 33.1

Label Figures 33.1, 33.2, and 33.3.

Exercise 33.2

Identify the following on the models of the kidney and its parts:

Whole kidney: afferent arteriole, calyx, collecting tubule, cortex, efferent arteriole, hilus, loop of Henle, medulla, nephron, renal artery, renal column, renal corpuscle, renal vein, renal papilla, renal pelvis, and ureter.

Nephron: afferent arteriole, ascending limb of Henle, collecting tubule, descending limb of Henle, distal convoluted tubule, efferent arteriole, loop of Henle, peritubular capillaries, proximal convoluted tubule, and renal corpuscle.

Renal corpuscle: afferent arteriole, Bowman's capsule, distal convoluted tubule, efferent arteriole, glomerulus, juxtaglomerular apparatus, and proximal convoluted tubule.

Exercise 33.3

Examine the sheep kidney. Identify: calyces, cortex, hilus, medulla, renal columns, renal pelvis, renal pyramids, and ureter.

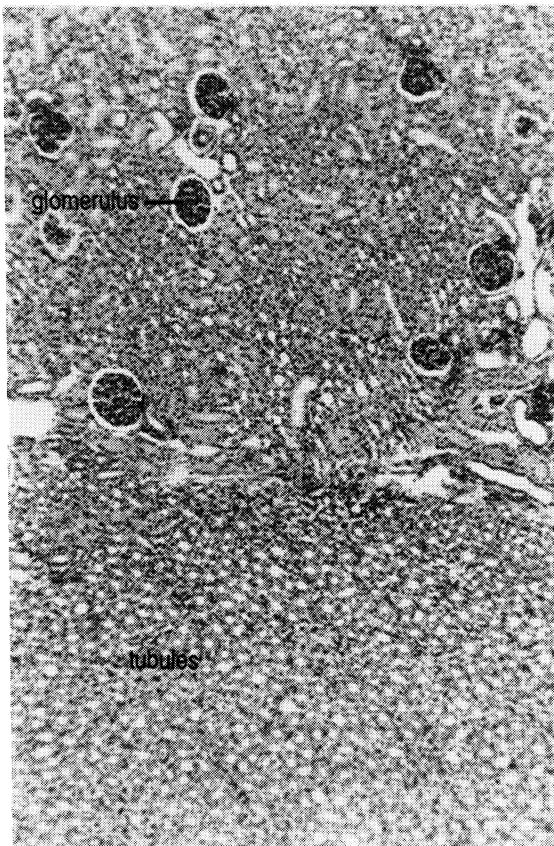
Exercise 33.4

The close association of the reproductive and urinary systems means that these two systems are best studied at the same time in the cat. We will look at the urinary system during our examination of the reproductive system in chapter 36.

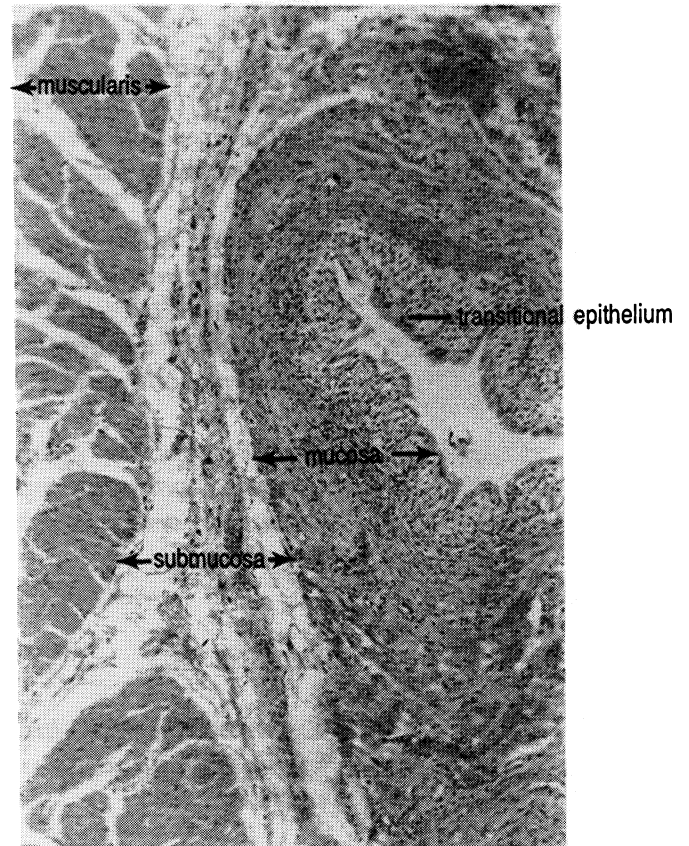
Exercise 33.5

Examine a section of the kidney with a microscope. Note the large number of tubules with walls of simple cuboidal epithelium. Be able to identify a glomerulus and Bowman's capsule.

Examine a section through the urinary bladder. Identify the mucosa, muscularis, submucosa, and transitional epithelium.



Kidney



Bladder

CHAPTER 33 REVIEW

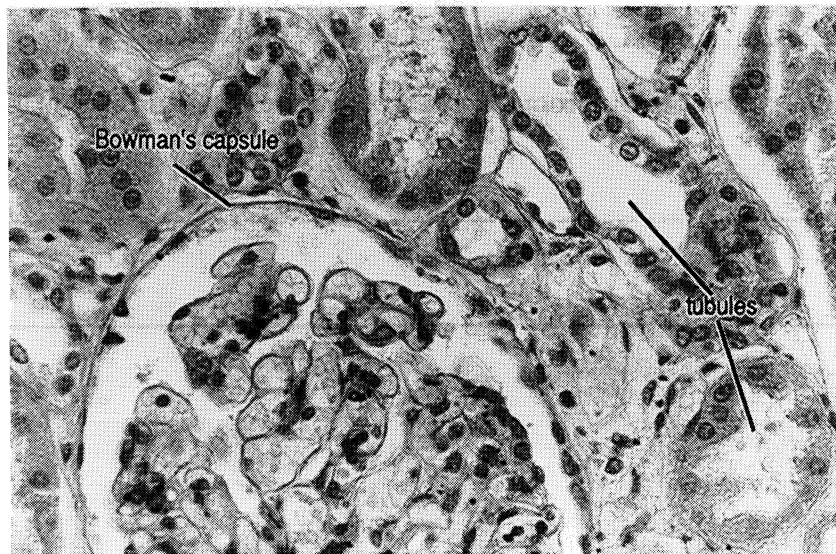1. _____ What two structures make up the renal corpuscle?
2. _____
3. _____ True/false. The renal columns are extensions of the cortex into the medulla.
4. _____ Each renal pyramid empties urine into a (4).
5. _____ The juxtaglomerular apparatus is composed of cells of the (5) and the (6).
6. _____
7. _____ True/false. A collecting tubule can collect urine from more than one nephron.
8. _____ The functional unit of the kidney is the (8).
9. _____ The central solid part of the kidney is the (9).
10. _____ True/false. The afferent arteriole is a blood vessel which carries blood to the kidney.
11. _____ How many layers are in the wall of the urinary bladder?
12. _____ The inner wall of the bladder is (12) epithelial tissue.
13. _____ The (13) is a triangular region on the inner wall of the urinary bladder.
14. _____ The (14) carries urine from the body.
15. _____ Blood is returned to circulation by the (15) vein.
16. Describe the flow of fluid from the renal corpuscle to the urinary bladder.

17. Why is the mucosa of the bladder composed of transitional epithelial tissue?

18. How is urine elimination controlled?

19. What is the purpose of the muscularis in the urinary bladder?

20. What is the function of rugae in the urinary bladder?



Glomerulus

CHAPTER 34
URINALYSIS

Urine is a complex mixture of organic and inorganic solutes in water. Since urine is derived from blood which has travelled throughout the body, urinalysis can point to problems in many other systems besides the urinary system. Physical and chemical characteristics of urine are used to point to abnormalities.

Many of the tests to be performed will utilize test strips. These test strips have been impregnated with chemicals which react with chemicals in the urine. By comparing the color of the strip with standard colors, the amount of various chemicals in the urine can be determined. The tests do not have to be performed in order.

Exercise 34.1

Collect a urine specimen in a clean jar just before class starts. You should fill the jar approximately two thirds full.

Examine the physical appearance of the urine and record your observations. Compare your results with the values shown.

Color. Normal urine is amber to straw colored due to a pigment called urochrome which is a breakdown product of hemoglobin in the blood:

hemoglobin → hematin → bilirubin →
urochromogen → urochrome.

The following colors are indications of unusual chemicals in the urine:

Milky white - pus, bacteria, chyle

Reddish yellow urobiligen from bacteria acting on bile or
 porphyrin from cirrhosis of the liver or
 jaundice

Brownish yellow or green - bile pigments

Reddish brown - blood

Certain foods such as carrots, beets, rhubarb and some drugs and vitamin supplements can color the urine without indicating pathology.

Transparency. *Swirl your specimen and observe its transparency. Normal urine is clear (not cloudy).* Cloudy urine may indicate minerals, pus, bacteria, chyle, or mucus. You will examine the urine microscopically later for these solids.

Specific Gravity. Specific gravity is a determination of the density of a substance. For liquids, the specific gravity is dependent upon the amount of solute dissolved in the water. Specific gravity is also dependent upon temperature. Specific gravity of urine is determined using a **urinometer** (see Figure 34.1) which is composed of a **cylinder** and a **hydrometer**. The hydrometer floats in urine in the cylinder. The greater the specific gravity, the higher the hydrometer will float. Calibrations on the stem of the hydrometer allow one to determine the specific gravity of the urine. A 24-hour, normal urine specimen has a specific gravity of 1.010 to 1.030, while single samples may range from 1.001 to 1.060.

Exercise 34.2

Before you use the hydrometer practice reading the sample drawings in Figure 34.1.

Fill the cylinder two thirds full of well mixed urine. Remove any foam with a piece of paper towel. Slowly insert the hydrometer so that it does not hit the bottom. Read the hydrometer.

Take the temperature of the urine. Record the temperature.

Wash the urinometer pieces with soap and water.

Calculate the correct specific gravity by adding 0.001 for each 3° C above 25° C or subtracting the same amount for each 3° below 25° C. Record the adjusted specific gravity.

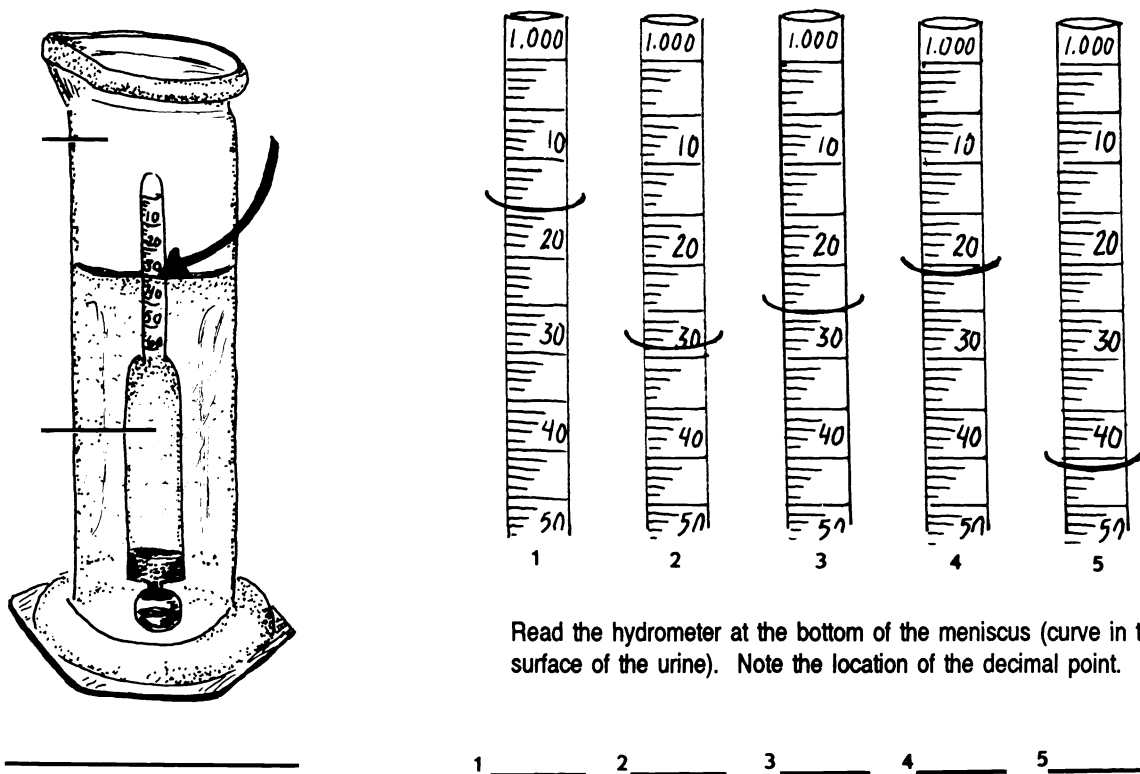


Figure 34.1 Urinometer

Cylinder Hydrometer Urinometer

Hydrogen Ion Concentration. Hydrogen ion concentration is measured by using pH paper. An acid pH is below 7.0, while an alkaline pH is above 7.0. Freshly collected urine has a pH between 4.5 and 8.0. The pH varies during the day and with diet. High acidity can indicate acidosis, fever, and high protein diet. Alkalinity can indicate retention in the bladder, anemia, and gastric ulcers.

Exercise 34.3

Dip a piece of pH (nitrazine) paper into the urine. Shake off the excess urine. Immediately compare the color of the paper with the standards on the container.

Record the pH.

Proteins. Normally large amounts of protein are not found in urine. We will test for one protein, albumin. Certain conditions such as a high protein diet and cold baths, as well as toxemia, anemia, and kidney congestion, can result in albumin in the urine.

Exercise 34.4

Swirl the sample of urine and insert an Albustix test strip and immediately compare the color with the standards on the bottle.

Record your results.

Bilirubin. Bilirubin is formed from the breakdown of hemoglobin from red blood cells. It is normally present in small quantities in the urine. Large amounts may indicate malfunction of the liver.

Exercise 34.5

Use the Ictotest to test for bilirubin.

Place the square, absorbent test mat on a paper towel.

Place ten drops of urine onto the center of the test mat.

Shake one Ictotest tablet into the jar lid. Transfer the tablet onto the center of the moistened mat. DO NOT HANDLE THE TABLET WITH YOUR FINGERS.

IMMEDIATELY CLOSE THE BOTTLE.

Place one drop of water onto the tablet. Wait 5 seconds and place another drop of water on the tablet so that the water runs off the tablet onto the mat.

A blue or purple color indicates the presence of bilirubin in the urine; a pink or red color should be ignored.

Blood. Blood is not normally found in urine, though the urine may be contaminated with blood at the time of collection from menstruating females.

Exercise 34.6

Use a Hemastix test strip to test for the presence of blood.

Dip the test strip into well-mixed urine and remove immediately. While removing, run the edge of the strip against the edge of the container to remove excess urine.

Exactly 60 seconds after removal, compare with the standards on the bottle.

Record your results.

Glucose. The amount of glucose excreted by the kidney is very small, no more than 0.03 g/dl. Excess glucose in the urine often indicates diabetes mellitus.

Exercise 34.7

Swirl the sample of urine and dip in a Clinistix test strip. Tap off excess urine on the rim of the container.

After ten seconds, compare the color with the standards.

Record your results.

Ketones. Ketones are an intermediate product in the breakdown of fatty acids by cells. When there is inadequate carbohydrate in the body, there is increased lipid catabolism. As fat catabolism increases, the level of ketones in the blood increases. This condition is called ketonuria. Some of the excess ketones are eliminated in the urine. Ketonuria is often a symptom of diabetes mellitus.

Exercise 34.8

Swirl the urine and dip in a Ketostix test strip.

Fifteen seconds after wetting the test strip, compare it with the standards on the bottle.

Record your results.

Microscopic Examination. This is the most critical part of urinalysis. Microscopic examination of the urine may reveal excess minerals, leukocytes, or bacteria. An abundance of leukocytes can indicate a urinary tract infection.

Exercise 34.9

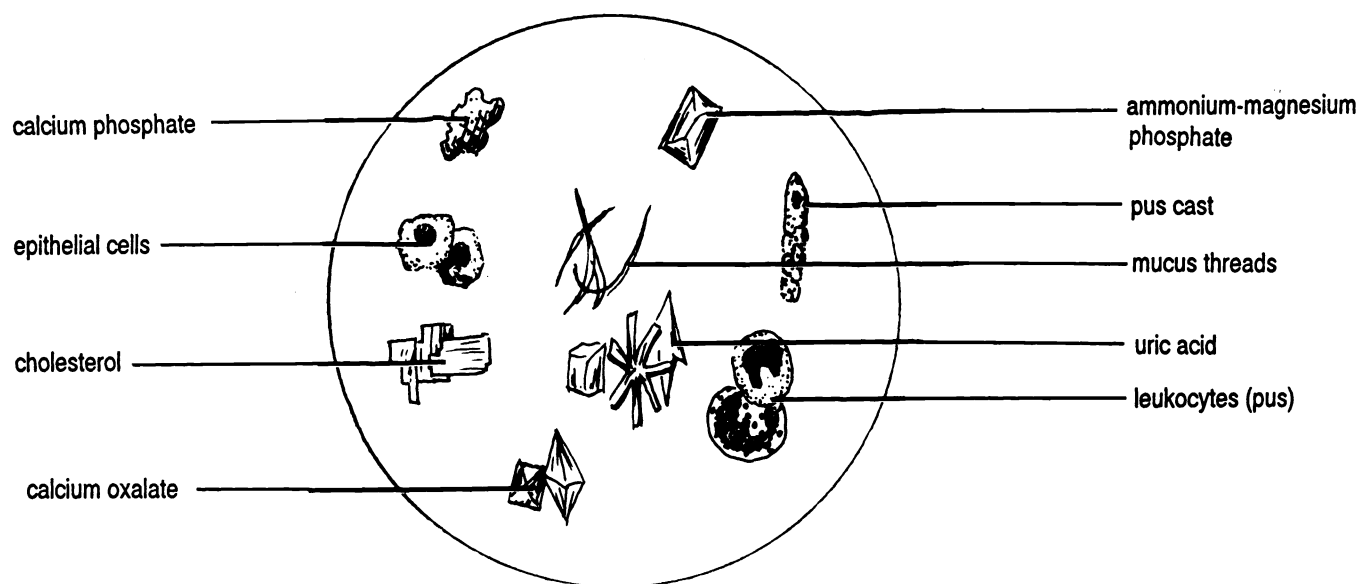
Swirl the urine and pour 5 ml into a centrifuge tube.

Insert the tube into the centrifuge. Balance the tube with another tube containing urine or water on the other side of the rotor.

Centrifuge the tube for five minutes at 1500 rpm.

Carefully pour off the liquid without disrupting the sediment.
Add 2 drops of Sedi-stain (to improve the visibility of cells etc.).
Thoroughly mix the contents by flicking the bottom of the tube with your finger.
With a wire loop, transfer two loops of sediment to a clean glass slide. Add a cover slip.
Examine the specimen under low and high power. Refer to Figure 34.2 to identify objects in the sediment.

Figure 34.2 Urine Sediment



RESULTS OF URINALYSIS

1. **Color** _____
2. **Transparency**
Circle one: Transparent (clear) Translucent (cloudy)
3. **Specific gravity**
Temperature (°C) _____
Adjustment factor _____
Adjusted specific gravity _____
4. **pH** _____
5. **Albumin** Circle one: negative trace + ++ +++ ++++
6. **Bilirubin** Circle one: absent present
7. **Blood** Circle one: negative trace small moderate large
8. **Glucose** Circle one: negative + ++ +++
9. **Ketones** Circle one: negative trace small moderate large
10. **Microscopic examination** Sketch the contents of the urine:

For Instructor-provided "unknown":

1. **Color** _____
2. **Transparency**
Circle one: Transparent (clear) Translucent (cloudy)
3. **Specific gravity**
Temperature (°C) _____
Adjustment factor _____
Adjusted specific gravity _____
4. **pH** _____
5. **Albumin** Circle one: negative trace + ++ +++ ++++
6. **Bilirubin** Circle one: absent present
7. **Blood** Circle one: negative trace small moderate large
8. **Glucose** Circle one: negative + ++ +++
9. **Ketones** Circle one: negative trace small moderate large

CHAPTER 35
MEIOSIS

Meiosis is a special form of nuclear division which occurs only in the ovaries and testes. This form of division results in daughter cells with only half of the normal number of chromosomes; they are **haploid**. These daughter cells are **ova (sing. - ovum)** (eggs) and **sperm**. With the union of sperm and ovum at fertilization, the full number of chromosomes (**diploid**) is reestablished in the new individual. Without meiosis, union of sperm and ovum would produce a new individual with twice as many chromosomes as the previous generation.

Meiosis is divided into eight phases.

Prophase I. Like prophase of mitosis (see chapter 4) the nuclear membrane disappears, and the chromosomes appear. Unlike mitosis, however, chromosomes of the same type pair up together to form twenty three pairs of homologous chromosomes. Since each chromosome has two chromatids (strands), each pair has four chromatids and is called a **tetrad**. During this phase parts of one chromatid may exchange with the identical part from another chromatid. This process is called **crossing over** and results in a unique mixture of genes.

Metaphase I. In metaphase I the chromosome pairs line up in the middle of the cell. This is different from the metaphase of mitosis where the chromosomes do not line up in pairs.

Anaphase I. In anaphase I the chromosomes in each pair are separated. The chromatids of each chromosome remain attached by the centromere. In contrast the chromatids of mitosis separate.

Telophase I. Like telophase in mitosis the nuclear membrane reforms. Cytokinesis (cell division) always follows telophase I of meiosis.

Telophase I may be followed by a brief interphase. Usually the daughter nuclei move directly into prophase II. The stages of prophase II, metaphase II, anaphase II,

and telophase II are basically the same as in mitosis. The chromosomes line up in the middle of the cell, the chromatids are pulled to each pole (and then each is called a chromosome), and then the nuclear membrane reforms. Cytokinesis always occurs during telophase II of meiosis.

The result of meiosis is four daughter nuclei, each different from the parents and from each other because of the crossing over which occurred in prophase I. The four nuclei are contained in four cells produced as a result of the two cytokineses.

In males each of the four cells forms into a sperm. In females the cell divisions are unequal. The first cytokinesis produces one large cell (the **secondary oocyte**) and one small cell termed a **polar body**. The secondary oocyte divides again to form the ovum and another polar body. The original polar body divides to form two polar bodies. The three polar bodies degenerate. In human females the second meiotic division occurs years after the first meiotic division.

Exercise 35.1

Study figure 35.1. Label the stages of meiosis. Crossing over is not shown in order to simplify the illustration. Crossing over is shown in your textbook.

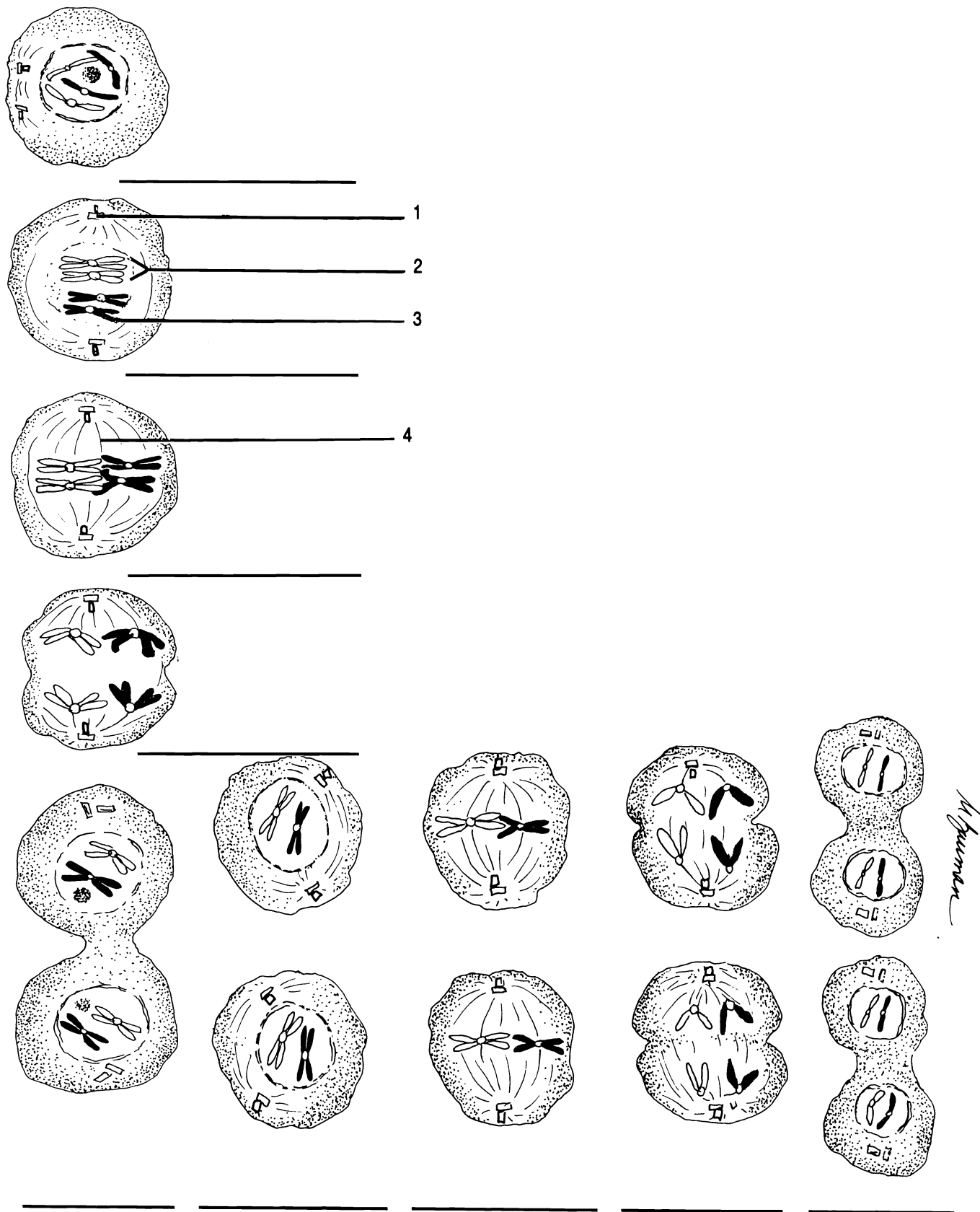


Figure 35.1 Meiosis

Anaphase I Anaphase II Centriole Chromatid Interphase Metaphase I Metaphase II Prophase I Prophase II
 Spindle Telophase I Telophase II Tetrad

CHAPTER 35 REVIEW

1. _____ How many stages are in meiosis?
2. _____ What two events make prophase I of meiosis different from prophase of mitosis?
3. _____
4. _____ In humans the diploid number is 46, what is the haploid number?
5. _____ How many sperm result from one meiosis and cell divisions?
6. _____ (6) chromosomes are chromosomes which are alike.
7. _____ (7) assures that the chromosomes of children are different from each other and from the parents.
8. How is anaphase different in meiosis I and mitosis?

9. _____ Cytokineses in conjunction with meiosis in females results in the production of one ovum and three (9).
10. _____ Does Figure 35.1 best illustrate meiosis in a male or a female?

THE REPRODUCTIVE SYSTEM

MALE

The primary sex organs of the male are the two **testes** (**sing. - testis**), sometimes referred to as testicles. The testes are enclosed in an external pouch, the **scrotum**.

Lying over the superior and posterior surfaces of a testis is an elongated organ, the **epididymis**, where sperm are stored.

During ejaculation (ejection of the sperm) the sperm are propelled from the epididymis through the **vas deferens**. The vas deferens, blood vessels, nerves, lymphatic vessels, and the cremaster muscle make up the spermatic cord.

The vas deferens continues over the symphysis pubis and bladder into the pelvic cavity. The vas deferens joins a duct from the **seminal vesicle** to form the **common ejaculatory duct**. This duct passes through the **prostate gland** and empties into the urethra.

The prostate gland, two seminal vesicles, and two **Cowper's glands** are secondary sex glands of the male. The Cowper's glands secrete into the urethra at the base of the penis.

The penis consists of three cylinders of spongy erectile tissue. The two upper cylinders are the **corpora cavernosa**. The longest of these cylinders is the **corpus spongiosum** (*corpus* = L. body). The corpus spongiosum contains the urethra. The distal end of the corpus spongiosum is enlarged to form the cone-shaped **glans penis**. A flap of skin called the **prepuce** or foreskin covers the glans in uncircumcised males.

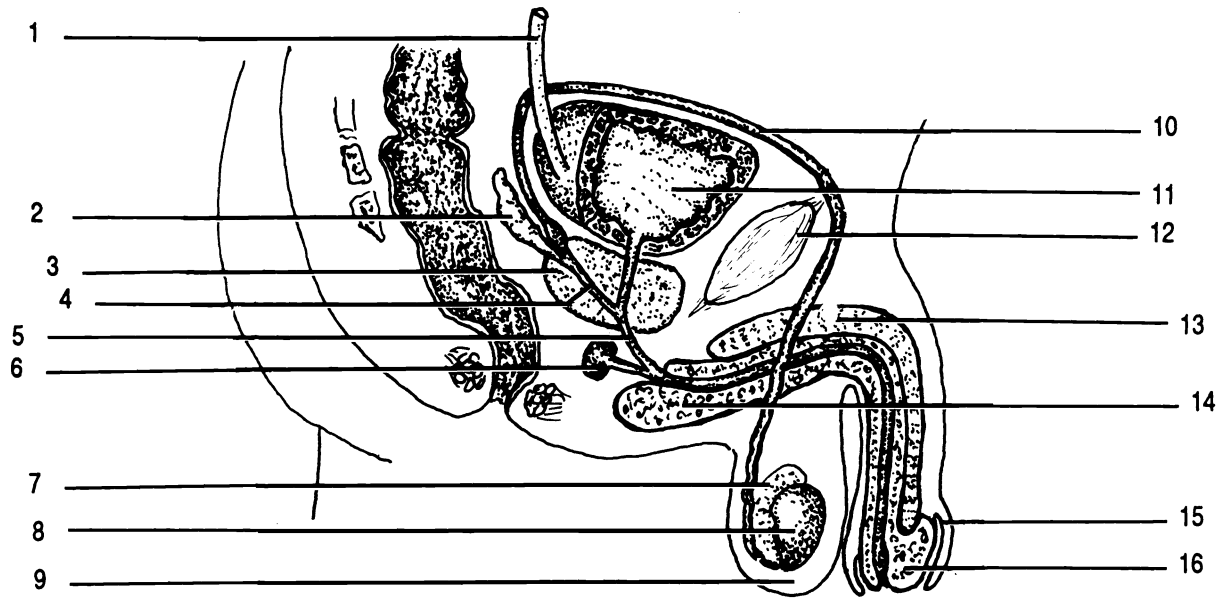


Figure 36.1 Male Reproductive System, Saggital Section

Common ejaculatory duct Corpus cavernosum Corpus spongiosum Cowper's gland Epididymis
 Glans penis Prepuce Prostate gland Scrotum Seminal vesicle Symphysis pubis Testis
 Ureter Urethra Urinary bladder Vas deferens

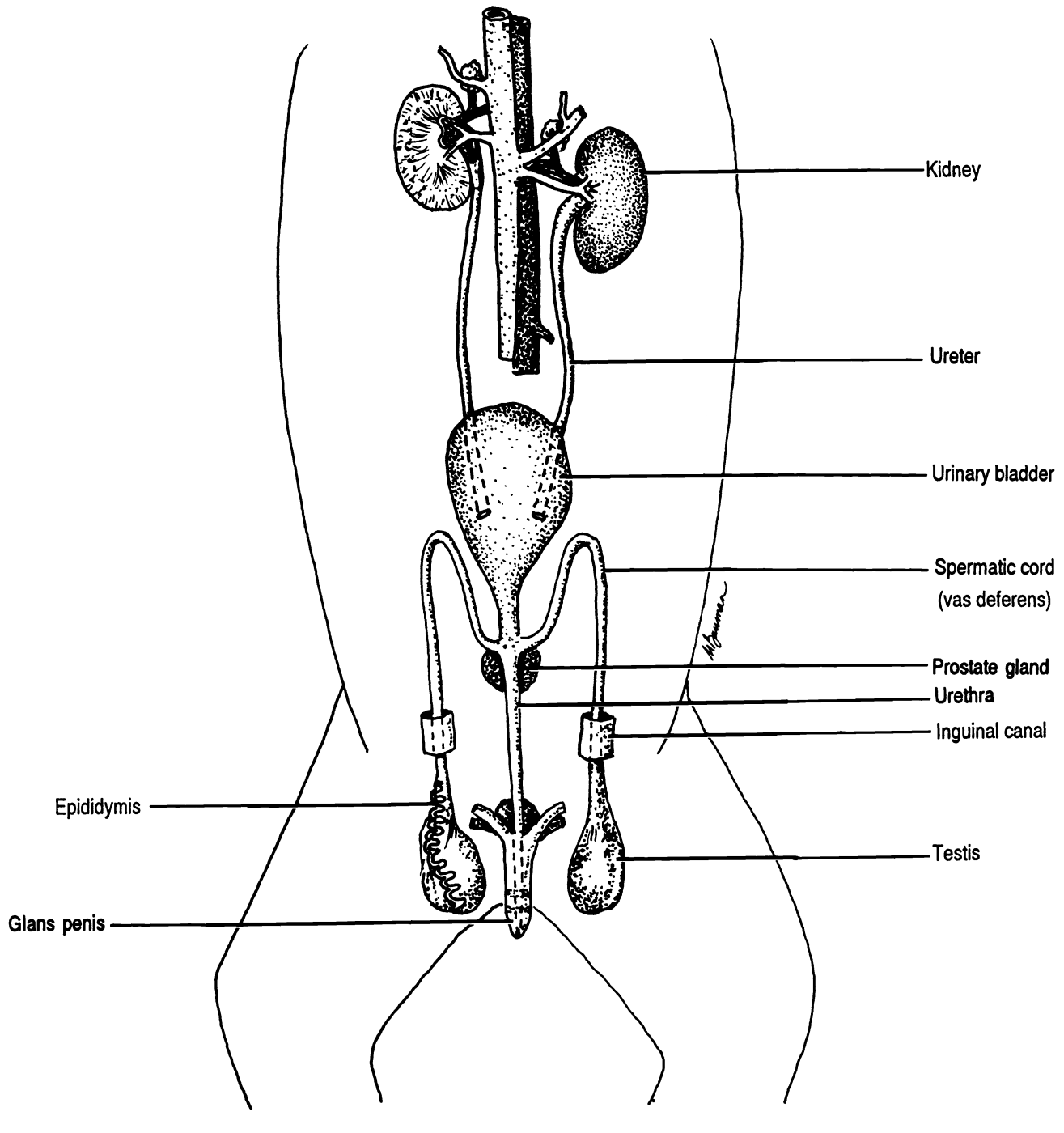
Exercise 36.1

Correctly label Figure 36.1.

Exercise 36.2

Identify the following structures on the model of the male reproductive system: common ejaculatory duct, corpus cavernosum, corpus spongiosum, Cowper's gland, epididymis, glans penis, prepuce, prostate gland, scrotum, seminal vesicle, spermatic cord, symphysis pubis, testis, ureter, urethra and vas deferens.

Figure 36.2 Urinary and Reproductive Systems of the Male Cat



Exercise 36.2

Cat dissection: urinary and reproductive systems. Using Figure 36.2 as a guide locate the following structures of the urinary system in the cat: urinary bladder, kidneys, renal artery, renal vein, ureters, and urethra.

Locate the penis. The sheath around the penis is the prepuce. Pull back the prepuce to expose the glans penis which is covered with papillae.

Carefully cut away the scrotum to expose the testis within a sac of fascia. Locate the epididymis.

Trace the vas deferens of the spermatic cord to the body wall, through the inguinal canal, past the bladder, and into the penis near the prostate gland.

FEMALE

Figure 36.3 illustrates the external reproductive organs of the female. The **mons pubis** is the anterior mound superficial to the symphysis pubis. Two folds of skin, the lateral **labia majora**, and the medial **labia minora**, surround the **vaginal orifice** and the **urethral orifice**. The urethral orifice is anterior to the vaginal. The vaginal orifice may be partially covered by a thin membrane termed the **hymen**. Between the urethral orifice and the mons pubis is the **clitoris**.

Most of the reproductive organs of the female are internal. The largest of these organs is the **uterus**. The uterus is a pear-shaped organ. The anterior, broad portion is the **fundus**, the central portion is the **body**, and the narrow portion is the **cervix**. The cervix opens into a muscular canal, the **vagina**, which opens externally between the labia minora.

Extending laterally from each side of the fundus of the uterus is a **uterine tube** (Fallopian tube) which ends in an enlarged funnel-shaped **infundibulum**. Finger-like projections of the infundibulum are **fimbriae**.

The infundibulum lies over and around the **ovary**. Usually one or two fimbriae touch the ovary. The ovary is the primary sex gland of the female, producing the major sex hormones as well as ova.

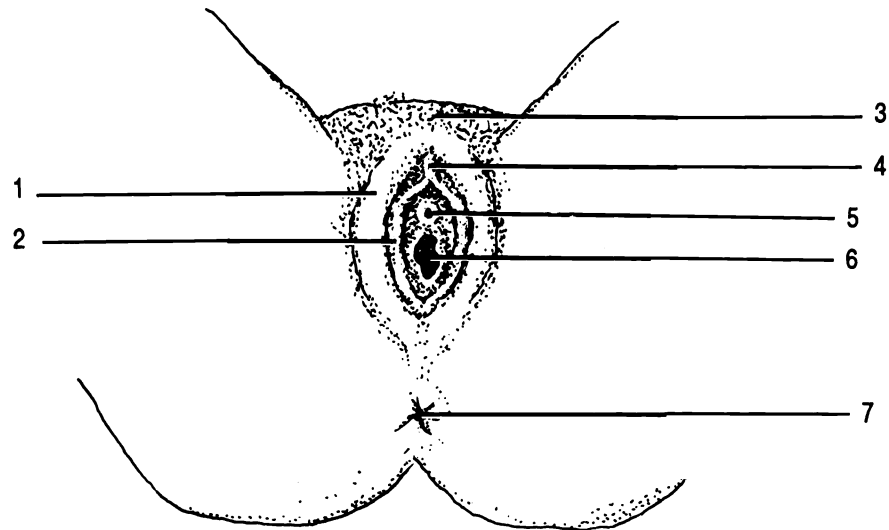


Figure 36.3 Female Reproductive System, external

Anus Clitoris Labia majora Labia minora Mons pubis Urethral orifice Vaginal orifice

The ovaries, uterine tubes, and uterus are held in place by ligaments. Examples of these are the ovarian and broad ligaments. The **ovarian ligament** connects the ovary to the uterus. The **broad ligament** holds the uterus in place.

Exercise 36.4

Correctly label Figures 36.4, 36.5, and 36.6.

Exercise 36.5

Examine the model of the female reproductive structures. Identify the following: body of the uterus, cervix, external os of uterus, fimbriae, fundus of the uterus, infundibulum, ovary, uterine tube, ureter, urethra, urinary bladder, uterus, and vagina.

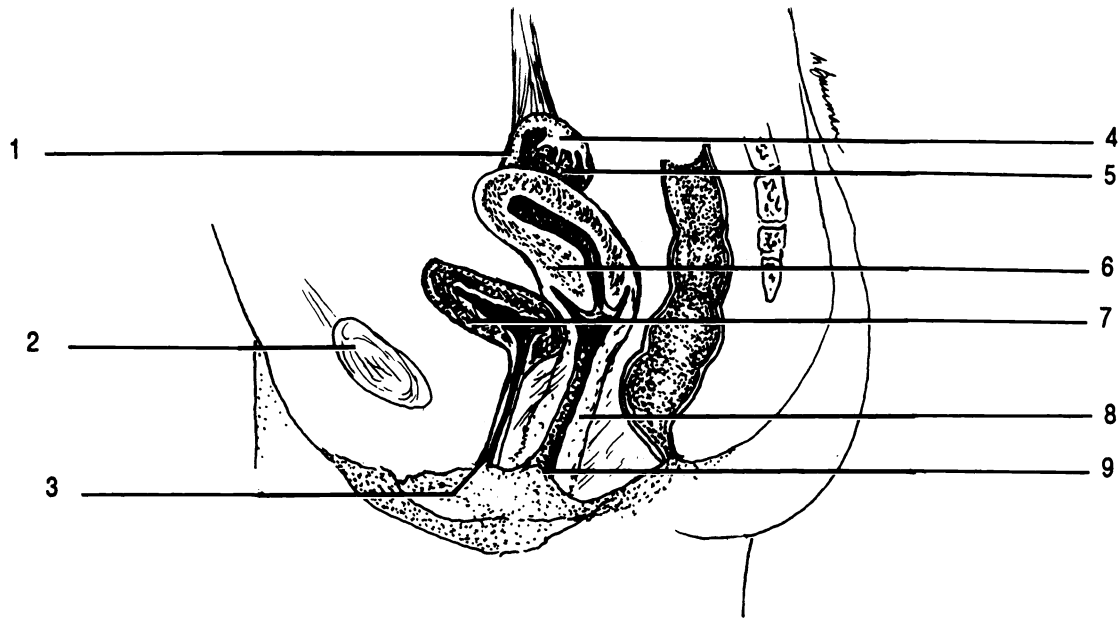


Figure 36.4 Female Reproductive System, midsagittal section

Infundibulum Ovary Symphysis pubis Urethral orifice Urinary bladder Uterine tube Uterus Vagina Vaginal orifice

Exercise 36.6 Cat dissection.

Using Figure 36.6 as a guide locate the following structures of the urinary system in the cat: urinary bladder, kidneys, renal artery, renal vein, ureters, and urethra.

Locate the small, light-colored ovaries posterior to the kidneys.

Locate the uterine tube with its infundibulum and fimbriae.

Note that the uterus in cats is branched. If your cat is pregnant, open the uterus and remove a fetus. Note the placenta and umbilical cord.

Exercise 36.7

Using a microscope, examine a prepared slide of an ovary and identify a Graafian follicle. Examine a section through a testis and identify spermatozoa.

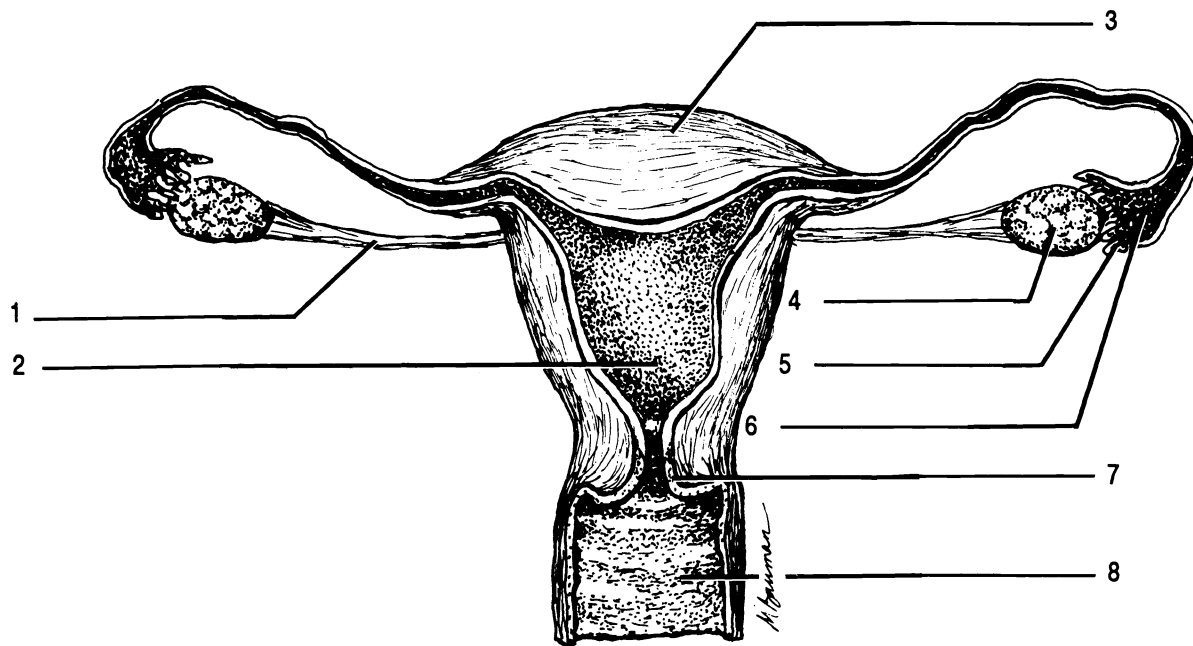
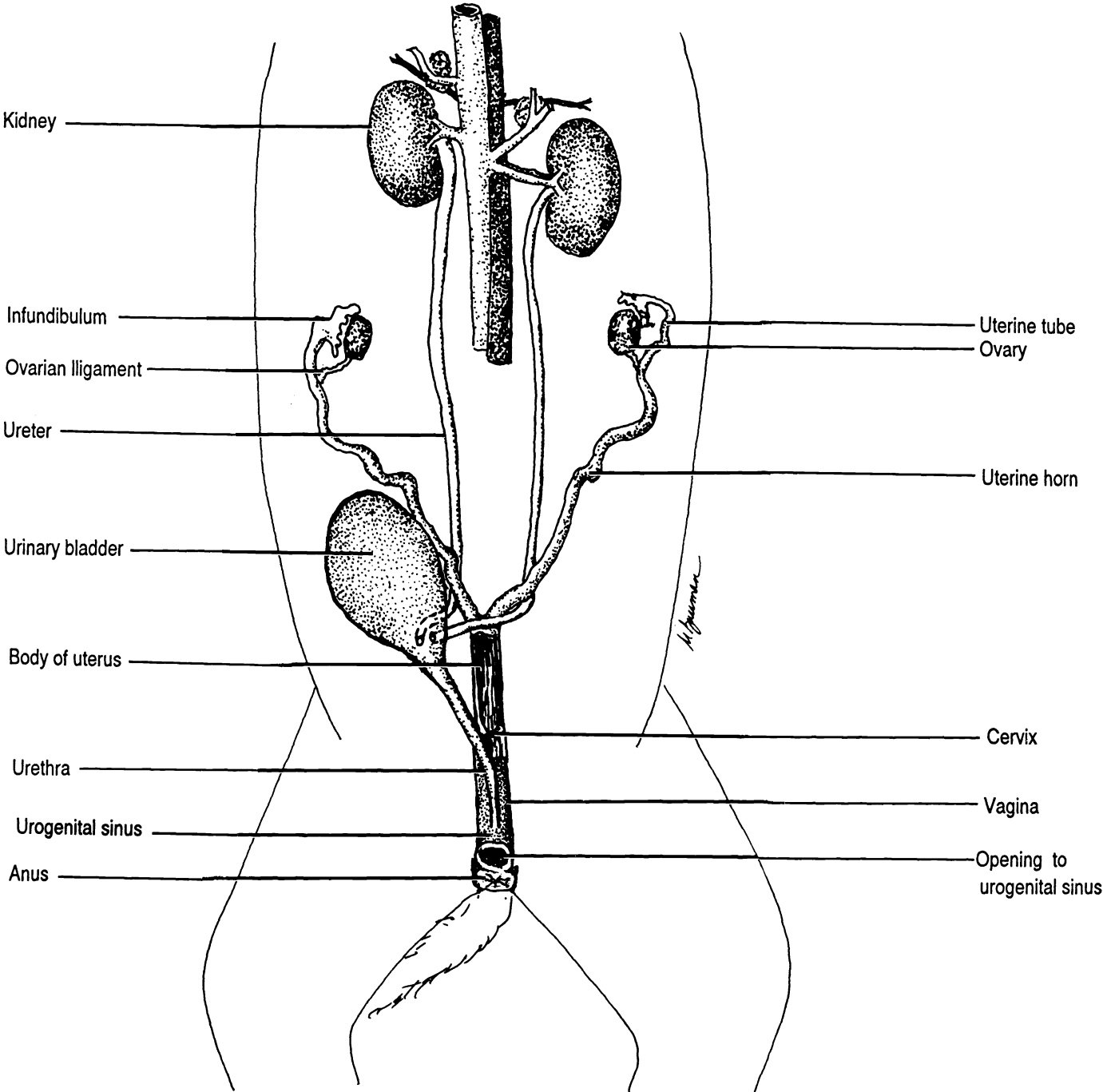


Figure 36.5 Female Reproductive System, frontal section

Body Cervix Fimbriae Fundus Infundibulum Ovarian ligament Ovary Vagina

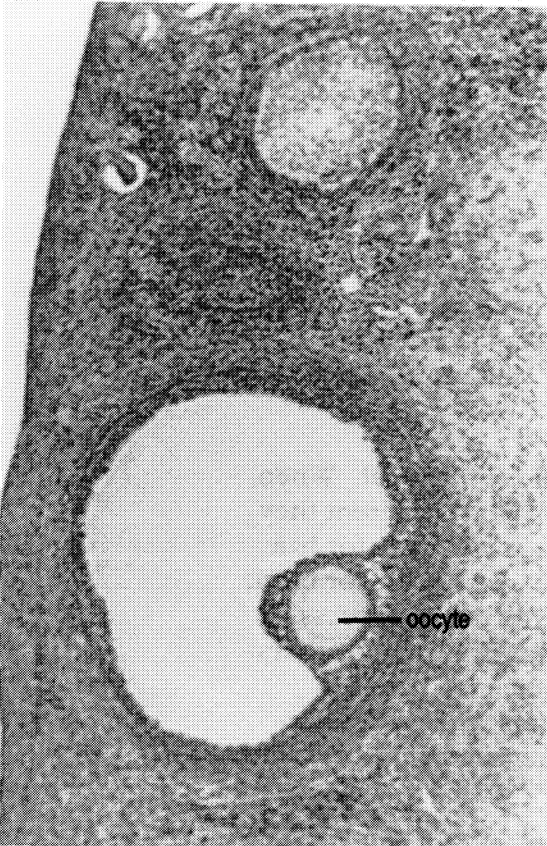
Figure 36.6 Urinary and Reproductive Systems of the Female Cat



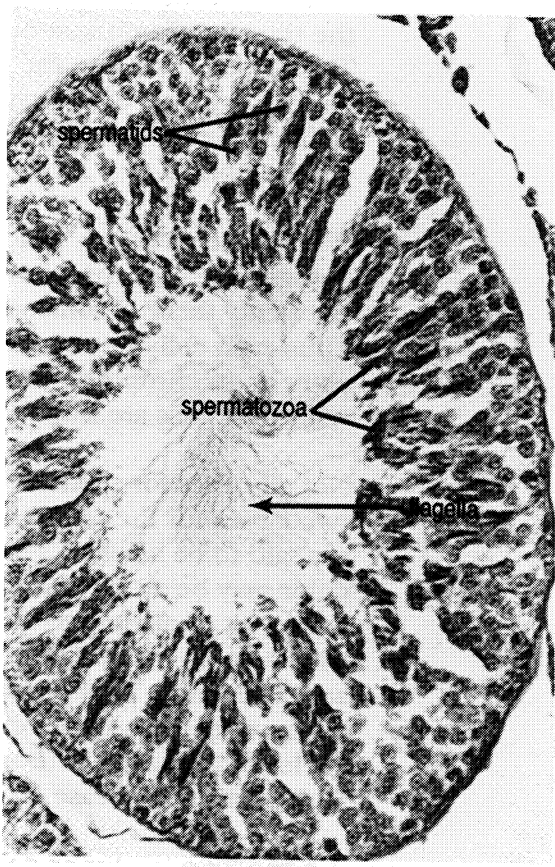
CHAPTER 36 REVIEW

1. _____ The primary sex glands of the male are the two (1).
2. _____ Sperm are stored in the (2).
3. _____ The distal end of the penis is known as the (3).
4. _____ The erectile tissues of the penis are (4), (5), and (6).
5. _____
6. _____
7. _____ The fold of skin covering the glans penis is the (7).
8. _____ The secondary sex glands in the male are (8), (9), and (10).
9. _____
10. _____
11. _____ The largest secondary sex gland in the male is the (11).
12. _____ Sperm travel from the epididymis in the (12).
13. _____ The duct within the prostate gland which empties into the urethra is the (13).
14. _____ The smallest of the secondary sex glands in the male are the (14).
15. _____ Sperm are produced in the (15).
16. _____ The primary female sex organs are the (16).
17. _____ These organs are held in place by the (17) ligaments.
18. _____ An ovum is carried from the ovary to the uterus through a (18) tube.
19. _____ The narrow neck of the uterus is the (19).
20. _____ The cervix opens to the (20).
21. _____ The finger-like projections at the end of the uterine tubes are (21).
22. _____ The vagina opens externally between the medial and lateral (22).

23. _____ True/false. The vagina and the urethra share a common opening in humans.
24. _____ The broad funnel at the end of the uterine tube is an (24).



Graafian follicle



Testis

CHAPTER 37
GENETICS

Genetics is the study of inheritance. Inheritance involves the transfer of information from parents to offspring. This information is in the form of **genes** which are coded segments of deoxyribonucleic acid (DNA). DNA is found in all nuclei and is organized into chromosomes.

With one exception, which will be mentioned later, human beings have two complete sets of genes. We inherit one set of twenty three chromosomes from each of our parents. Thus each cell of our bodies (except sex cells) contain 23 pairs or 46 chromosomes. Body cells are said to be **diploid**, while sex cells are **haploid**.

Not all genes for a particular trait are identical. When two genes for the same trait are slightly different they are said to be **alleles**. For instance, the gene for hair color may be an allele for blonde, or an allele for black hair. Not all alleles are equally effective at expressing themselves. Some alleles are **dominant** while others are **recessive**. Traditionally dominant alleles are abbreviated with upper case letters while recessive alleles of the same gene are abbreviated with the same letter, only lower case.

A **genotype** is a list or description of the exact genes which are present in an organism. The **phenotype** is a description only of the traits which are visible or measurable. For example, a genotype might be "one dominant allele for black hair and one recessive allele for blonde hair", but since black hair is dominant over blonde hair, only the black-hair allele would be visible. The phenotype is simply "black hair".

Two words are commonly used to describe genotypes more easily. **Heterozygous** means that the two alleles are different. In our example of hair color the genotype could be simply stated as "heterozygous". The genotype could also be written "Bb" where "B" stands for the dominant allele and "b" for the recessive allele.

Homozygous indicates that the two alleles are identical. The genotype could be "homozygous dominant" (two dominant alleles, e.g. BB) or "homozygous recessive" (two recessive alleles, e.g. bb).

Notice that there are only two alleles for any given trait, because one allele was inherited from each parent.

With this background in vocabulary you are ready to work some problems in genetics. We will work many problems with animals and not with humans, because genetic problems often involve the need for many offspring as well as matings between siblings, or between offspring and parents.

GENETICS PROBLEMS

Monohybrid Problems

(One trait being followed from one generation to the next.)

1. Polydactyly, having more than five digits, is a dominant allele. We can use any letter for our abbreviation, but we should use one which is easy to remember and which has different forms for upper and lower case. Let us use "F" to represent the dominant allele for polydactyly. Five fingers is a recessive allele so we will abbreviate it "f".

Two individuals who are heterozygous for polydactyly marry. What is the phenotype and genotype of each parent? What is the chance that they will have a five-fingered child? a six-fingered child?

- a. Father's phenotype _____ Mother's phenotype _____
- b. Father's genotype _____ Mother's genotype _____
- c. Father's sperm cells _____ or _____
- d. Mother's ova _____ or _____

(Remember that sperm cells or ova can contain only one allele because they are haploid.)

One of the easiest ways to work genetic problems is to use a Punnett square. The square consists of boxes representing the offspring. The mother's potential ova are listed above the boxes, the father's potential sperm are listed down the left side. The boxes are then filled in by combining the sperm and egg alleles inside each box.

The dominant allele (upper case letter) is always written first, regardless of who donates it.

Punnett square

Notice that there is a 75% chance (3 out of 4) that a child will have six fingers (FF, Ff, and Ff). There is a 25% chance that a child will be five-fingered (ff).

2. A man who is heterozygous for polydactyly marries a woman who has only five fingers on each hand. What is the probability of having these characteristics in their offspring?

Six fingers _____ Five fingers _____

3. In humans, curly hair is dominant over straight hair. If a straight-haired woman marries a heterozygous, curly-haired man, what is the chance that they will have a child who has straight hair?

Straight-haired child _____

Dihybrid Problems

(Two traits being followed from one generation to the next.)

You will still use the Punnett square, only each egg or sperm will have alleles for two different genes and the square will have sixteen boxes instead of four.

4. In horses, black color (B) dominates chestnut color (b). The trotting gait (T) dominates the pacing gait (t). A cross is made between a horse homozygous for black color and the pacing gait, and a horse which is homozygous for both chestnut color and trotting gait. List the probable genotypes and phenotypes of their offspring.

5. What possible offspring could result from crossing two of the offspring from problem number four?

6. Humans may have Rh⁺ blood or Rh⁻ blood. Rh⁺ is dominant. Normal insulin production is dominant over abnormal insulin production (diabetes mellitus).

If both parents are heterozygous for the Rh factor and for insulin production, what is the phenotype and genotype of the parents? What will be the phenotype(s) and genotype(s) of their children?

7. If the father is homozygous for Rh⁺ blood and has diabetes mellitus and the mother has Rh⁻ blood and is homozygous for insulin production, what phenotypes could they produce in their offspring?

8. In humans, there is a type of blindness due to a dominant allele; normal vision is the result of a recessive allele in this case. Migraine headaches are due to a dominant allele and normal (no headaches) is recessive.

A man who is blind and does not suffer from headaches marries a woman who has normal vision and suffers from migraines. Could they produce a child with normal vision who does not suffer from headaches? If yes, can the probability of such a child be determined?

Sex-linked Genes

There are genes located on the X chromosome which have no corresponding allele on the Y chromosome. (The Y chromosome is shorter than its homolog.) Females carry two X chromosomes; males carry one X and one Y. Thus

males have only one allele of some genes carried by the X chromosome.

9. In humans, the condition for normal blood clotting dominates the condition for non-clotting (hemophilia). Both alleles are linked to the X chromosome.

A male hemophiliac marries a woman who is a carrier (i.e. heterozygous). What are the chances, if they have a son, that he will be hemophiliac?

10. A male who has normal blood clotting marries a woman who is a carrier for this condition. What are the chances, that if they have a son, he will be normal for blood clotting?

11. In humans, the condition for normal vision dominates color blindness. Both alleles are linked to the X chromosome.

A color blind male marries a color blind female. If they have a daughter, what are the chances that she will have normal vision?

12. A normal visioned man marries a color blind woman. She gives birth to a color blind daughter. The husband claims that the child is not his. The wife claims the child is his. Can you support the argument of either parent? If yes, which one? Why?

Multiple Allele Problems

(Characteristics which have more than two possible alleles per gene.)

13. In humans, the alleles for A type blood and B type blood show codominance. A person with both alleles A and B has AB blood type. Both A and B dominate O.

A person with alleles for type A blood and type O blood marries someone with an allele for type B blood and an allele for type O blood. List the types of offspring they could have and the probability for each type.

14. A young woman with type O blood gave birth to a baby with type O blood. In a court case she claims that a certain young man is the father of her child. The man has type A blood. Can it be proven on this evidence alone that he is the father? Could he be the father?

Polygenic Inheritance Problems

(Any characteristic which is controlled by more than one pair of alleles.)

15. Normal pigmentation dominates no pigmentation (albinism). In order for an organism to exhibit color, it must have an allele for normal pigment production as well as alleles for a specific color. In cattle, red color dominates black.

An albino bull that is heterozygous for red is crossed with a red cow. The cow is heterozygous for normal pigment production and for red coloring. What types of offspring will they produce and what will be the probability of producing each?

16. In humans, black hair dominates blonde hair. An albino person will have white hair color even though he or she may also have the alleles for black or blonde hair.

An albino man who is homozygous for black hair marries a woman who is heterozygous for normal pigmentation and who has blonde hair. What colors of hair can their children have and what is the probability of each?

Determination of Genotype
(What you see and what you get.)

Not all types of heredity problems deal with the determination of the phenotypes of the offspring. There is a type of problem where the phenotypes of both parents and the offspring are known and their genotypes are determined.

For example, in humans, brown eyes are dominant over blue eyes. Two brown eyed people marry and produce one brown eyed child and two blue eyed children. What is the genotype of the parents and of each child?

Since the parents are both brown eyed, they must have at least one allele for brown eyes. Their genotypes are "B_". (The "_" means that the gene could be either the dominant allele or the recessive allele.) The genotype for the blue eyed children must be "bb". Since the parents each contribute one allele to each child, you know that each brown eyed parent must have a blue-eye allele. Therefore, the "_" must be a "b" and the genotype of each parent is "Bb". All you know about the brown eyed child is that the child has at least one allele for brown eyes. The genotype could be "BB" or "Bb", so we write it as "B__".

In the remaining problems, attempt to determine the genotypes of the individuals. Take it slowly and only write down an allele when you are certain that the individual has it. In all other cases put a "_".

17. Two people with normal skin pigmentation produce brown-eyed children, blue-eyed children with normal skin pigmentation, and albino children. What are the possible genotypes of the parents?

18. In rabbits, short hair is due to a dominant allele (L) and long hair to its recessive allele (l). Black hair is due to a dominant allele (B) and white hair to its recessive (b).

When two rabbits were crossed they produced 2,497 short haired black and 801 long haired black offspring. What are the probable genotypes of the parents?

19. A man and wife produce daughters who are all hemophilia carriers and sons who are all normal in their blood clotting ability. What are the probable genotypes of the parents? (Remember that the blood-clotting allele is linked to the X chromosome.)

Father:

Mother:

20. In humans, deafness is due to a homozygous condition of either or both recessive genes "d" and "e". Both dominant genes "D" and "E" are needed for normal hearing.

Two deaf people marry and produce eight offspring who all have normal hearing. What are the probable genotypes of the children and of the parents?

LM HUMAN A&P



00128

/

1B

ISBN 1-878045-06-7